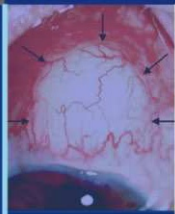


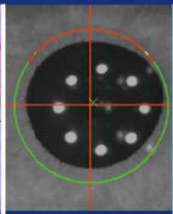
ESSENTIALS IN OPHTHALMOLOGY

G. K. KRIEGLSTEIN · R. N. WEINREB

Series Editors



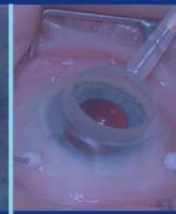Glaucoma



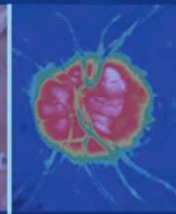
Cataract
and Refractive
Surgery



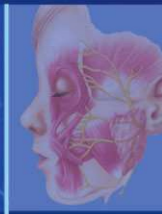Uveitis
and
Immunological
Disorders



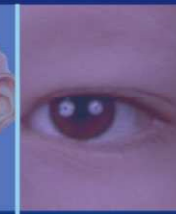Vitreo-retinal
Surgery



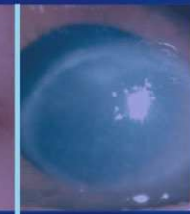Medical
Retina



Oculoplastics
and Orbit



Pediatric
Ophthalmology,
Neuro-
ophthalmology,
Genetics



Cornea
and External
Eye Disease

Cataract and Refractive Surgery

PROGRESS III

Edited by
T. KOHNEN
D. D. KOCH

 Springer

Essentials in Ophthalmology

G. K. Krieglstein R. N. Weinreb
Series Editors

Glaucoma

Cataract and Refractive Surgery

Uveitis and Immunological Disorders

Vitreo-retinal Surgery

Medical Retina

Oculoplastics and Orbit

Pediatric Ophthalmology, Neuro-Ophthalmology, Genetics

Cornea and External Eye Disease

Editors Thomas Kohnen
Douglas D. Koch

Cataract and Refractive Surgery

Progress III

With 145 Figures, Mostly in Colour
and 6 Tables

 Springer

Series Editors

Günter K. Krieglstein, MD

Professor and Chairman
Department of Ophthalmology
University of Cologne
Kerpener Straße 62
50924 Cologne
Germany

Robert N. Weinreb, MD

Professor and Director
Hamilton Glaucoma Center
Department of Ophthalmology
University of California at San Diego
9500 Gilman Drive
La Jolla, CA 92093-0946
USA

Volume Editors

Thomas Kohnen, MD

Professor of Ophthalmology
Department of Ophthalmology
Johann Wolfgang Goethe-University
Theodor-Stern-Kai 7
60590 Frankfurt
Germany
and
Baylor College of Medicine
Cullen Eye Institute
6565 Fannin, Suite NC205
Houston, TX 77030
USA

Douglas D. Koch, MD

Professor and the Allen, Mosbacher,
and Law Chair in Ophthalmology
Department of Ophthalmology
Baylor College of Medicine
Cullen Eye Institute
6565 Fannin, Suite NC205
Houston, TX 77030
USA

ISBN 978-3-540-76378-9

e-ISBN 978-3-540-76380-2

ISSN 1612-3212

Library of Congress Control Number: 2008935626

© 2009 Springer-Verlag Berlin Heidelberg

This work is subject to copyright. All rights are reserved, whether the whole or part of the material is concerned, specifically the rights of translation, reprinting, reuse of illustrations, recitation, broadcasting, reproduction on microfilms or in any other way, and storage in data banks. Duplication of this publication or parts thereof is permitted only under the provisions of the German Copyright Law of September 9, 1965, in its current version, and permission for use must always be obtained from Springer-Verlag. Violations are liable for prosecution under the German Copyright Law.

The use of general descriptive names, registered names, trademarks, etc. in this publication does not imply, even in the absence of a specific statement, that such names are exempt from the relevant protective laws and regulations and therefore free for general use.

Product liability: The publishers cannot guarantee the accuracy of any information about dosage and application contained in this book. In every individual case the user must check such information by consulting the relevant literature.

Cover Design: WMXDesign GmbH, Heidelberg, Germany

Printed on acid-free paper

9 8 7 6 5 4 3 2 1

springer.com

Foreword

The Essentials in Ophthalmology series represents an unique updating publication on the progress in all subspecialties of ophthalmology.

In a quarterly rhythm, eight issues are published covering clinically relevant achievements in the whole field of ophthalmology. This timely transfer of advancements for the best possible care of our eye patients has proven to be effective. The initial working hypothesis of providing new knowledge immediately following publication in the peer-reviewed journal and not waiting for the textbook appears to be highly workable.

We are now entering the third cycle of the Essentials in Ophthalmology series, having been encouraged by

readership acceptance of the first two series, each of eight volumes. This is a success that was made possible predominantly by the numerous opinion-leading authors and the outstanding section editors, as well as with the constructive support of the publisher. There are many good reasons to continue and still improve the dissemination of this didactic and clinically relevant information.

G.K. Krieglstein

R.N. Weinreb

Series Editors

September 2008

Preface

We are pleased to share with our readers this Third Edition of *Cataract and Refractive Surgery*, less than three years from publication of the Second Edition. The dramatic pace of change in cataract and refractive surgery necessitates rapid publication of new material, with frequent updating of topics and introduction of new topics as they become clinically relevant.

The emphasis in this edition is on refining what we do. One chapter discusses the latest technologies for imaging the anterior segment of the eye. Three chapters address advances in cataract surgical techniques and the management of complications. Two chapters describe new IOLs that provide a superior quality of

uncorrected and, in one instance, corrected vision. Topics in corneal refractive surgery include discussion of the management of higher order aberrations and corneal procedures for treating presbyopia.

We greatly appreciate our authors' generous contribution of wisdom and time in writing these chapters. We hope that this volume enhances ophthalmologists' ability to provide the best vision for their cataract and refractive surgical patients and that it stimulates new ideas for advancing the field.

Thomas Kohnen
Douglas D. Koch

Contents

Chapter 1

Anterior Segment Imaging

Martin Heur, William J. Dupps, Jr

1.1	Introduction.....	1
1.2	Placido-Disc Based Imaging.....	2
1.3	Slit-Scanning Imaging.....	2
1.4	Scheimpflug Imaging.....	2
1.5	Arc-Scanning Ultrasound.....	3
1.6	Optical Coherence Tomography Imaging.....	4
1.7	Comparison of Imaging Capabilities.....	4
1.7.1	Pachymetry.....	4
1.7.2	Refractive Surgery.....	7
1.7.3	Biometry.....	8
1.7.4	Lamellar Corneal Surgery.....	8
	References.....	9

Chapter 2

Microincisional Lens Surgery

Jorge L. Alió, Pawel Klonowski,
Bassam El Kady

2.1	Introduction: The Trends Towards Microincision Cataract Surgery.....	11
2.2	MICS Definition.....	12
2.3	Indication for MICS Surgery.....	12
2.4	Our Surgical Technique Step by Step.....	13
2.4.1	MICS Anesthesia.....	13
2.4.2	MICS Incision.....	13
2.4.3	MICS Capsulorhexis.....	13
2.4.4	MICS Hydrodissection, Hydrodelineation.....	14
2.4.5	MICS Prechopping.....	14
2.4.6	MICS Phacoemulsification and Removal Section.....	15
2.5	Flat Instruments Concept.....	17
2.6	Fluidics in MICS.....	17
2.7	Irrigation and Aspiration: Creating a Balanced Fluidics Environment....	19
2.8	Is MICS Worthwhile?.....	20
2.8.1	Clinical Outcome.....	20
2.8.2	Outcome of the Incision.....	20
2.8.3	Astigmatism Control with MICS.....	21

2.8.4	Corneal Aberration Control with MICS.....	21
2.9	End of the Surgery.....	23
2.10	Future of MICS.....	24
	References.....	24

Chapter 3

Capsular Tension Rings

Rupert Menapace

3.1	History of the Concept.....	27
3.2	Applications and Designs.....	28
3.2.1	Impact of a CTR on IOL Positioning and Refraction.....	28
3.2.2	The CTR as a Surgical Tool.....	29
3.2.2.1	Localized Zonular Dehiscence.....	29
3.2.2.2	Generalized Zonular Weakness.....	29
3.2.2.3	Posterior Capsulorhexis.....	30
3.2.2.4	Combined Cataract and Vitreous Surgery.....	30
3.2.3	Modified CTR for Special Purposes ..	31
3.2.3.1	CTRs for Iris Defects.....	31
3.2.3.2	CTRs for Sulcus Suture Fixation.....	32
3.2.3.3	Capsular Tension Segments.....	33
3.2.4	The CTR as a Measuring Gauge.....	34
3.2.4.1	Quantification of the Diameter of the Evacuated Capsular Bag.....	34
3.2.4.2	Quantification of Bag Diameter Changes During Capsular Shrinkage.....	34
3.2.5	CTRs and After-Cataract Formation.....	35
3.2.6	The Capsular Bending Ring.....	36
3.2.7	Full-Circle Capsular Bending Rings.....	38
3.2.7.1	'Tailed' Capsular Bending Ring.....	38
3.2.7.2	Foldable Closed Ring.....	38
3.3	Surgical Technique.....	40
3.3.1	Timing of Ring Insertion.....	40
3.3.2	Insertion Techniques and Instruments.....	40
3.3.3	Sizing of the Capsulorhexis.....	41
3.4	Complications, Prophylaxis and Management.....	41
3.4.1	Intraoperative Complications.....	41

3.4.2	Postoperative Complications.....	41	Chapter 6		
3.4.2.1	Capsular Contraction	41	Wavefront-Modified IOLs		
3.4.2.2	(Sub-) Luxation of CTR-IOL-Bag Complex	42	Li Wang, Elizabeth Yeu, Douglas D. Koch		
	References	42	6.1	Introduction.....	81
			6.2	Aspheric IOLs.....	81
			6.2.1	Corneal Spherical Aberrations.....	81
			6.2.2	Aspheric IOLs.....	82
			6.3	Custom Selection of Aspheric IOLs	84
			6.3.1	Custom Selection of Aspheric IOLs in Normal Eyes	84
			6.3.2	Custom Selection of Aspheric IOLs in Eyes Following Myopic-PRK.....	85
			6.3.3	Custom Selection of Aspheric IOLs in Eyes Following Hyperopic LASIK/PRK... ..	86
			6.4	Decentration/Tilt of Aspheric IOL.....	87
			6.5	Depth of Focus with Aspheric IOLs	89
			6.6	Clinical Outcome of Aspheric IOLs.....	90
			6.7	Conclusion	92
				References	92
			Chapter 7		
			How Should We Manipulate Higher-Order Aberrations After Refractive Surgery?		
			Jens Bühren, Thomas Kohnen, Scott M. MacRae		
			7.1	Refractive Surgical Procedures Induce Higher-Order Aberrations, and Higher-Order Aberration Correction Can Induce Spherical Refractive Error (Aberration Interaction)	95
			7.2	Role of Higher-Order Aberrations After Refractive Surgery on Visual Performance	96
			7.3	Methods to Optimize the Wavefront Error Post Refractive Surgery.....	96
			7.3.1	Wavefront-Guided Laser Profiles	97
			7.3.2	Aspheric ("Wavefront-Optimized") Laser Profiles	97
			7.3.3	Improved Treatment Registration: Dynamic Rotational Sensible (Active) Eyetrackers.....	97
			7.3.4	Improved Keratomes: Femtosecond Laser LASIK.....	97
			7.4	Current and Future State of the Art LASIK and Lenticular Surgery.....	97
				References	98
			Chapter 8		
			Current State of Accommodation Research		
			Martin Baumeister, Thomas Kohnen		
			8.1	Introduction.....	101
			8.1.1	Accommodation.....	101
Chapter 4					
Intraocular Lens Complications and Management					
Diamond Y. Tam, Iqbal Ike K. Ahmed					
4.1	Introduction.....	45			
4.2	IOL Complications	45			
4.2.1	Presentation.....	45			
4.2.2	Causes	48			
4.3	Management of the Malpositioned IOL	49			
4.3.1	General Principles	49			
4.3.2	IOL Repositioning: Surgical Principles.....	50			
4.3.2.1	Capsular Fixation	51			
4.3.2.2	Scleral Sutured Repositioning.....	54			
4.3.2.3	Iris Sutured Repositioning	58			
4.3.3	IOL Explantation and Exchange – Surgical Principles	60			
4.4	Conclusion	63			
	References	65			
Chapter 5					
Toric Intraocular Lenses for Correction of Astigmatism in Primary Cataract Surgery					
Thomas Kohnen, Victor Derhartunian, Daniel Kook, Oliver K. Klaproth					
5.1	Background	67			
5.1.1	Astigmatism.....	67			
5.1.2	Incidence of Astigmatism in the Cataractous Population.....	67			
5.1.3	Surgical Correction of Astigmatism.....	70			
5.2	Toric IOL Technology.....	70			
5.2.1	Concepts of TIOL for Primary Cataract Surgery.....	70			
5.2.2	Advantages and Disadvantages of TIOL	70			
5.3	Handling of TIOL.....	71			
5.3.1	Preoperative Measurements	71			
5.3.2	TIOL Calculation	72			
5.3.3	Implantation of TIOL.....	72			
5.3.4	Follow-Up.....	76			
5.4	Discussion.....	76			
5.4.1	Rotational Stability	76			
5.4.2	Residual Astigmatism.....	79			
5.4.3	Visual Acuity	79			
	References	79			

Contributors

Iqbal Ike K. Ahmed

Department of Ophthalmology and Visual Sciences
University of Toronto, Toronto
ON, Canada

Shazia S. Ahmed

Eye Center of Northshore
225 Boston St.
Lynn, MA 01904
USA

Jorge L. Alió

Vissum/Instituto Oftalmológico de Alicante
Avda de Denia s/n
Edificio Vissum, 03016 Alicante
Spain

Martin Baumeister

Department of Ophthalmology
Johann Wolfgang Goethe-University
Theodor-Stern-Kai 7
60590 Frankfurt am Main
Germany

Jens Bühren

Department of Ophthalmology
Johann Wolfgang Goethe-University
Theodor-Stern-Kai 7
60590 Frankfurt am Main
Germany

Victor Derhartunian

Department of Ophthalmology
Johann Wolfgang Goethe-University
Theodor-Stern-Kai 7
60590 Frankfurt am Main
Germany

William J. Dupps

Cole Eye Institute and
Department of Biomedical Engineering
Lerner Research Institute, Cleveland Clinic
9500 Euclid Ave/i-32
Cleveland, OH 44195
USA

Bassam El Kady

Ain Shams University
Cairo, Egypt
and
Clinical research fellow at Vissum-Instituto
Oftalmologico de Alicante
Department of Research and Development
Alicante, Spain

Martin Heur

Cole Eye Institute
Cleveland Clinic
9500 Euclid Ave/i-32
Cleveland, OH 44195, USA

Oliver K. Klaproth

Department of Ophthalmology
Johann Wolfgang Goethe-University
Theodor-Stern-Kai 7
60590 Frankfurt am Main
Germany

Pawel Klonowski

Vissum-Instituto Oftalmologico de Alicante
Department of Research and Development
Alicante
Spain

Douglas D. Koch

Department of Ophthalmology
Baylor College of Medicine
Cullen Eye Institute
6565 Fannin, Suite NC205
Houston, TX 77030
USA

Thomas Kohnen

Department of Ophthalmology
Johann Wolfgang Goethe-University
Theodor-Stern-Kai 7
60590 Frankfurt am Main
Germany
and
Cullen Eye Institute
Baylor College of Medicine
6565 Fannin, Suite NC 205
Houston, TX 77030
USA

Daniel Kook

Department of Ophthalmology
Johann Wolfgang Goethe-University
Theodor-Stern-Kai 7
60590 Frankfurt am Main
Germany

and
Department of Ophthalmology
Ludwig Maximilians-University
Mathildenstrape 8
80336 Munich, Germany

Scott M. MacRae

Strong Vision
University of Rochester Eye Institute
100 Meridien Centre
Suite 125
Rochester, NY 14618
USA

Rupert Menapace

Department of Ophthalmology
Medical University of Vienna
Vienna General Hospital
Wahringer Guertel 18-20
1090 Vienna, Austria

Diamond Y. Tam

Department of Ophthalmology and Visual Sciences
University of Toronto
Toronto, ON
Canada

Li Wang

Department of Ophthalmology
Baylor College of Medicine
Cullen Eye Institute
6565 Fannin, Suite NC205
Houston, TX 77030
USA

Mitchell P. Weikert

Baylor College of Medicine
Houston, TX
USA

Elizabeth Yeu

Department of Ophthalmology
Baylor College of Medicine
Cullen Eye Institute
6565 Fannin, Suite NC205
Houston, TX 77030
USA

Anterior Segment Imaging

1

Martin Heur, William J. Dupps, Jr

Core Messages

- Placido-disc based imaging provides a curvature map of the anterior cornea based on *reflections* of mires and assuming prolate corneal shape.
- Placido-disc based imaging interpolates central corneal data and does not provide posterior corneal surface data
- Slit scanning imaging relies on parallel slit beams and direct stereotriangulation to model anterior and posterior corneal surfaces
- Arc-scanning ultrasound uses parallel very high frequency ultrasound B-scans of the cornea to model anterior and posterior corneal surfaces
- Arc-scanning ultrasound provides imaging of the anterior chamber, iridocorneal angle structures, the anterior lens, and the ciliary sulcus
- Arc-scanning ultrasound requires emersion of the cornea for scanning
- Scheimpflug imaging uses Scheimpflug images of the anterior segment to model anterior and posterior corneal surfaces
- Scheimpflug imaging provides images of the anterior chamber, iridocorneal angle structures, and portions of the lens not obstructed by iris
- Anterior segment OCT relies on interferometry of backscattered light to generate cross-sectional images of the anterior segment
- Anterior segment OCT can provide pachymetry maps of the cornea along with images of the anterior chamber, iridocorneal angle, and anterior lens
- Measurements from the different systems should not be used interchangeably

1.1 Introduction

Anterior segment imaging has made tremendous strides since the introduction of slit lamp biomicroscopy. When the slit illumination device [1] of Swedish ophthalmologist Allvar Gullstrand was combined with Czapski's binocular microscope in 1916, a major advance was marked as more accurate three-dimensional visualization and localization of anterior segment pathology became possible. Subsequent advances in anterior segment imaging have occurred primarily in three categories: (1) introduction of new imaging methods [ultrasound, confocal microscopy, and optical coherence tomography (OCT)], (2) progression from qualitative to quantitative analysis aided by advances in digital imaging, and (3) advances in end-user data representation [2].

Slit lamp biomicroscopy is an excellent case study of this progress. The coupling of photography to the slit lamp biomicroscope allowed clinicians to create permanent impressions of an exam, and these images became

the preferred media for communicating clinical findings. Clinical atlases illustrating normal eyes and diseases of the anterior segment emerged. With the introduction of digital image acquisition, edge-detection algorithms allowed quantitative characterization of the anterior and posterior corneal surfaces, which provided the geometric information necessary to reconstruct surface elevations, curvatures, and thicknesses across a two-dimensional optical section. More recently, video acquisitions of rotating Scheimpflug sections [e.g., the Pentacam (Oculus) and the Galilei (Ziemer Ophthalmic Systems)] or horizontally scanning vertical slit beams [Orbscan (Bausch & Lomb Surgical)] have combined multiple two-dimensional sections to reconstruct the three-dimensional anatomy of the cornea. Similar advances are also occurring in the measurement of the anterior chamber, iridocorneal angle structures, and the lens. This chapter presents an overview of major imaging approaches in refractive surgery, including computerized videokeratography, arc-scanning ultrasound, Scheimpflug imaging, and anterior segment

OCT. The focus is on clinical utility as well as caveats for practitioners who rely on the information these technologies provide.

1.2 Placido-Disc Based Imaging

Corneal topography dates its roots to over 100 years ago when Antonio Placido showed that the corneal steepness could be estimated by examining the reflection of concentric discs on the cornea; the areas of the cornea where the mires – the reflections of the discs – are closer together are steeper than areas where the mires are farther apart. This laid the foundations for the modern keratoscope. Videokeratography combines the keratoscope with image capture and digital analysis of the mires, allowing for more refined quantitative analysis of the anterior corneal curvature [3].

Videokeratography measures the anterior corneal *curvature*, which is but one representation of corneal shape, and derives the curvature map from the data assuming a prolate corneal geometry. This assumption can lead to errors when attempting to map the surface of irregular corneas or those of patients who have undergone refractive surgery [4]. Another disadvantage is the absence of posterior corneal surface data. The posterior surface is not imaged and is instead presumed to have radius of curvature that is 0.82 times that of the anterior curvature. Furthermore, the center of the cornea cannot be imaged because of the diminutive nature of central mires; central corneal data is thus interpolated from neighboring data points. This is usually not a source of clinically significant error in unoperated corneas where assumptions of prolate sphericity are reasonable, but in patients who have had refractive surgery, central interpolation within the framework of a spherical assumption can lead to underestimation of central flatness and lead to hyperopic refractive surprises after cataract surgery.

1.3 Slit-Scanning Imaging

The Orbscan was a breakthrough technology that utilized three-dimensional scanning slit triangulation to generate elevation maps for both the anterior and posterior corneal surfaces. Orbscan II combined the scanning slit system with placido-disc keratography to integrate corneal elevation data with traditional corneal curvature measurements. Pachymetric maps of the cornea are derived from the elevation data. The combination of elevation and pachymetry maps has been useful in keratoconus screening during refractive surgery evaluations and provides information about focal thickness and posterior surface abnormalities that is not available with reflection-based corneal topography.

Like other light-based imaging modalities and in contrast to ultrasonic pachymetry, the Orbscan does not require contact with the eye.

Of the many factors affecting the interpretation of a measurement, none is more influential than the format of the output presented to the clinician. From a single reconstruction of anterior and posterior surface elevation data from scanning slit devices or other full-thickness corneal imaging technologies, users can obtain maps of corneal curvature expressed with any number of algorithms (usually axial, mean, or tangential curvature). Fundamental differences in the mathematics and implications of axial and tangential/instantaneous radius of curvature algorithms have been elegantly discussed by Roberts [5–7]. Figure 1.1 illustrates a practical example of how a single elevation dataset from a central island induced after broad-beam phototherapeutic keratectomy can produce three very different postoperative curvature maps, ranging from a focal central island with flattening of the ablation zone to a more diffuse island that shows overall steepening of the ablation zone [8]. This is a dramatic illustration of the power of the data representation algorithm to affect our interpretation of an imaging study, and clearly argues against the interchangeability of curvature algorithms in irregular corneas.

1.4 Scheimpflug Imaging

The Pentacam captures slit images of the anterior segment using the Scheimpflug principle, a photographic technique that involves a non-parallel orientation of lens and image planes to correct for perspective distortion (Fig. 1.2). The Pentacam images the anterior segment of the eye in three dimensions using 25–50 slit images captured by a rotating camera, and a second camera captures eye movements to facilitate centration [9]. Anterior and posterior elevation and curvature maps and pachymetry maps of the cornea are generated from surface measurements (Fig. 1.3). Unlike videokeratography, data over the central cornea is obtained by direct measurements, though the resolution of these measurements for calculating curvature is debated. The Pentacam can provide biometry data such as anterior chamber depth while allowing visualization of the irido-corneal angle structures and the lens within the pupillary aperture [9].

A major area of interest is estimation of true corneal refractive power for calculating optimal intraocular lens (IOL) power in eyes that have had refractive surgery. The BESt formula uses Pentacam-derived anterior and posterior corneal radii and central pachymetry data to calculate corneal power based on the Gaussian optics formula without relying on pre-refractive surgery historical information [10]. A recent integrated software enhancement

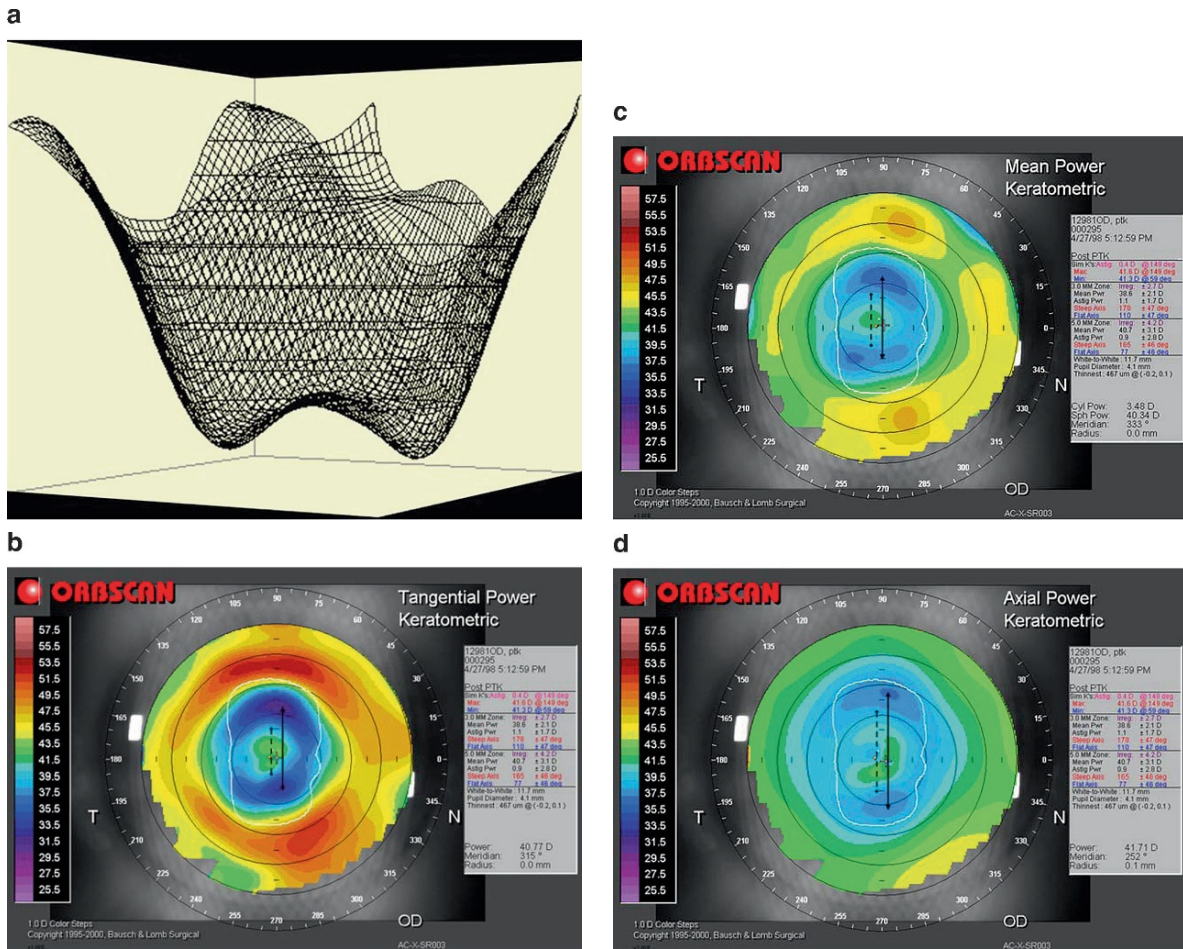


Fig. 1.1 Example of central island formation associated with 5 mm, 100-micron broad-beam phototherapeutic keratectomy (PTK) and the impact of curvature algorithm alone on the perceived effects of surgery. The vertical axis in (a) indicates the effective ablation profile in millimeters as determined by Orbscan pachymetry map subtraction in one human donor globe. Post-PTK Orbscan (version 2.10B) curvature representation by tangential (b), mean (c), and axial (d) algorithms for the same cornea represented in (a). The diameter of the 38.5 diopter (d) isopter of the central island (*dashed arrow*) is progressively increased in (c) and (d). Note also circumferential spread of the island's diameter into

the paracentral cornea in (d) (*solid arrows* mark distance between curvature minima, i.e., 'valleys') and loss of the dramatic central and para-central flattening previously seen in (b). The mean algorithm (c) appears to respect the island diameter established in (b) but underestimates overall ablation zone flattening. The mean intraoperative curvature change in 10 donor globes was -9.69 D (flattening) in the central 5.0 mm zone if the tangential algorithm was used, -2.81 D if the mean algorithm was used, and $+3.88$ D (steepening) if the axial algorithm was used. The effect of a central corneal topographic feature on curvature depends strongly on the mathematical algorithm used to calculate curvature

includes quantification of spatial pachymetric progression profiles for risk assessment of keratoconus [11].

1.5 Arc-Scanning Ultrasound

Artemis (ArcScan) is an arc-scanning very high frequency ultrasound that combines parallel B-scans with digital signal processing to provide three-dimensional pachymetric mapping of the cornea [12]. The chief advantage of this method over visible light slit-beam imaging is that it

provides sufficient resolution for direct measurements of corneal sublayers, including epithelial, flap, and residual stromal bed thickness in LASIK patients or lamellar graft thicknesses in anterior or posterior lamellar keratoplasty (Fig. 1.4) [13]. Residual stromal thickness maps are of great utility in deciding whether adequate stromal bed remains for LASIK enhancement procedures, and compensatory epithelial thinning atop an area of stromal steepening may be an early sign of keratoconus that is not apparent on standard topography [14]. A major advantage of the Artemis shared by other ultrasound biomicroscopy methods is its

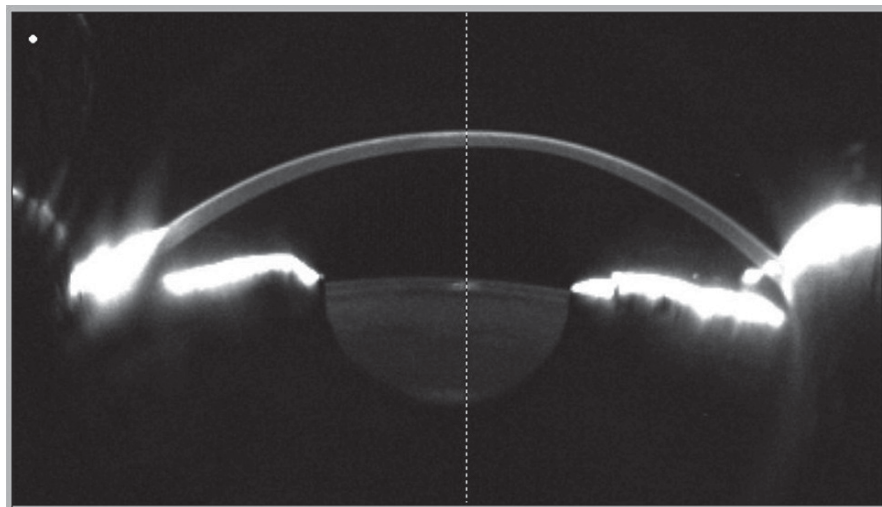


Fig. 1.2 Scheimpflug image of anterior segment. A Scheimpflug image of the anterior segment obtained with the Pentacam shows the anterior segment in cross section. Structures shown include the cornea, anterior chamber, iris, and lens

capability in the setting of media opacities such as corneal infiltration and hyphema. A disadvantage is that it requires immersion of the eye for adequate ultrasound coupling.

not the epithelial/Bowman's membrane interface. Spectral domain systems provide much faster scan rates, and higher resolution anterior segment OCT devices are in development [17].

1.6 Optical Coherence Tomography Imaging

Optical coherence tomography (OCT), initially developed to test the integrity of fiber-optic lines, relies on interferometry to measure time delay and intensity of backscattered light relative to a reference beam of known path length and time delay [15]. It is analogous to ultrasound in that it relies on reflected energy but relies on light instead of sound. The anterior segment OCT evolved from OCT developed for posterior segment imaging and typically uses a longer wavelength infrared laser (1,310 vs. 820nm) [16]. Because the longer wavelength is mostly absorbed by the anterior segment structures, higher power can be used without damaging the retina (15mW for the anterior segment OCT versus 0.7mW) [16]. Higher power combined with higher sampling rate result in higher image resolution compared to the posterior segment OCT. A commercially available time-domain anterior segment OCT, the Visante (Zeiss), takes meridional, telecentric linear measurements of the anterior segment to generate pachymetry maps of the cornea (Fig. 1.5). It can also provide anterior chamber depth data and imaging of the iridocorneal angle structures and the anterior crystalline lens. The anterior segment OCT is used in refractive surgery primarily as a pachymetric mapping tool that is capable of resolving the flap interface but

1.7 Comparison of Imaging Capabilities

1.7.1 Pachymetry

All the above modalities, except videokeratography, can be used to measure corneal pachymetry. Published reports show that all modalities demonstrate excellent repeatability in normal corneas. Orbscan pachymetry measurements are slightly higher than ultrasound pachymetry, and most clinicians use a software correction factor of 0.92 with Orbscan measurements [18]. A comparative study of central corneal thickness between Orbscan, Pentacam, and ultrasound pachymetry in 21 healthy eyes showed good correlation between Pentacam and ultrasound pachymetry [19]. The authors also showed that the mean measured values were lowest for Orbscan, using the correction factor, and highest for ultrasound pachymetry [530 μ m (Orbscan) vs. 542 μ m (Pentacam) vs. 552 μ m (ultrasound pachymetry)] [19]. A study of 42 myopic eyes showed a high correlation between anterior segment OCT and ultrasound pachymetry measurements, and anterior segment OCT values for central corneal thickness were slightly lower compared to ultrasound pachymetry [547 μ m (anterior segment OCT) vs. 553 μ m (ultrasound pachymetry),

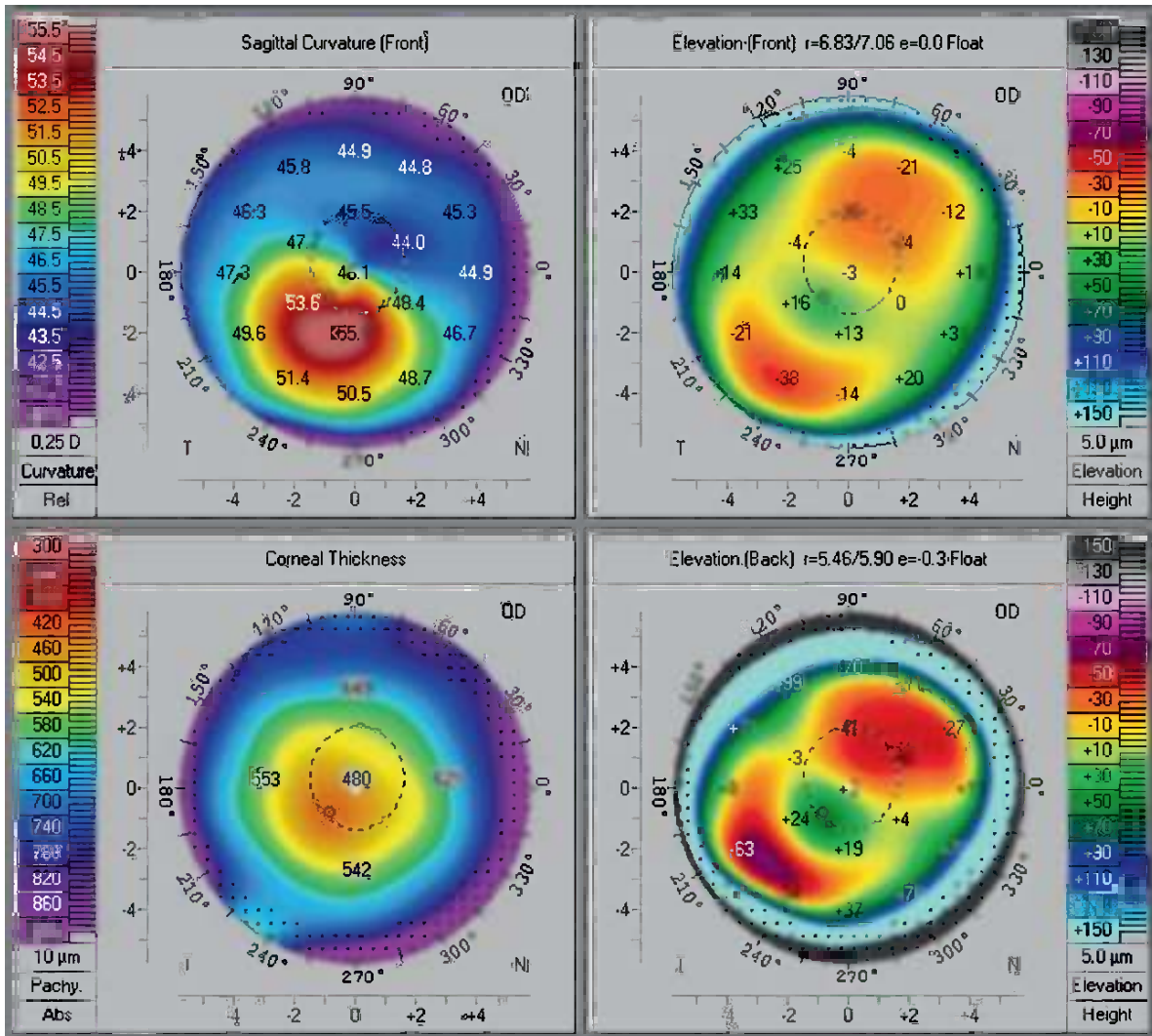


Fig. 1.3 Pentacam refractive map. A refractive map of the cornea generated by the Pentacam shows a curvature map, pachymetry map, and posterior and anterior elevation maps of the central 10 mm. This refractive surgery screening exam reveals several stigmata of keratoconus




Fig. 1.4 Artemis very high frequency arc-scanning ultrasound image of Descemet stripping and automated endothelial keratoplasty (DSAEK) graft adherent to host bed

$p < 0.001$] [20]. A study of 54 healthy eyes showed a high correlation between Pentacam, Orbscan II, and ultrasound pachymetry measurements, and there were no

statistically significant differences between the systems [$538 \pm 31 \mu\text{m}$ (Pentacam), $541 \pm 41 \mu\text{m}$ (Orbscan II), and $545 \pm 31 \mu\text{m}$ (ultrasound pachymetry), $p = 0.57$] [21].

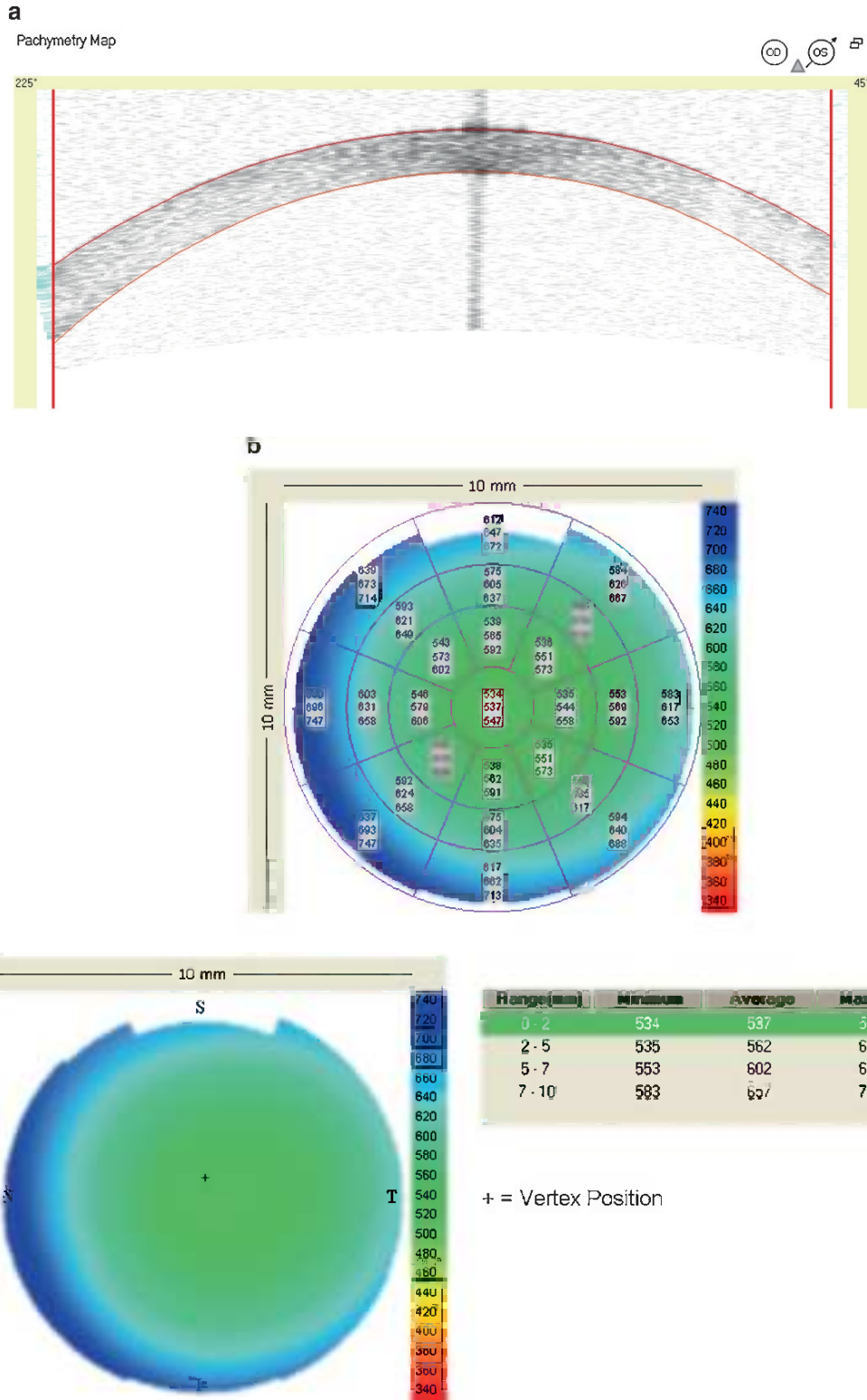


Fig. 1.5 (a) A standard resolution time-domain anterior segment OCT image of the cornea used to calculate corneal pachymetry. (b) Pachymetry map generated by the Visante anterior segment OCT shows corneal thicknesses in the central 10 mm of the cornea. The table shows the minimum, maximum and average thicknesses of concentric regions of the cornea. (c) A high-resolution Visante image of a post-DSAEK cornea

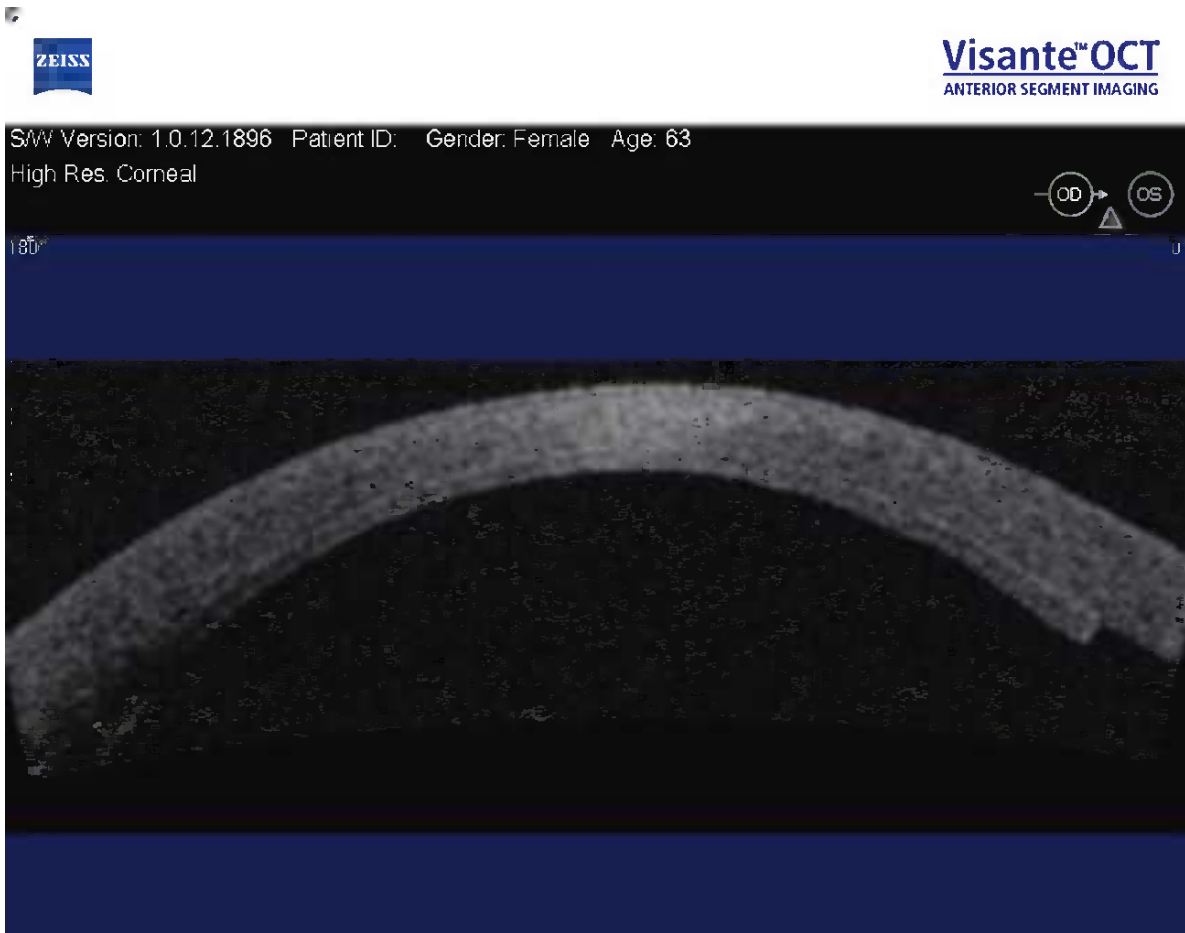

Fig. 1.5 (continued)

Although multiple studies have shown correlations between the various systems, it does not necessarily follow that measurements from the different systems can be used interchangeably. This issue may be addressed using analyses proposed by Bland and Altman, who described a method for assessing the interchangeability of different measurements [22–24]. It is important to note that results can be considered statistically interchangeable but produce limits of agreement that are clinically unacceptable for some purposes.

It is also critical to note that thickness measurements depend on the quality of anterior and posterior surface edge detection algorithms. These are subject to error when abnormally high reflections are encountered for example in the presence corneal scar or corneal edema. The clinician should inspect surface tracings on scanning slit, Scheimpflug and OCT image to confirm the fidelity of posterior surface tracings.

1.7.2 Refractive Surgery

Videokeratography and Orbscan scanning slit topography have been used extensively by refractive surgeons for several years. Both have been useful for identifying patients with features of keratoconus during preoperative screening and for evaluating postoperative ectasia. Many algorithms that rely on topographic data such as KISA% index and Klyce–Maeda–Smolek tests are available to identify patients with keratoconus [25, 26]. Reports are beginning to emerge correlating topographic features considered to be high risk for corneal ectasia to slit-scanning and Scheimpflug imaging findings. In one study, higher anterior maximum elevation, horizontal location of the thinnest point on the pachymetry map, and large differences between the highest and lowest points on the posterior elevation map with Orbscan II were the strongest predictors of a suspicious Placido

topography, while thin pachymetry and large differences between the highest and lowest points on the posterior elevation map were the strongest predictors with the Pentacam [27]. Due to a lack of a standard for comparing posterior corneal topography data, it is difficult to compare data from different devices. A study of 36 eyes from confirmed keratoconus patients showed that there were statistically significant differences between Pentacam and Orbscan IIz in their posterior corneal topographic measurements [28]. Such differences are difficult to interpret in part because of the lack of a gold standard for posterior corneal topographic measurements [29].

Many of the current modalities can image the cornea with sufficient resolution to detect the LASIK flap interface. The anterior segment OCT has been shown to be a useful tool in studying flap anatomy in eyes that have undergone LASIK [30]. Anterior segment OCT and arc-scanning ultrasound can be useful in the evaluation of a patient presenting for enhancement of previous refractive surgery because they can, in addition to being able to image the flap and the stromal bed, measure the thickness of each to determine the suitability of the enhancement procedure [31, 32]. Arc-scanning ultrasound has been used to successfully reposition a free LASIK cap and to facilitate complex refractive interventions such as trans-epithelial phototherapeutic keratectomy in a patient with multiple prior keratorefractive procedures [33, 34]. With large numbers of people electing to undergo refractive surgery, it is inevitable that tissue banks will experience an increase in donors that have had refractive procedures. Initial work using the anterior segment OCT shows promising results in being able to detect corneas that have had refractive procedures while the eye is still in the container with the preservative medium [35].

1.7.3 Biometry

Biometry is becoming increasingly important with increasing patient expectations for excellent refractive outcomes after cataract surgery. Accurate biometry is critical not only in the preoperative sizing and postoperative management of phakic intraocular lenses, but also in calculating posterior chamber intraocular lenses power and in evaluating anterior segment pathology such as iris masses. Systems such as Artemis, Pentacam, and anterior segment OCT can provide biometry measurements such as anterior chamber depth and angle-to-angle distance. A study of 20 healthy eyes showed no statistical difference in anterior chamber depth and horizontal angle-to-angle measurements between the anterior segment OCT and the Artemis 2 [36]. Mean anterior chamber depth

measurements were 3.07 ± 0.40 mm (Artemis 2) versus 3.16 ± 0.41 mm (anterior segment OCT, $p = 0.45$), and horizontal angle-to-angle measurements were 12.23 ± 0.59 mm (Artemis 2) versus 12.14 ± 0.54 mm (anterior segment OCT, $p = 0.69$) [36]. A study of 82 eyes showed that mean anterior chamber depth measurements between Pentacam and IOL Master were very similar [3.25 mm (Pentacam) vs. 3.20 mm (IOL Master)] [37]. A study of 60 healthy eyes showed deeper anterior chamber depth measurements with the anterior segment OCT relative to immersion A-scan [3.12 ± 0.33 mm (anterior segment OCT) vs. 2.98 ± 0.33 mm (immersion A-scan), $p = 0.02$] [38]. The studies that showed no differences were limited by their power in that their sample size was insufficient to detect statistical significance at the level of observed difference. Biometry values between different systems cannot be used interchangeably until more studies with larger sample sizes are available.

Phakic intraocular lenses (PIOL) are becoming more popular for correction of ametropia. PIOL have inherent challenges, such as respecting the anterior segment anatomy, that are not associated with posterior chamber intraocular lenses [39]. White-to-white measurement to estimate anterior chamber size for PIOL sizing has been shown to underestimate of the angle-to-angle distance in postmortem eyes [40], and such measurements are critical in the preoperative evaluation. Measurements such as endothelium to PIOL distance and PIOL to crystalline lens distance are also important in the postoperative evaluation. The anterior segment OCT has been shown to be a useful approach for obtaining anterior segment biometry [39, 41], though the question of interchangeability with other modalities, including ultrasound biomicroscopy, slit-scanning imaging, and arc-scanning ultrasound remains unanswered [41–46].

1.7.4 Lamellar Corneal Surgery

Lamellar corneal procedures are gaining popularity due to improved benefit-to-risk ratios over penetrating keratoplasty in select cases. The anterior segment OCT has been shown to be useful in postoperative management of patients who have undergone lamellar corneal surgery. It can provide information on donor apposition or detachment, retained Descemet membrane, and anterior chamber crowding [47]. A study using anterior segment OCT has shown that the visual outcome in deep anterior lamellar keratoplasty is dependent on the thickness of the residual host bed. Patients who had residual thickness less than $20\mu\text{m}$ had much better visual outcomes than those whose thickness was

greater than 80 μm [48]. Very high frequency arc-scanning ultrasound has provided evidence, through clinical profilometry of endothelial keratoplasty lenticles, that graft central thickness and graft thickness profile independently contribute to refractive shifts in DSAEK (Descemet-stripping automated endothelial keratoplasty) [13].

Summary for the Clinician

- Anterior segment imaging technology is changing the way ophthalmologists evaluate and manage their patients. Complete three-dimensional characterization of the geometry of the anterior segment is becoming more accessible to clinicians and is increasingly important as corneal and lenticular refractive technologies increase in sophistication. Advances in imaging speed, resolution, and quantitative data representation will ensure that clinicians have the tools necessary to meet the challenges of this rapidly growing field.

References

1. Gullstrand A (1911) Demonstration der Nernstspaltlampe. *Ber Deutsch Ophthalmol Ges* 37:374–6
2. Dupps WJ Jr (2006) Anterior segment imaging: new milestones, new challenges. *J Cataract Refract Surg* 32(11):1779–83
3. Binder PS (1995) Videokeratography. *CLAO J* 21(2):133–44
4. Koch DD, Foulks GN, Moran CT, Wakil JS (1989) The corneal EyeSys system: accuracy analysis and reproducibility of first-generation prototype. *Refract Corneal Surg* 5(6):424–9
5. Roberts C (1995) Analysis of the inherent error of the TMS-1 topographic modeling system in mapping a radially aspheric surface. *Cornea* 14(3):258–65
6. Roberts C (1994) The accuracy of 'power' maps to display curvature data in corneal topography systems. *Invest Ophthalmol Vis Sci* 35(9):3525–32
7. Roberts C (1994) Characterization of the inherent error in a spherically-biased corneal topography system in mapping a radially aspheric surface. *J Refract Corneal Surg* 10(2):103–11, discussion 12–6
8. Dupps WJ, Jr., Roberts C (2001) Central islands affect interpretation of anterior curvature change in an in vitro model of excimer laser keratectomy. *Invest Ophthalmol Vis Sci* 42:S894
9. Buehl W, Stojanac D, Sacu S, et al (2006) Comparison of three methods of measuring corneal thickness and anterior chamber depth. *Am J Ophthalmol* 141(1):7–12
10. Borasio E, Stevens J, Smith GT (2006) Estimation of true corneal power after keratorefractive surgery in eyes requiring cataract surgery: BESSt formula. *J Cataract Refract Surg* 32(12):2004–14
11. Ambrosio R Jr, Alonso RS, Luz A, Coca Velarde LG (2006) Corneal-thickness spatial profile and corneal-volume distribution: tomographic indices to detect keratoconus. *J Cataract Refract Surg* 32(11):1851–9
12. Reinstein DZ, Silverman RH, Trokel SL, Coleman DJ (1994) Corneal pachymetric topography. *Ophthalmology* 101(3):432–8
13. Dupps WJ, Jr., Qian Y, Meisler DM (2008) Multivariate model of refractive shift in Descemet-stripping automated endothelial keratoplasty. *J Cataract Refract Surg* 34(4):578–84
14. Reinstein DZ, Archer TJ, Gobbe M, et al (2008) Epithelial thickness in the normal cornea: three-dimensional display with Artemis very high-frequency digital ultrasound. *J Refract Surg* 24(6):571–81
15. Huang D, Swanson EA, Lin CP, et al (1991) Optical coherence tomography. *Science* 254(5035):1178–81
16. Huang D, Li Y, Radhakrishnan S (2004) Optical coherence tomography of the anterior segment of the eye. *Ophthalmol Clin North Am* 17(1):1–6
17. Kaluzny BJ, Kaluzny JJ, Szkulmowska A, et al (2006) Spectral optical coherence tomography: a new imaging technique in contact lens practice. *Ophthalmic Physiol Opt* 26(2):127–32
18. Swartz T, Marten L, Wang M (2007) Measuring the cornea: the latest developments in corneal topography. *Curr Opin Ophthalmol* 18(4):325–33
19. O'Donnell C, Maldonado-Codina C (2005) Agreement and repeatability of central thickness measurement in normal corneas using ultrasound pachymetry and the OCULUS Pentacam. *Cornea* 24(8):920–4
20. Li Y, Shekhar R, Huang D (2006) Corneal pachymetry mapping with high-speed optical coherence tomography. *Ophthalmology* 113(5):792–9, e2
21. Amano S, Honda N, Amano Y, et al (2006) Comparison of central corneal thickness measurements by rotating Scheimpflug camera, ultrasonic pachymetry, and scanning-slit corneal topography. *Ophthalmology* 113(6):937–41
22. Bland JM, Altman DG (1986) Statistical methods for assessing agreement between two methods of clinical measurement. *Lancet* 1(8476):307–10
23. Ho T, Cheng AC, Rao SK, et al (2007) Central corneal thickness measurements using Orbscan II, Visante, ultrasound, and Pentacam pachymetry after laser in situ keratomileusis for myopia. *J Cataract Refract Surg* 33(7):1177–82
24. Li EY, Mohamed S, Leung CK, et al (2007) Agreement among 3 methods to measure corneal thickness: ultrasound pachymetry, Orbscan II, and Visante anterior segment optical coherence tomography. *Ophthalmology* 114(10):1842–7
25. Maeda N, Klyce SD, Smolek MK, Thompson HW (1994) Automated keratoconus screening with corneal topography analysis. *Invest Ophthalmol Vis Sci* 35(6):2749–57

26. Rabinowitz YS, Rasheed K (1999) KISA% index: a quantitative videokeratography algorithm embodying minimal topographic criteria for diagnosing keratoconus. *J Cataract Refract Surg* 25(10):1327–35
27. Nilforoushan MR, Speaker M, Marmor M, et al (2008) Comparative evaluation of refractive surgery candidates with Placido topography, Orbscan II, Pentacam, and wavefront analysis. *J Cataract Refract Surg* 34(4):623–31
28. Cairns G, McGhee CN (2005) Orbscan computerized topography: attributes, applications, and limitations. *J Cataract Refract Surg* 31(1):205–20
29. Quisling S, Sjoberg S, Zimmerman B, et al (2006) Comparison of Pentacam and Orbscan IIz on posterior curvature topography measurements in keratoconus eyes. *Ophthalmology* 113(9):1629–32
30. Li Y, Netto MV, Shekhar R, et al (2007) A longitudinal study of LASIK flap and stromal thickness with high-speed optical coherence tomography. *Ophthalmology* 114(6):1124–32
31. Izquierdo L Jr, Henriquez MA, Zakrzewski PA (2008) Detection of an abnormally thick LASIK flap with anterior segment OCT imaging prior to planned LASIK retreatment surgery. *J Refract Surg* 24(2):197–9
32. Reinstein DZ, Couch DG, Archer T (2006) Direct residual stromal thickness measurement for assessing suitability for LASIK enhancement by Artemis 3D very high-frequency digital ultrasound arc scanning. *J Cataract Refract Surg* 32(11):1884–8
33. Reinstein DZ, Archer T (2006) Combined Artemis very high-frequency digital ultrasound-assisted transepithelial phototherapeutic keratectomy and wavefront-guided treatment following multiple corneal refractive procedures. *J Cataract Refract Surg* 32(11):1870–6
34. Reinstein DZ, Rothman RC, Couch DG, Archer TJ (2006) Artemis very high-frequency digital ultrasound-guided repositioning of a free cap after laser in situ keratomileusis. *J Cataract Refract Surg* 32(11):1877–83
35. Lin RC, Li Y, Tang M, et al (2007) Screening for previous refractive surgery in eye bank corneas by using optical coherence tomography. *Cornea* 26(5):594–9
36. Pinero DP, Plaza AB, Alio JL (2008) Anterior segment biometry with 2 imaging technologies: very-high-frequency ultrasound scanning versus optical coherence tomography. *J Cataract Refract Surg* 34(1):95–102
37. Reuland MS, Reuland AJ, Nishi Y, Auffarth GU (2007) Corneal radii and anterior chamber depth measurements using the IOLmaster versus the Pentacam. *J Refract Surg* 23(4):368–73
38. Nemeth G, Vajdas A, Tsorbatzoglou A, et al (2007) Assessment and reproducibility of anterior chamber depth measurement with anterior segment optical coherence tomography compared with immersion ultrasonography. *J Cataract Refract Surg* 33(3):443–7
39. Baikoff G (2006) Anterior segment OCT and phakic intraocular lenses: a perspective. *J Cataract Refract Surg* 32(11):1827–35
40. Werner L, Izak AM, Pandey SK, et al (2004) Correlation between different measurements within the eye relative to phakic intraocular lens implantation. *J Cataract Refract Surg* 30(9):1982–8
41. Li H, Leung CK, Cheung CY, et al (2007) Repeatability and reproducibility of anterior chamber angle measurement with anterior segment optical coherence tomography. *Br J Ophthalmol* 91(11):1490–2
42. de Souza RF, Allemann N, Forseto A, et al (2003) Ultrasound biomicroscopy and Scheimpflug photography of angle-supported phakic intraocular lens for high myopia. *J Cataract Refract Surg* 29(6):1159–66
43. Frisch IB, Rabsilber TM, Becker KA, et al (2007) Comparison of anterior chamber depth measurements using Orbscan II and IOLMaster. *Eur J Ophthalmol* 17(3):327–31
44. Garcia-Feijoo J, Hernandez-Matamoros JL, Mendez-Hernandez C, et al (2003) Ultrasound biomicroscopy of silicone posterior chamber phakic intraocular lens for myopia. *J Cataract Refract Surg* 29(10):1932–9
45. Lavanya R, Teo L, Friedman DS, et al (2007) Comparison of anterior chamber depth measurements using the IOLMaster, scanning peripheral anterior chamber depth analyser, and anterior segment optical coherence tomography. *Br J Ophthalmol* 91(8):1023–6
46. Yu AY, Lin ZD, Chen XQ, et al (2008) Position of myopic iris-claw phakic intraocular lens by Scheimpflug photography and ultrasound biomicroscopy. *Eye* 22(2):233–9
47. Lim LS, Aung HT, Aung T, Tan DT (2008) Corneal imaging with anterior segment optical coherence tomography for lamellar keratoplasty procedures. *Am J Ophthalmol* 145(1):81–90
48. Ardjomand N, Hau S, McAlister JC, et al (2007) Quality of vision and graft thickness in deep anterior lamellar and penetrating corneal allografts. *Am J Ophthalmol* 143(2):228–35

Microincisional Lens Surgery

2

Jorge L. Alió, Pawel Klonowski, Bassam El Kady

Core Messages

- The minimization of the incision is a consequence of a natural evolution of the cataract surgery technique.
- Microincision cataract surgery (MICS) is the surgery performed through incisions of 1.5 mm or less.
- With MICS, you can operate all grades of cataract LOCS III, even hard cataracts, subluxated lenses, post traumatic lenses, zonular laxity, and congenital cataracts.
- One of the most important achievements of MICS is the reduction of the ultrasonic (US) power delivered into the eye.
- Among the major advantages of MICS is the reduction of surgical trauma resulting in a reduction of surgically-induced astigmatism (SIA).
- However, a major problem remains in the possibility of lens compression.
- The future belongs to the miniaturization of the tools and the wound size.
- MICS is ready to extract cataracts through sub-1-mm incisions.

2.1 Introduction: The Trends Towards Microincision Cataract Surgery

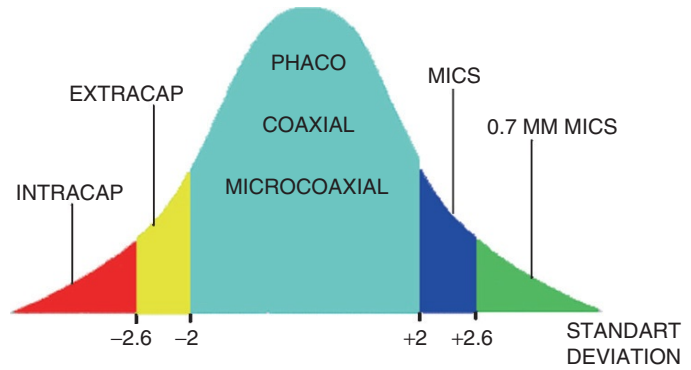
Biaxial microincision clear corneal phacoemulsification was a new method which made the corneal incision smaller; it was described by Shearing in 1985 [1]. This procedure uses separate irrigations with an irrigating chopper and sleeveless phacoemulsification tip, and also requires pulsed phacoemulsification energy.

The minimization of the incision is a consequence of a natural evolution of the cataract surgery technique in the search of excellence. When we place cataract surgery within the context of Gaussian distribution, it is clear that the normal practice today is standard coaxial phacoemulsification (Fig. 2.1). Extra-capsular 6-mm surgery is a procedure still in practice, but rarely performed, hence between -2 and -2.6 standard deviations. The Gaussian curve is like a wave. It moves from ancient to new surgical techniques. Nowadays, the standard coaxial technique

is still the most popular type of cataract surgery in the world. The coaxial wound size is still 2.75 mm, in spite of the availability of the newest foldable intraocular lenses which can be injected through smaller incisions. Microincision cataract surgery (MICS) can make the incision smaller than 1.5 mm and it should be considered beyond 2 and up to 2.6 standard deviations of our Gaussian distribution. MICS will be the standard practice in future, and what we could call sub-1-mm MICS or micro-MICS will be the next standard [2]. MICS is the next stage in the evolution of cataract surgery.

Summary for the Clinician

- The minimization of the incision is a consequence of a natural evolution of cataract surgery technique

Fig. 2.1 Natural evolution of cataract surgery [2]

2.2 MICS Definition

In 2001, MICS was patented as a new operating method by Jorge Alio. The definition of MICS is surgery performed through incisions of 1.5 mm or less. Understanding this global concept implies that it is not only about achieving a smaller incision size but also about making a global transformation of the surgical procedure towards minimal aggressiveness. In other words, a transition from conventional small incision surgery to the more developed concept of MICS [3].

Confirmed advantages of MICS:

- Surgery
 - I/A separation
 - No leakage (tight incision and well-profiled tools make wounds impermeable) [4–6]
 - Fluidics work as an instrument (high vacuum is the third power which can crumble the lens mass) [2, 3, 7]
 - Flexible surgery, assisted by fluidics (proper fluidics flow assures anterior chamber stability, while profundity and separated tools allow the possibility of faster and more precise surgery) [3, 8, 9]
 - Intraoperative control of intraocular pressure (permanent and sufficient infusion keep the eye globe in stable condition) [3, 10]
 - Smaller incision
 - New MICS irrigating hydromanipulators and the new use of fluidics leads to a reduction in the dimension of the incision [2, 3, 7–9]
 - Decreased effective phaco time (EPT)
 - Pre-chopping, new irrigating hydromanipulators, and fluidics as a tool, effectively decrease the time of phacoemulsification [4, 11–14]
- Patient
 - Minimal surgical-induced astigmatism
 - Smaller incision means smaller astigmatism [15–17]
 - Minimal aberration induction
 - Minor intraoperative injury does not lead to permanent injury of the cornea [4–6, 15, 17, 18]

- Faster postoperative recovery
 - Safe and stable anterior chamber operating system with minimal corneal injury reduces recovery time [4–6, 12, 13, 19]
- Excellent visual acuity
 - Fast and safe operation technique, and minimal harmful influence on corneal optic property [6, 8, 13, 15, 20, 21]

Ophthalmic surgeons who perform cataract surgery in the standard phacoemulsification mode will not have a problem changing their operation technique to MICS because the principle idea of the manipulation inside the eye remains unaltered. The main aim of MICS is to understand the principles.

Summary for the Clinician

- MICS is the surgery performed through incisions of 1.5 mm or less
- MICS advantages
 - I/A separation with fluidics work as an instrument
 - Smaller incision
 - Decreased effective phaco time (EPT)
 - Minimal surgical-induced astigmatism
 - Minimal aberration induction
 - Faster postoperative recovery
 - Excellent visual acuity

2.3 Indication for MICS Surgery

There is no limitation to indicate MICS cataract surgery. You can operate all grades of cataract LOCS III, even hard cataracts. The sub-luxated lenses, posttraumatic lenses, zonular laxity, and congenital cataracts can also be operated with MICS, with small doses of ultrasound. Generally MICS does not induce astigmatism. MICS is especially suitable for 'refractive cataract operation'. MICS can be used for refractive cataract

surgery by injecting multifocal lenses and toric lenses [21, 22].

Summary for the Clinician

- All grades of cataract LOCS III can be operated with MICS

2.4 Our Surgical Technique Step by Step

2.4.1 MICS Anesthesia

After the incision, intraocular anesthesia and mydriatics are applied to the eye. We use 1% lidocaine injecting it into the anterior chamber. Pupil dilatation is achieved by intraocular tropicamide (10%) and fenilefrine (10%) combination.

2.4.2 MICS Incision

The incision optimization results from maintaining a stable anterior chamber depth, adapting the incision size to the tools used, implantation of the lens, and counter-stretching in the route of manipulation. The minimization of the incision is required to carry out MICS correctly. Incisions smaller than 1.5 mm do not normally induce postoperative astigmatism [8]. Nowadays, we use 19 G (1/1.1 mm) and 21 G (0.7 mm) tools to do MICS.

The first stage of the operation is making two corneal incisions with a distance of 90–110° angle steps. To assure the reduction of existing astigmatism, a dominant incision must be made in a positive meridian of astigmatism. This leads to 30% reduction in the refractive cylinder [20]. Relaxing incisions can also be made [23, 24]. Incisions should allow correct tool manipulation and be watertight, and the wound should be correctly closed in

the postoperative period. The shape of the wound is very important, it should be trapezoidal-shaped with a smaller measurement 1.2 mm wide inside the wound near the Descemet membrane and a wider measurement 1.4 mm outside near the epithelium.

This shape is particularly important because of the necessity of the tool manipulation. By forming the wound this way it enables quite a considerable transfer of tools without any distortion, deformation, and maceration. It also protects against induced postoperative astigmatism. This is essential as the structure of the wound must be protected against leakage, and at the same time it provides an opportunity to work without tissue injury. The mechanical injury to tissues can lengthen the healing process and contribute to leakage, hypotony, and increased risk of endophthalmitis. It is also necessary to remember that too small incisions will not allow us to correct manipulations and a too big incision will lead to uncontrolled leakage from the wound. (Fig. 2.2) The value of such incisions reduces the possibility of exchanging liquids between the anterior chamber and the conjunctival sack [25–27].

To make the incision, we use trapezoidal knives, which allow different widths of incision from 1.2 mm at the peak to 1.4 mm at the base. To achieve this target, two kinds of knives can be used:

Alio's MICS knife (Katena, Denville, NJ, USA). Trapezoid shape 1.25 mm/1.4 mm/2.0 mm angled, double bevel (Fig. 2.3).

MICS diamond knife (Katena). Trapezoid shape, pale 1.25 mm/1.4 mm/2.0 mm width, laser-etched line indicating 1.25 mm width (Fig. 2.4).

2.4.3 MICS Capsulorhexis

Correctly performed capsulorhexis is vitally important for the MICS procedure. For this we used Alio's MICS capsulorhexis forceps (Katena). These are exquisitely delicate forceps with a 23-G diameter (Fig. 2.5).

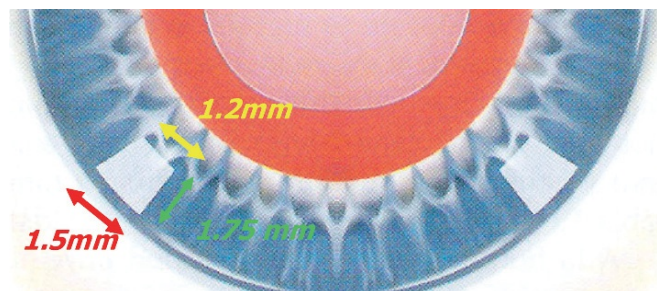


Fig. 2.2 19G Micro-incision cataract surgery (MICS) incision [3]

Fig. 2.3 Alio's MICS metal knife (Katena, Denville, NJ, USA)



Fig. 2.4 Alio's MICS diamond knife (Katena)



Fig. 2.5 Alio's MICS capsulorhexis forceps (Katena)



They can be easily located in the corneal wound. The correct profile of the hilt assures ergonomic use and normal movements inside the eye. At the end of the forceps is a pointed hook. This enables a controlled puncturing of the anterior capsule of the lens. Pressure is applied on the capsule and then with a little movement a cut is made. The wide-gauge shoulder forceps enable free manipulation of the torn capsule.

The next step is to pull the flap by tearing the capsule clockwise or anticlockwise. The size of the surgical wound and the diameter of the forceps prevent the possibility of the OVD leakage and flattening of the anterior chamber. The lens and the capsule are stabilized. The probability of bad tearing decreases. MICS capsulorhexis forceps allows capsulorhexis without the necessity of the help of the second tool.

2.4.4 MICS Hydrodissection, Hydrodelineation

The next stage of the cataract operation is the dissection of the lens from the cortex. This is important for prechopping as it enables the process of prechopping to be carried out in a safe way and does not cause complications.

Hydrodissection can diminish the power of ultrasound and surgery time [28].

In hydrodelineation, liquid is applied under the ring of the anterior capsule into the space of the lens. It enables the nucleus to be elevated and separated from the cortical masses. The maneuvers should be carried out as quickly as possible and with a very little amount of liquid. If nucleus rotation is not possible, hydrodissection maneuvers should be repeated [29].

2.4.5 MICS Prechopping

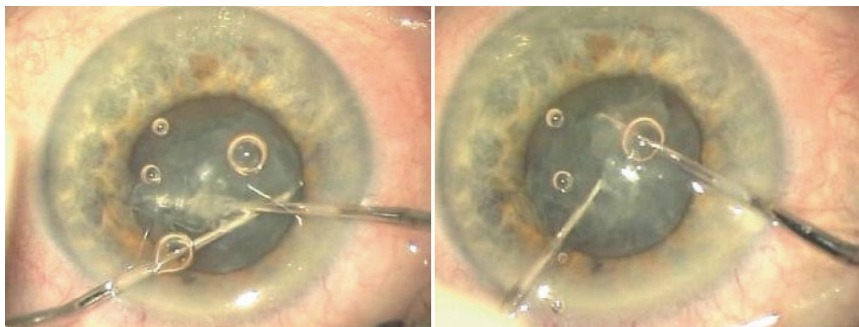
After the hydrodissection of the lens a mechanical division is made. This activity is aimed to make four lens quadrants. Prechopping reduces the amount of the ultrasonic, laser or mechanical energy delivered into the anterior chamber for fragmentation. This is a very important activity in the process of the energy reduction delivered to the eye. This is made with the help of two prechoppers (Alio-Rosen MICS prechoppers; Katena) (Fig. 2.6).

Two prechoppers should be inserted into the capsule under the anterior capsular rim, so that they are opposite each other. The hook of the chopper should be parallel

Fig. 2.6 Alio-Rosen phaco prechopper for MICS (Katena)



Fig. 2.7 MICS prechopping with Alio-Rosen phaco prechoppers



to the anterior capsule. Next, the chopper should be gently rotated along the axis of the tool. The chopper should now be situated in the lens under the anterior capsule on the perimeter (Fig. 2.7).

This activity should be made symmetrically by both hands. The choppers are crossed by situating each one symmetrically opposite to the other. Next, a cutting movement of the lens is made, gently crossing the prechoppers. The cut will be made from the perimeter to the center of nucleus. The internal edge of prechoppers is sharp which facilitates the incisions of the lens. This ambidextrous activity is important so that zonular stress does not occur. When the cut is made, two dividing hemispheres are formed. The nucleus is then rotated about 90° and the prechopping process is repeated as described. After carrying out prechopping, we have four lens quadrants in the capsular bag.

2.4.6 MICS Phacoemulsification and Removal Section

Having shared quadrants we can start phacoemulsification from the first quadrant. We use Alio's MICS hydro-manipulator irrigating fingernail (Katena). Its end is fingernail-shaped. This tool helps to remove rather soft cataracts. There is an irrigation hole on the bottom lower side of the tool. The hole diameter is 1 mm. It also has very thin walls to increase the internal diameter of the instrument. This irrigation canula assures infusion of about 72 cc min⁻¹ (Fig. 2.8).

An outstanding stability of the anterior chamber is assured through the infusion and directs the liquid to

the lens masses at the back of the capsule, independently from high vacuum settings of the phacoemulsification machine (Fig. 2.9).

The strength of the stream permits the capsule to be held at a safe distance from the phacoemulsification tip and at the same time enables convenient manipulations of tools and lens masses. Additionally, this stream can clean the posterior capsule from the remaining cortical cells. A very fertile directed stream to the posterior capsule is provided with the preservation of corneal endothelial cells from mechanical and thermal damage.

The tool which allows the removal of harder cataracts is Alio's MICS irrigating stinger (Katena) (Fig. 2.10).

This tool has a 19-G diameter and is equipped with a tip at the end which is angled downwards. This tool is useful to chop off segments or for dividing masses of the nucleus in the phacoemulsification tip.

In the case of soft cataracts, having established the pressure at 500–550 mmHg, we can only use Alio's MICS hydro-manipulator irrigating fingernail. This makes it possible to divide and aspirate fragments of the cataract without using ultrasound or using ultrasound in the minimum way. In this case, a torsional phacoemulsification system can be helpful. In the case of hard cataracts, when total occlusion of the tip occurs preventing aspiration, Alio's MICS irrigating stinger would be more useful. This handpiece has a narrow edge at the end which divides the masses and allows easy aspiration of the phacoemulsification tip. The fragmented elements of the hard cataracts are now easily aspirated using the high underpressure and occasionally using ultrasound energy.

Fig. 2.8 Alio's original fingernail MICS irrigating hydromanipulator (Katena)



Fig. 2.9 Posterior irrigation helps to open the capsular bag which does not induce turbulences, elevates nucleus fragments towards the phaco tip, and helps in cortex cleaning [3]

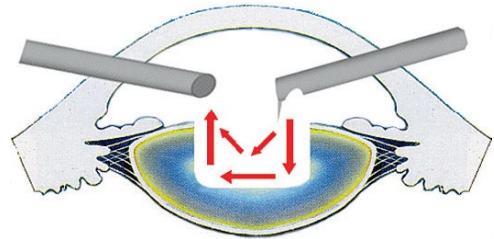


Fig. 2.10 Alio's MICS irrigating stinger (Katena)



Fig. 2.11 Alio's MICS aspiration handpiece (Katena)



For removing cortical remains, Alio's MICS aspiration handpiece (Katena) is a useful instrument. It has a port diameter of 0.3 mm which assures the stability of the hydrodynamic of liquid within the anterior chamber (Fig. 2.11).

Another auxiliary instrument, Alio's MICS scissors, exists for complicated cataracts which may require cutting within the anterior chamber. They can cut delicate membranes, adhesions, make iridotomy, and also cut the fibrosis of the capsules. This tool has a 23-G curved shaft with horizontal microblades (Fig. 2.12). Their shape allows the comfort of free manipulation in the angles of the anterior chamber.

Summary for the Clinician

- Incision should be trapezoidal-shaped with a smaller measurement 1.2 mm wide inside the wound near the Descemet membrane and a wider measurement 1.4 mm outside near the epithelium.
- Prechopping reduces the amount of the ultrasonic, laser, or mechanical energy delivered into the anterior chamber for lens fragmentation.
- Alio's MICS hydromanipulators assure an infusion of about 72 cc min^{-1} which allows the fluidics to act as a tool and cool the phaco tip.

Fig. 2.12 Alio's MICS scissors (Katena)



2.5 Flat Instruments Concept

Wound integrity is one of the most important factors that may influence the outcome of surgery. The assurance of the proper amount of the fluidics in MICS requires large dimensions of the tools. That is why the corneal tissue can be stressed during the operation. Mechanical tissue stress can evoke leakage, astigmatism, and anterior chamber instability [4–6, 25]. The requirement for tool improvement has become very important. The new Alio's MICS flat tools have been made by Katena. The irrigation and aspiration tools have rectangular cross-sections. The change of the shape did not influence the fluidics parameters. The fluidics flow of these tools is correct for MICS. Leakage around the tool is absent. Tool manipulation is easy and does not cause corneal tissue stress. Vertical manipulating does not stretch the wound and the horizontal movements do not press the angle of the wound due to the trapezoidal shape. This concept of irrigation–aspiration flat tools is a new way of treating the wound. The tools are adapted to the wound, but the wound does not have to be stressed by the tools. The tissue of the wound is untouched.

The self-sealing capability of the incision is mainly dependent on the construction of the wound: the angle, the width to depth ratio, and the multiple-plane construction of incision. The disturbance of these conditions can have an effect on the postoperative healing. The flat instruments do not affect the edges so the natural process of healing is not disturbed.

Summary for the Clinician

- MICS flat tools do not stretch the wound

2.6 Fluidics in MICS

In order to use the additional tool, the flow of liquids must be fulfilled with the following conditions:

1. Stable incision with no leakage
2. Stable anterior chamber
3. High vacuum

When the diameter of the infusion canulas is decreased a serious problem occurs. The anterior chamber does not start to fill up with the adequate amount of liquid. An infusion canula diameter of 21 G is not able to maintain a stable anterior chamber at aspiration and under pressure of 500–600 mmHg. Each attempt would end with the collapse of the anterior chamber.

Getting the high inflow of liquids into the anterior chamber is possible thanks to a new generation of tools. These tools have a relatively large infusion diameter and the right profile, allowing the right flow of liquid and a low level of internal resistance. These conditions do not allow the anterior chamber to become shallow or allow rippling of the posterior capsule. Also, the correct amount of liquid ensures chilling of the phacoemulsification tip and can function with highly efficient aspiration pumps.

According to the laws of physics the interior diameter of the tool has a major influence on fluidic resistance, because resistance is proportional to the diameter. Therefore, one is not allowed to apply standard infusion tools because of the insufficient hydrodynamics of these units. Tools assuring the flow is higher than 50 cc min^{-1} are needed for doing MICS. Current aspiration pumps have a utility which considerably exceeds the flow function of standard tools. The activity of standard infusion canulas is estimated at only 30 cc min^{-1} .

Therefore, the need for creating new tools arose in order to meet MICS needs. Katena took on the design and manufacture. A tool set came into existence with a very

small diameter in answer to MICS requirements but at the same time with a high flow of about 72 cc min⁻¹.

Using the highly efficient pump we must allow the correct inflow of liquid into the anterior chamber. In the case of the Accurus[®] and Infiniti[®] types of equipment we have the additional mechanism of pressurized inflow of fluidics – ‘gas forced infusion’. This can allow the controlling of the increase in the pressure of the irrigation bottle. This mechanism pumps filtered gas into the irrigation bottle and allows an additional increase in infusion. Highly efficient irrigation canulas and the mechanism of gas forced infusion helps provide the comfort of working in stable anatomical conditions.

We can achieve anterior chamber stability in two ways: (1) the high inflow of fluidics with proper instrument fluidics flow and forced infusion of fluidics, and (2) reduced outflow. The diminished diameter of tools and the Cruise Control stable chamber system allow proper outflow without reducing the vacuum.

MICS can be done with different kinds of aspiration systems. However, a Venturi Pump system is most popular and recommended. It has great flexibility and fast reaction. It allows a high value of underpressure and flow as the additional important tool in breaking and removing masses of the lens. The flow can be adjusted through the amount of vacuum and degree of occlusion of the tip. At present, venturi is the most efficient system. MICS settings with different phacoemulsification platforms are shown in Tables 2.1, 2.2 and 2.3.

Avoiding corneal burn:

At present, biaxial microincision clear cornea phacoemulsification makes it possible to do the treatment practically with no temperature elevation. However, development of high temperatures and incidence of corneal burns are possible (Fig. 2.13). For example, they may appear when the phacoemulsification tip is occluded for a long time with lens fragments associated with the use of highly OVD material [30]. They do not occur with the normal flow of liquids as long as the infusion liquid is circulated adequately. Flow control seems to be one of basic conditions of the entire procedure.

Table 2.1. Accurus 600 Alcon settings for 19G MICS

Quad	Phacoemulsification power	20%
	Vacuum	300 mmHg
	Irrigation	90
	Mode burst	30 ms

Table 2.2. Infinity Alcon settings for 19G MICS

Chop	Phacoemulsification power	0
	Dynamic rise	0
	Vacuum	150
	Irrigation	110
	Torsional amplitude	Limit 40 On: 20 Off: 40
	Aspiration rate	15
Quad	Phacoemulsification power	0
	Dynamic rise	2
	Vacuum	500
	Irrigation	110
	Torsional amplitude	Limit 80 On: 20 Off: 40
	Aspiration rate	30
Epi	Phacoemulsification power	0
	Vacuum	28
	Irrigation	110
	Torsional amplitude	Limit 30 On: 20 Off: 40
	Aspiration rate	28

Note For 21 G MICS forced air infusion with air pump is necessary

Table 2.3. Millennium Bausch & Lomb settings for 19G MICS

Sculpture	Bottle height	100 cm
	Maximum bottle infusion	40 mmHg
	Fixed vacuum	200 mmHg
	Fixed U/S	10%
	Duration	20 ms
	Duty cycle	60%
Quadrant	Bottle height	100 cm
	Maximum bottle infusion	40 mmHg
	Fixed vacuum	470 mmHg
	Fixed U/S	10%
	Duration	20 ms
	Duty cycle	60%
I/A	Bottle height	80 cm
	Maximum bottle infusion	40 mmHg
	Maximum vacuum	550 mmHg

Note For 21 G MICS forced air infusion with air pump is necessary

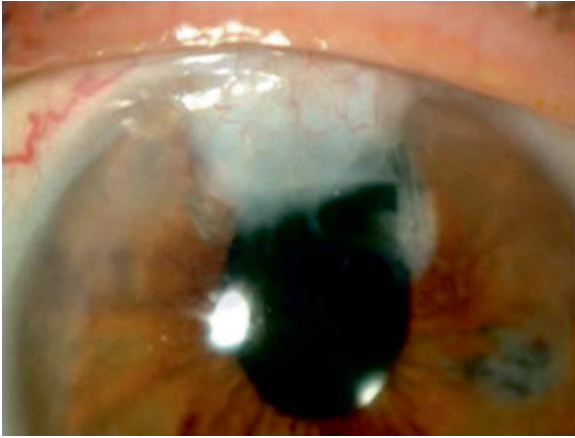


Fig. 2.13 Corneal burn after surgery. Personal case. This is the only corneal burn so far in our transmission period to MICS and was related to the use of high viscosity viscoelastics

Summary for the Clinician

- Fluidics conditions
 - Stable incision with no leakage
 - Stable anterior chamber
 - High vacuum
- MICS tools with a small diameter have a high liquid flow of about 72 cc min^{-1}
- 'Gas forced infusion' allows an additional increase in infusion
- Flow control is one of the basic conditions of the entire procedure

2.7 Irrigation and Aspiration: Creating a Balanced Fluidics Environment

The aspiration canula has a smaller internal diameter than the irrigation canula. This will cause disproportion in the resistance of the flow between infusion and aspiration and additionally will guarantee the anterior chamber stability. The aspirating canula has a hole of about 0.3 mm diameter. However, increasing the depth of the anterior chamber causes movement of the lens diaphragm which can make the lens fragments enter the space behind the iris. Fragments can get between the iris and the anterior capsule in the space surrounding the sulcus and cannot be seen. However, occasionally the fragments can be observed in the anterior chamber several hours after the operation. Rinsing out and cleaning this space is extremely important.

The stability of the anterior chamber in the case of MICS is indisputably higher than in coaxial phacoemulsification. MICS does not cause frequent and considerable changes in the anatomical proportion of the eyeball, and traction does not occur during the operation. From capsulorhexis to filling up with OVD before lens injection it is possible to maintain the anterior chamber stable.

Stable Chamber System

Cruise Control[™] of the STAAR Surgical Company is an additional system streamlining the irrigating–aspirating system [31]. It is a device specially designed for cataracts in the bimanual microincisional phacoemulsification mode at high vacuum settings. Cruise Control has a disposable flow restrictor with a 0.3-mm internal diameter. It is fixed between the phacoemulsification handpiece and the aspiration tubing. It prevents surges during occlusion breaks at higher vacuum level. It has a mesh filter which safeguards against blocking. Lens fragments remain on the filter. The restrictor limits the flow. At the underpressure of 500 mmHg, the anterior chamber does not become shallow (Fig. 2.14).

A similar device is offered by Bausch & Lomb (Rochester, NY, USA). The Stable Chamber differs in size restrictor, but the principle of action remains similar. This device can be attached to the standard phaco machine tubes (Fig. 2.15).

The Stellaris (Bausch & Lomb) offers new tubing technology called stable chamber tubing system. This kit consists of tubes integrated with a micromesh filter. The tubes have reduced diameter and the wall is much more durable. These modifications help to achieve greater power of fluidics and reduces postocclusion surge (Fig. 2.16).

2.8 Is MICS Worthwhile?

2.8.1 Clinical Outcome

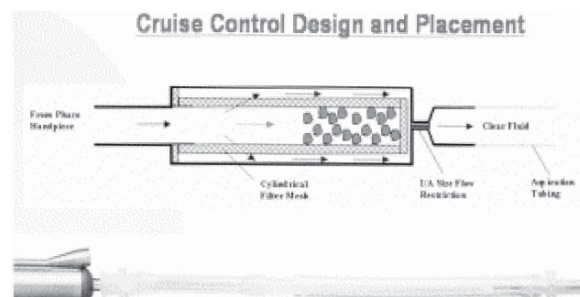


Fig. 2.14 Cruise control[™] system (STAAR Surgical, Monrovia, CA, USA)

Fig. 2.15 Stable chamber system (Bausch & Lomb, Rochester, NY, USA)



Fig. 2.16 Stable chamber tubing system (Bausch & Lomb)



Summary for the Clinician

- Flow restrictor makes the procedure safer, helps to achieve greater power of fluidics, and reduces postocclusion surge

One of the most important achievements of MICS is the reduction of the ultrasonic (US) power delivered into the eye. The nucleus breaking is done by mechanical movements of tools, high volume fluidics activity, and US power in the cataract surgery system. The total effective US power and total ultrasound time can be diminished in MICS surgery. Alio et al. indicated that the MICS surgery technique compared to standard coaxial phacoemulsification diminishes the mean incision size with statistical significance ($p < 0.001$), mean total phacoemulsification percent ($p < 0.001$), and mean effective phacoemulsification time ($p < 0.001$) [8]. Kahraman et al. show that in MICS the mean ultrasound time is statistically lower than in the coaxial group [12]. In Kurz et al., the microincision group had shorter EPT, and BCVA improved more rapidly than in the coaxial group [13]. Also, Cavallini et al. explain that microincision surgery can be less invasive and safer, resulting in less postoperative intraocular inflammation, fewer incision related complications, and shorter surgical time [11].

For the corneal endothelium, the clinical evaluations after MICS are variable, but most of them indicate that there is no difference between the coaxial and MICS group. Crema et al. indicate in their MICS and coaxial surgery comparative study with 1-year follow-up that central endothelial cell loss can be significant in the MICS group after 1 year. This study also shows that endothelial

cell loss 6 months after surgery did not change [32]. Wilczynski et al. did not find any difference in endothelial cell loss between the MICS and standard phacoemulsification group: the endothelial cell loss was similar in both groups and the difference was not statistically significant [33]. Kahraman et al. confirm this in their investigation [12]. Also, Mencucci et al. report that the endothelial cell loss was similar in the MICS and coaxial groups [19].

2.8.2 Outcome of the Incision

MICS is performed using new technology, so the US tip does not need to be extensively cooled. Using rapid on-off cycles you can reduce the power delivered to the tip. Donnenfeld et al. showed that the increase of temperature during bimanual phacoemulsification can be lower than temperature increase during coaxial phacoemulsification, and no wound damage was observed [5].

Experimental models of sleeveless bimanual phacoemulsification indicate that advanced microburst or hyperpulse technology does not enhance corneal temperature over the corneal damage threshold and, additionally, did not pass 39.0°C even with tip occlusion [4]. The total amount of US power used in MICS surgery is much lower than the power which can damage the cornea [34]. The sleeveless US tip does not deform the incision and there is a sufficient flow to cool the tip during phacoemulsification so the risk of thermal burn is minimal [9]. Additionally, the corneal swelling is much less significant in smaller incisions than in standard coaxial incisions [35].

The problem with leakage after the wound stress has been described [25]. However, the integrity of the wound can be achieved using MICS tools and the new Alio's

MICS flat instruments. The incision can be tight with no leakage and the tissues are not stressed. The sub-2.0-mm MICS incision has good self-sealing ability and, additionally, does not cause post-operative astigmatism in most cases [8].

2.8.3 Astigmatism Control with MICS

Among the major advantages of MICS is the reduction of surgical trauma resulting in a reduction of surgically-induced astigmatism (SIA) and aberrations and improvement of the optical quality of the cornea after surgery, thus leading to improvement of visual outcome and high patient satisfaction [7, 36].

Degraded optical quality of the cornea after incisional cataract surgery would limit the performance of the pseudophakic eye. Thus, it is important not to increase nor to induce astigmatism and/or corneal aberrations after cataract surgery [17]. Even with MICS, we could achieve reduction of astigmatism and higher order corneal aberrations [37].

The optical quality of the cornea plays an important role in the recovery of the visual function after cataract surgery, and this is determined by a combination of corneal and internal aberrations generated by the intraocular lens (IOL) and those induced by the surgery. These corneal refractive changes are attributed to the location and size of the corneal incision. The smaller the incision, the lower the aberrations, and the better the optical quality [38].

We have described the improved control of SIA with MICS when compared to conventional 3-mm phacoemulsification. A great advantage of MICS is the reduction of SIA and also that the microincisions do not produce an increase in astigmatism [8]. The shorter the incision, the less the corneal astigmatism, as it was estimated that the magnitude of the SIA studied by vector analysis is around 0.44 and 0.88 D, rising as the size of the incision increases [28, 39]. This is considered important because cataract surgery today is considered more and more a refractive procedure [8].

Also, small-incision surgery (3.5-mm incision without suture) does not systematically degrade the optical quality of the anterior corneal surface. However, it introduces changes in some aberrations, especially in nonrotationally symmetric terms such as astigmatism, coma, and trefoil [18]. Therefore, one has to expect better results and fewer changes with sub-2-mm incision (MICS).

This is supported by the finding that the corneal incision of <2 mm had no impact on corneal curvature [16, 37, 40]. Going hand in hand with the modern concept

of making cataract surgery a refractive procedure, one can control and even decrease astigmatism and HOA by using MICS, which is state of the art.

2.8.4 Corneal Aberration Control with MICS

Nowadays, cataract surgery is not only removal of an opaque lens, but it is also a part of refractive surgery. The technical progress has generated high standards of ophthalmic machines and tools. We can obtain precise intraocular lens (IOL) power calculation, reduce residual astigmatism, and do surgery without SIA. Corneal refractive surgery becomes more popular and more excellent. For this reason, the lenses we are using should be perfect. Optical quality of MICS IOL

Our experience with MICS has proved its effectiveness in stabilizing the corneal optics after surgery without degradation of the corneal optical quality [15]. Thus, for a MICS IOL to fulfill this advantage, it should help to improve the control of the optical performance of the human eye. Consequently, such IOL should be aberration and scattering free, not cause night-vision complaints such as halos and glare, and have similar or even better optical outcome when compared to conventional lenses [7].

The optical quality of the pseudophakic eye is largely affected by aberrations induced by the implanted IOL. These aberrations depend on two characteristics of the lens, thickness and surface quality, and will vary depending on the type of IOL implanted [21].

Among the currently available MICS IOLs, only a few of them have been evaluated from the optical quality point of view. Generally, they obtain optical quality and biocompatibility similar to conventional intraocular lenses *in vivo* [7, 21].

For Acri.Smart IOLs (Acri-Tec, Hennigsdorf, Berlin, Germany), studying the point spread function (PSF) before and after pushing the lens through the Acri.Glide cartridge (Acri-Tec), revealed no difference between the Acri.Smart lens before and after. This was further supported by an interesting study comparing the retinal image quality after implantation of two MICS IOLs and a conventional IOL, by evaluating the modulation-transfer function (MTF), 0.1 and 0.5 values for Acri.Smart and ThinOptX UltraChoice 1.0 IOL (ThinOptX, Abrindon, Virginia, USA) for MICS versus AcrySof conventional lens (AcrySof MA60BM; Alcon Laboratories, Ft Worth, USA), with no statistical difference between all of these lenses [21] (Table 2.4). Also, the manufacturing company studied the MTF for the ThinOptX MICS IOL, concluding that each stepped ring provides the same optical information to the same focal

Table 2.4. MTF value of Acri.Smart IOL, ThinOptX IOL, and AcrySof IOL [7]

IOL type	Incision size (mm)	Mean IOL power (D \pm SD)	Mean after surgery defocus equivalent (D \pm SD)	Mean BCVA after surgery	Mean spatial frequency (cpd) at 0.5 MTF \pm SD	Mean spatial frequency (cpd) at 0.1 MTF \pm SD
Alcon AcrySof MA60BM	3.2	19.86 \pm 6.21	1.13 \pm 0.72	20/20	2.647 \pm 0.833	8.720 \pm 3.074
ThinOptX ultraChoice 1.0	1.6–1.8	20.39 \pm 1.05	0.88 \pm 0.35	20/20	2.601 \pm 0.986	8.814 \pm 4.380
Acri.Smart 48S	1.6–1.8	23.25 \pm 4.6	1.00 \pm 0.63	20/20	3.453 \pm 0.778	11.418 \pm 2.574

IOL Intraocular lens, BCVA best-corrected visual acuity, MTF modulation transfer function




Fig. 2.17 AcriLisa 366D ACRITEC, bifocal, aberration correcting, aspherical, foldable one piece lens for capsular capsule fixation and microincision (MICS)

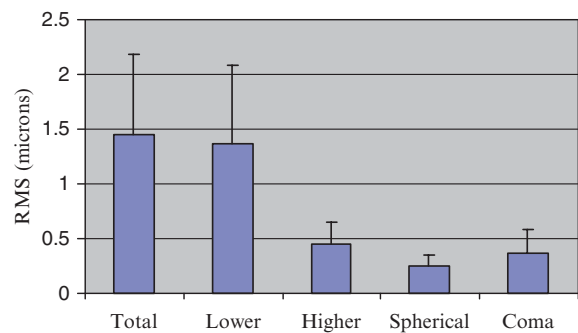


Fig. 2.18 RMS values and standard deviation of total, lower order, higher order, spherical and coma-like intraocular aberrations

point on the retina and MTF and visual acuity, therefore providing excellent refractive design [7]. Recently, the aberration-correcting effect of ThinOptX IOL has been evaluated by comparing the spherical aberration between ThinOptX and Alcon Acrysof lenses. The results demonstrated that although there was no statistically significant difference in the root mean square (RMS) for spherical aberration the ThinOptX eyes showed smaller spherical aberrations, being designed for negative spherical aberration [41].

Recently, we evaluated a new MICS multifocal IOL, the Acri.LISA 366D (Acri-Tec) (Fig. 2.17) [42]. We analyzed objectively the intraocular optical quality in vivo of this diffractive asymmetrical light distribution multifocal IOL. The main outcomes were RMS values for intraocular aberrations, Strehl ratio, and the MTF (0.5 and cut-off), using an intraocular optical analysis model [43]. The Acri-Tec Acri.LISA 366D showed excellent intraocular optical performance as demonstrated by good values for the intraocular optical aberrations, Strehl ratio and MTF, (Figs. 2.18 and 2.19).

Such an effect can be additionally explained by Acri.LISA neutral asphericity and aberration-correcting profile [42].

Finally, we can conclude that for an ideal MICS IOL it is not enough to have low optical aberrations but it must also be able to compensate for corneal aberrations (coupling of two optical systems), an effect which can work with MICS in stabilizing corneal optical quality. The evaluation of MTF in vivo may be the best method to study the optical quality of eyes implanted with IOLs which could be objectively measured by the Optical Quality Analysis System (OQAS, Visiometrics S.L. Tarrasa, Spain) which also calculates the PSF. Consequently, MICS IOLs perform well inside the eye; their folding and unfolding does not cause structural and functional defects, which together with neuroprocessing allows excellent IOL optical performance in vivo [7, 8, 21].

The other study shows that UltraChoice 1.0 ThinOptX and Acri.Smart 48S MICS lenses have excellent MTF performance. In this study, there was no difference between

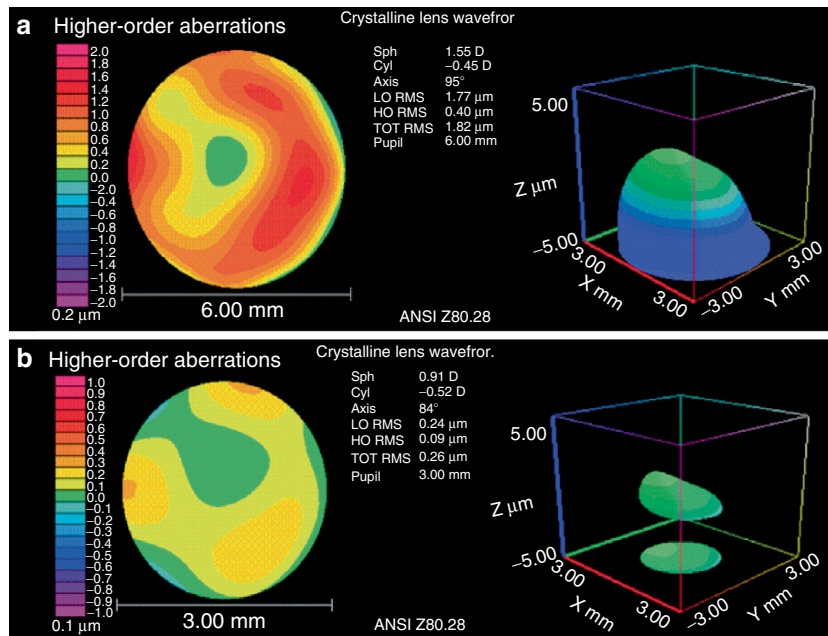


Fig. 2.19 Wavefront intraocular aberrations after surgery of the AcriLISA 366D at both (a) 6-mm and (b) 3-mm pupil diameters [42]

these lenses and AcrySof MA60BM lenses. This indicates that there is no difference between MICS lenses and conventional cataract lenses. Small incision, folding and unfolding did not cause structural and functional defects [7, 21] (Figs. 2.20 and 2.21).

Summary for the Clinician

- MICS surgery technique compared to standard coaxial phacoemulsification:
 - Diminishes the mean incision size
 - Diminishes the mean effective phacoemulsification time
 - Diminishes surgical time
 - Diminishes postoperative intraocular inflammation
 - Diminishes complications
 - Diminishes surgically induced astigmatism
- With MICS, we can achieve a reduction of astigmatism and higher order corneal aberrations

2.9 End of the Surgery

Endophthalmitis prevention is the last part of the surgery. The procedure is finished by injecting 0.1–0.2 ml of cefuroxime into the anterior chamber. Next, corneal wound hydration should be done to close the wound and 2–3 drops of povidone iodine administered into the

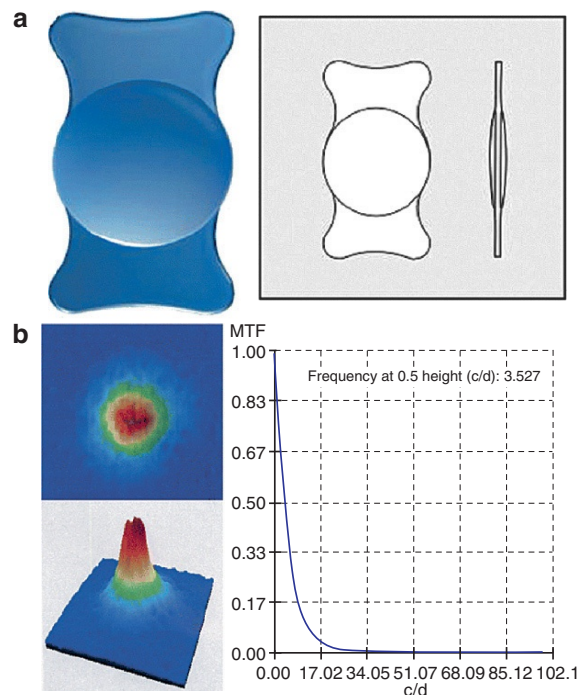


Fig. 2.20 Acri.Smart lens (a) Acri.Smart lens. (b) Optical quality analysis system (OQAS) image comparison with the PSF of treated and untreated Acri.Smart IOL [7]

conjunctival sac. The state of incisions is verified in the slit lamp after half an hour. If leakage appears, the procedure of hydration should be repeated.

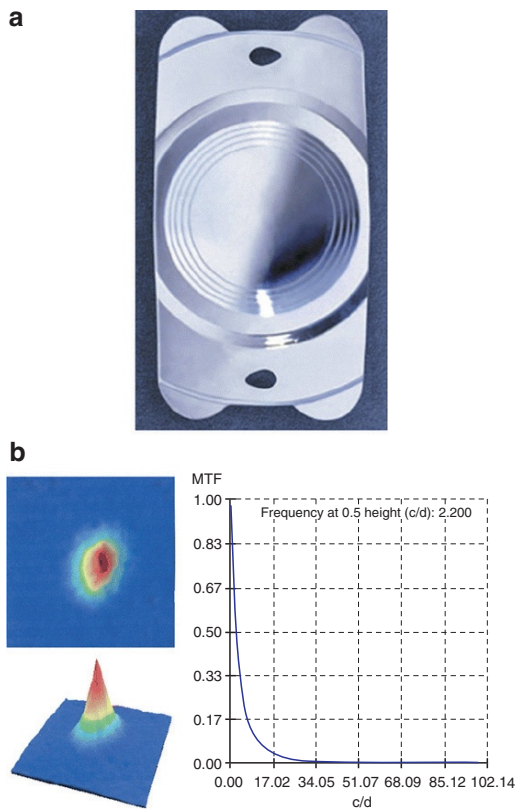


Fig. 2.21 The ThinOptX IOL. (a) The ThinOptX IOL. (b) OQAS image comparison with the MTF of treated and untreated ThinOptX IOL [7]

2.10 Future of MICS

Unfortunately, new ideas in the field of the cataract surgery are limited by technical possibilities. However, a major problem remains in the possibility of lens compression. The foldable intraocular lenses are compressed only to 1.5 mm of incision. MICS makes the wound smaller and will evolve into reduction of incision, energy, and eye injury. The future belongs to the miniaturization of the tools and the wound size. A minimization of the energy and manual activities must occur in the anterior chamber. The problem of energy still remains a problem to be solved. The next step could be subsonic oscillation and lasers. In the future, the laser will supply the ultrasound energy and may become the standard technology for breaking nuclei of the lenses. However, it is not possible to remove hard cataracts with the help of new types of lasers at the present stage of technology. Also in the future, the ultrasound energy and laser energy connection can bring the desired effect. Laser energy will make it possible to remove cataracts with incisions smaller than 0.7 mm.

Managing the flow of liquids will also change together with the development of infusion and aspirating pumps. The problem with providing large amounts of liquids by irrigation tools still occurs. The development of highly efficient fluid injectors and new liquid substances with a different viscosity will be the perfect solution.

MICS development and evolution will be necessary in the future.

References

1. Shearing SP, Relyea RL, Loaiza, Shearing RL (1985) Routine phacoemulsification through and they millimeter non-sutured incision. *Cataract* 2:6–11
2. Alió JL (2006) What is the future of cataract surgery? *Ocular Surg News* 17:3–4
3. Alio JL, Rodriguez Prats JL, Galal A (2004) MICS Microincision Cataract Surgery. Highlights of Ophthalmology International, Miami
4. Braga-Mele R (2006) Thermal effect of microburst and hyperpulse settings during sleeveless bimanual phacoemulsification with advanced power modulations. *J Cataract Refract Surg* 32:639–42
5. Donnenfeld ED, Olson RJ, Solomon R, Finger PT, Biser SA, Perry HD, Doshi S (2003) Efficacy and wound-temperature gradient of WhiteStar phacoemulsification through a 1.2 mm incision. *J Cataract Refract Surg* 29:1097–100
6. Soscia W, Howard JG, Olson RJ (2002) Bimanual phacoemulsification through 2 stab incisions. A wound-temperature study. *J Cataract Refract Surg* 28:1039–43
7. Alio JL, Rodriguez-Prats JL, Galal A (2006) Advances in microincision cataract surgery intraocular lenses. *Curr Opin Ophthalmol* 17:80–93
8. Alio JL, Rodriguez-Prats JL, Galal A, Ramzy M (2005) Outcomes of microincision cataract surgery versus coaxial phacoemulsification. *Ophthalmology* 112:1997–2003
9. Tsuneoka H, Shiba T, Takahashi Y (2001) Feasibility of ultrasound cataract surgery with a 1.4 mm incision. *J Cataract Refract Surg* 27(6):934–40
10. Khng C, Packer M, Fine IH, Hoffman RS, Moreira FB (2006) Intraocular pressure during phacoemulsification. *J Cataract Refract Surg* 32:301–8
11. Cavallini GM, Campi L, Masini C, Pelloni S, Pupino A (2007) Bimanual microphacoemulsification versus coaxial miniphacoemulsification: prospective study. *J Cataract Refract Surg* 33:387–92
12. Kahraman G, Amon M, Franz C, Prinz A, Abela-Formanek C (2007) Intraindividual comparison of surgical trauma after bimanual microincision and conventional small-incision coaxial phacoemulsification. *J Cataract Refract Surg* 33(4):618–22

13. Kurz S, Krummenauer F, Gabriel P, Pfeiffer N, Dick HB (2006) Biaxial microincision versus coaxial small-incision clear cornea cataract surgery. *Ophthalmology* 113:1818–26
14. Tanaka T, Koshika S, Usui M (2007) Cataract surgery using the bimanual phacoemulsification technique with an Accurus system and Mackool microphaco tip. *J Cataract Refract Surg* 33:1770–4
15. Elkady B, Alió JL, Ortiz D, Montalbán R (2008) Corneal aberrations after microincision cataract surgery. *J Cataract Refract Surg* 34:40–5
16. Olson RJ, Crandall AS (1998) Prospective randomized comparison of phacoemulsification cataract surgery with a 3.2-mm vs a 5.5-mm sutureless incision. *Am J Ophthalmol* 125:612–20
17. Yao K, Tang X, Ye P (2006) Corneal astigmatism, high order aberrations, and optical quality after cataract surgery: microincision versus small-incision. *J Refract Surg* 22:1079–82
18. Guirao A, Tejedor J, Artal P (2004) Corneal aberrations before and after small-incision cataract surgery. *Invest Ophthalmol Vis Sci* 45:4312–9
19. Mencucci R, Ponchietti C, Virgili G, Giansanti F, Menchini U (2006) Corneal endothelial damage after cataract surgery: Microincision versus standard technique. *J Cataract Refract Surg* 32:1351–4
20. Alió JL, Rodriguez-Prats JL, Vianello A, Galal A (2005) Visual outcome of microincision cataract surgery with implantation of Acri.Smart Lens. *J Cataract Refract Surg* 31:1549–56
21. Alió JL, Schimchak P, Montés-Micó R, Galal A (2005) Retinal image quality after microincision intraocular lens implantation. *J Cataract Refract Surg* 31:1557–60
22. Assaf A, El-Moatassem Kotb AM (2007) Feasibility of bimanual microincision phacoemulsification in hard cataracts. *Eye* 21:807–11
23. Kaufmann C, Peter J, Ooi K, Phipps S, Cooper P, Goggin M (2005) The Queen Elizabeth Astigmatism Study Group. Limbal relaxing incisions versus on-axis incisions to reduce corneal astigmatism at the time of cataract surgery. *J Cataract Refract Surg* 31:2261–5
24. Nichamin L (2003) Treating astigmatism at the time of cataract surgery. *Curr Opin Ophthalmol* 14:35–8
25. Berdahl JP, DeStafeno JJ, Kim T (2007) Corneal wound architecture and integrity after phacoemulsification evaluation of coaxial, microincision coaxial, and microincision bimanual techniques. *J Cataract Refract Surg* 33:510–5
26. Mehran T, Behrens A, Newcomb R, Nobe M, Saedi G, McDonnell P (2005) Acute endophthalmitis following cataract surgery and systematic review of the literature. *Arch Ophthalmol* 123:613–20
27. Nagaki Y, Hayasaka, Kadoi C, Matsumoto the M, Yanagisawa, Watanabe K, Watanabe K, Hayasaka Y, Ikeda N, Sato, Kataoka Y, Togashi M, Abe J (2003) Bacterial endophthalmitis after small-incision cataract surgery: effect of incision placement and intraocular lens type. *Cataract Refract Surg* 29:20–6
28. Vasavada AR, Singh R, Apple DJ, Trivedi RH, Pandey SK, Werner L (2002) Effect of hydrodissection on intraoperative performance: randomized study. *J Cataract Refract Surg* 28:1623–8
29. Peng Q, Apple DJ, Visessook N, Werner L, Pandey SK, Escobar-Gomez M, Schoderbek R, Guindi A (2000) Surgical prevention of posterior capsule opacification. Part 2: Enhancement of cortical cleanup by focusing on hydrodissection. *J Cataract Refract Surg* 26:188–1897
30. Tsuneoka H, Hayama A, Takahama M (2003) Ultrasmall-incision bimanual phacoemulsification and AcrySof SA30AL implantation through a 2.2 mm incision. *J Cataract Refract Surg* 29:1070–6
31. Chang DF (2004) 400 mm Hg high-vacuum bimanual phaco attainable with the staar cruise control device. *J Cataract Refract Surg* 30:932–3
32. Crema AS, Walsh A, Yamane Y, Nosé W (2007) Comparative study of coaxial phacoemulsification and microincision cataract surgery. One-year follow-up. *J Cataract Refract Surg* 33:1014–8
33. Wilczynski M, Drobniowski I, Synder A, Omulecki W (2006) Evaluation of early corneal endothelial cell loss in bimanual microincision cataract surgery (MICS) in comparison with standard phacoemulsification. *Eur J Ophthalmol* 16:798–803
34. Soscia W, Howard JG, Olson RJ (2002) Microphacoemulsification with WhiteStar: a wound-temperature study. *J Cataract Refract Surg* 28:1044–6
35. Fine IH, Hoffman RS, Packer M (2007) Profile of clear corneal cataract incisions demonstrated by ocular coherence tomography. *J Cataract Refract Surg* 33:94–7
36. Naeser K, Knudsen EB, Hansen MK (2002) Bivariate polar value analysis of surgically induced astigmatism. *J Refract Surg* 18:72–8
37. Jiang Y, Le Q, Yang J, Lu Y (2006) Changes in corneal astigmatism and high order aberrations after clear corneal tunnel phacoemulsification guided by corneal topography. *J Refract Surg* 22:1083–8
38. Holladay JT (2003) Optical quality and refractive surgery. *Int Ophthalmol Clin* 43:119–36
39. Simsek S, Yasar T, Demirok A, Cinal A, Yilmaz OF (1998) Effect of superior and temporal clear corneal incisions on astigmatism after sutureless phacoemulsification. *J Cataract Refract Surg* 24:515–8
40. Oshika T, Tsuboi S (1995) Astigmatic and refractive stabilization after cataract surgery. *Ophthalmic Surg* 26:309–15

41. Ouchi M, Kinoshita S (2007) Aberration-correcting effect of ThinOptX IOL. *Eye*, Dec 21. doi:10.1038/sj.eye.6703068
42. Alió JL, Elkady B, Ortiz D, Bernabeu G (2008) Clinical outcomes and intraocular optical quality of a diffractive asymmetrical light distribution multifocal intraocular lens (Acri.LISA 366D). *J Cataract Refract Surg* 34:942–8
43. Ortiz D, Alió JL, Bernabeu G, Pongo V (2008) Optical quality performance inside the human eye of monofocal and multifocal intraocular lenses. *J Cataract Refract Surg* 34:755–62

Capsular Tension Rings

3

Rupert Menapace

Core Messages

- A CTR withholds optic decentration and tilt
- A CTR supports localized dehiscence and general weakness of the zonules
- A CTR increases control of a posterior capsulorhexis
- Tinted CTRs with integrated shields compensate for iris kolobomas and aniridia
- A zonular defect extending over more than half of the circumference requires additional suture-fixation of the CTR (Cionni ring)
- Very large capsular defects or severe zonular weakness are best managed by two Cionni rings
- Capsular tension segments may be used with iris retractors intraoperatively, and with scleral fixation sutures postoperatively
- A CTR may counteract after-cataract formation by avoiding stretch folds and capsular bag ovalization, and by reducing the width of the retro-optical space
- The capsular bending ring (CBR) demonstrably significantly reduces posterior capsule opacification, and avoids fibrotic whitening and contraction of the anterior capsule leaf
- Foldable closed rings allow for easy implantation and circumferential capsular bending, but require additional anterior capsule polishing
- Generally, a capsular ring should be implanted into the evacuated capsular bag following thorough cortex fibre aspiration
- Though use of an injector is more convenient, bimanual implantation minimizes capsular deformation and zonular stress and the risk of capsular entanglement
- Sizing the anterior capsulorhexis so as to only barely overlap the optic counteracts excessive capsular bag shrinkage especially with PEX
- With PEX, progressive zonular failure often occurs: timely suture-fixation of a CTR avoids consecutive luxation of the CTR-IOL-bag complex

3.1 History of the Concept

In 1991, Hara and co-workers were the first to publish the idea of inserting an endocapsular ring into the capsular bag [1]. They used a closed ring made of soft silicone with a groove on its inner surface for the loops of the intraocular lens (IOL). The ring was thought not only to maintain the circular contour of the capsular bag equator, but also to withhold lens epithelial cell (LEC) migration. The inability of the closed silicone ring to adapt to all capsular bag sizes obviated routine use in human eyes. At about the same time, Nagamoto independently presented the concept of using an open ring made of rigid poly (methyl methacrylate) (PMMA) in order to maintain the circular

contour of the capsular bag and thus avoid deformation or decentration of soft intraocular lenses [2]. In cadaver eyes, a 12.5-mm ring diameter was found most appropriate for the human capsular bag [3]. Implantation of a PMMA ring in human eyes was first reported in 1993 (“The Capsular Ring: A New Device for Complicated Cataract Surgery,” film presented at the third American-International Congress of Cataract, IOL and Refractive Surgery, Seattle, May 1993). This ring was produced by Morcher (Stuttgart, Germany) and marketed under the name ‘capsular tension ring’ (CTR). It carried characteristic eyelets at its ends for atraumatic insertion and better manipulation. This, and similar CTR types soon gained widespread use especially in Europe. The various brands

differ significantly in resilience as defined by the spring constant [4]. While softer rings cause less zonular stress during insertion, more rigid rings counteract fibrotic capsular bag contraction. Figures 3.1 and 3.2 depict the various CTR modifications to be described in the chapters to follow.

Summary for the Clinician

- The capsular ring concept was first published by Hara et al. [1] (closed silicone ring)
- An open PMMA was ring first presented by Nagamoto [3]
- The first implantation of a ‘capsular tension ring’ in humans was reported by Legler et al. in 1993

3.2 Applications and Designs

3.2.1 Impact of a CTR on IOL Positioning and Refraction

As the capsular bag collapses, fibrosis sets in. Especially when the anterior capsulorhexis is not perfectly circular or centred, asymmetric shrinkage may ensue. A CTR equally distends the capsular bag. With soft haptic intraocular lenses (IOLs), it withholds secondary optic decentration and tilt by promoting uniform circumferential rhexis optic contact and thus symmetric capsular bag contraction [5]. Rigid and oversized haptics may significantly distort the capsular bag particularly in pediatric eyes [6]. A CTR avoids capsular bag ovalization and stretch fold formation in the posterior capsule which may otherwise be frozen in by collagen deposition. The uniform

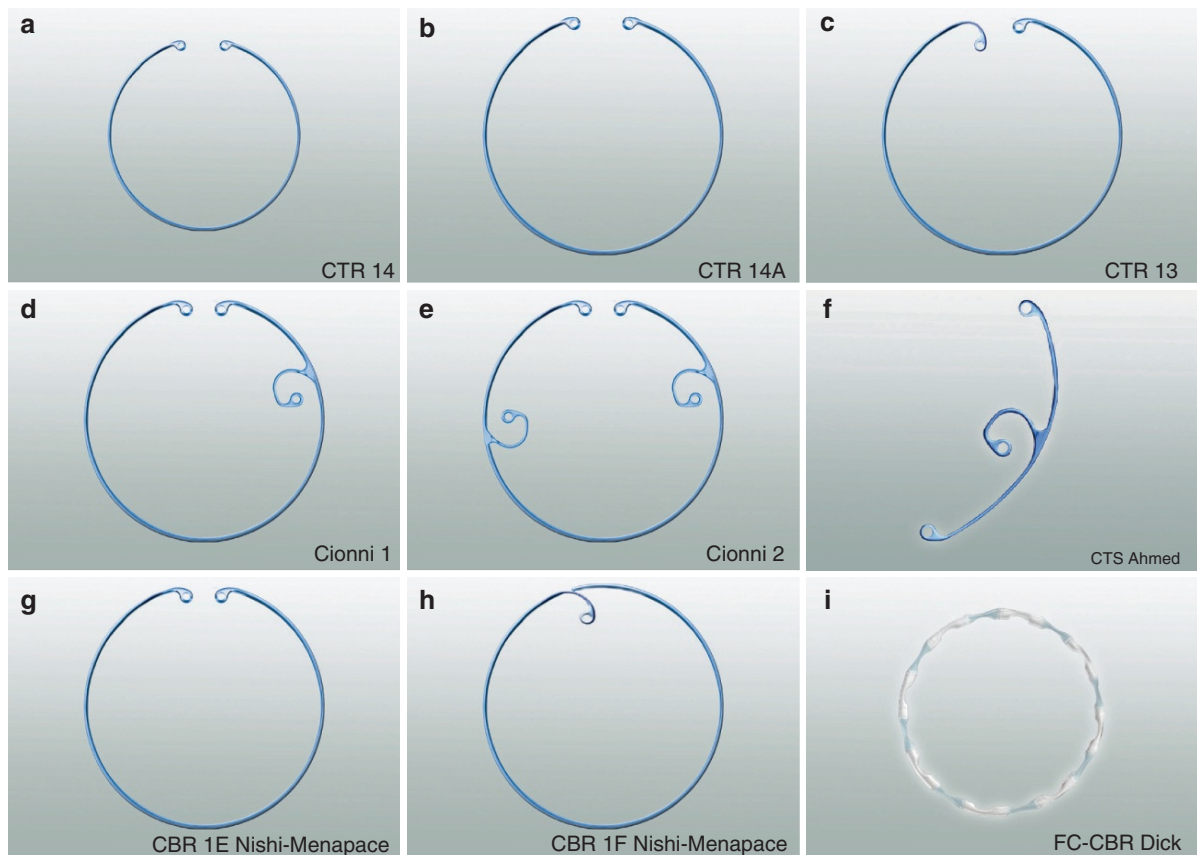


Fig. 3.1 The original ‘capsular tension ring’ (Legler: (a),(c)) and the various devices derived from it: sulcus suture rings (Cionni: (d), (e)), capsular tension segment (Ahmed: (f)), capsular bending rings (Nishi-Menapace: (g), (h)), and foldable closed ring (Dick: (i))




Fig. 3.2 Iris koloboma (*left*) and aniridia CTRs (*center*) with shields made from tinted PMMA (V. Rasch, by Morcher). *Right*: Artificial silicone iris (H.R. Koch, by Schmidt Intraokularlinsen)

circular distension and thus symmetric shrinkage of the capsular bag provided by the CTR was also shown to slightly enhance the predictability of the refractive outcome [7].

Summary for the Clinician

- A CTR withholds optic decentration and tilt especially with soft-haptic IOLs and a decentered capsulorhexis
- A CTR slightly enhances refractive predictability

3.2.2 The CTR as a Surgical Tool

A CTR not only enhances postoperative centration of the IOL optic, but also intraoperative control and safety during phacoemulsification, cortex aspiration, and IOL placement with localized defects or general weakness of the zonular apparatus.

3.2.2.1 Localized Zonular Dehiscence

Such defects may be pre-existent in conjunction with a systemic disease like Marfan's syndrome, or traumatic following ocular contusion or aspiration of the capsular bag equator. This was the indication the CTR was first used for in humans. Its efficacy to compensate for localized zonular dehiscence has been demonstrated in vitro [8]. Depending upon whether the defect is pre-existent or created during the surgery, the CTR is preferably inserted

at different stages of the operation. *With a pre-existent dehiscence*, the CTR may be inserted prior to phacoemulsification, following gentle thorough hydrodissection and lens content rotation, in order to ensure that all cortico-capsular adhesions have been severed. Then, additional cortico-capsular viscodissection with a dispersive ocular visco-surgical device (OVD) like methylcellulose is additionally performed. The OVD cushion between capsule and cortex thereby created avoids capsular entanglement when the leading eyelet of the CTR is advanced. A CTR is used the ends of which are not bent up like a ski tip. When in place, the CTR avoids inadvertent aspiration of the capsule during lens removal, which otherwise may extend the area of dehiscence. In addition, it withholds irrigation fluid from running behind the capsular diaphragm, which otherwise may cause anterior movement of the latter or vitreous prolapse, and prevents vitreous aspiration. *If zonular dehiscence occurs during phacoemulsification or cortex aspiration*, the surgery is interrupted. The irrigation bottle is slowly lowered, the anterior chamber tamponaded, the capsular bag reformed with a highly cohesive OVD, and a CTR inserted. A CTR has also been helpful in managing lens kolobomas with pre-existent sectorial lack of zonular fibres [9].

3.2.2.2 Generalized Zonular Weakness

This may be part of a systemic disease like Marchesani syndrome where it causes spherophakia, but most often occurs with pseudoexfoliation (PEX) syndrome, which is also a systemic condition. Longstanding silicone tamponade may also induce zonular atrophy. Zonular degradation

tends to be progressive and may end up in spontaneous luxation of the entire capsule-implant complex (see Sect. 4.2.2).

Surgical Measures to Avoid Intraoperative Damage of Weak Zonules

Complete cortico-capsular cleavage by thorough hydrodissection and rotation of the freed lens contents is again mandatory. Timing of CTR insertion depends on the course of surgery. Generally, the CTR should be inserted after cortex removal, since the ring impedes residual cortex fiber peeling from the capsular equator ('clothesline phenomenon'). Also, CTR implantation causes more capsular stress and shearing with the lens contents in place [10]. When a pronounced zonular laxity causes capsular bag collapse with wrinkling or forward bulging of the posterior capsule due to retro-capsular fluid accumulation, early CTR placement reduces the risk of capsular aspiration and thus that of creating zonular or capsular defects. An anchor suture threaded through the leading eyelet is helpful in preventing or reversing capsular entanglement by the CTR tip. Inserting the CTR manually at an acute angle with regard to the capsular bag equator while repeatedly extending the fornix with a cohesive OVD minimizes zonular traction when advancing it. Also, care must be taken not to overstress the zonules when aspirating the residual cortex fibers with the CTR in place, which may cause immediate dehiscence or accelerate decompensation of the zonules later on. Traction during cortex fiber aspiration must be directed tangentially, and residual cortex fibers may be better left behind than trying to aggressively pull them loose.

Surgical Measures to Counteract Postoperative Capsular Shrinkage with Weak Zonules

Due to the reduced counterforce provided by the weakened zonules, the anterior capsule leaf tends to contract. This causes stress and elongation of the zonules, accelerating general decompensation. To avoid this, the following measures of precaution are recommended. The capsulorhexis opening should be designed so as to only barely overlap the optic periphery [11]. A too small or asymmetric opening should be enlarged at the end of the surgery, reshaping the capsulorhexis by closely following the optic rim. Contraction may also be avoided by removing the anterior LEC layer using appropriate instrumentation [12, 13]. This must be done with the CTR already in place and with low vacuum settings in order to minimize zonular stress. When, after CTR and IOL implantation, vibrations with ocular saccades and ovalization of the capsular bag with stretch folds indicate excessive general weakness, a

second CTR may be inserted to enhance zonular support [9, 14]. However, its additional weight may also accelerate delayed zonular failure. In cases of severe weakness, two CTRs with an additional fixation hook (Cionni rings [15], see Sect. 2.3.2) may be inserted and suture-fixed to the ciliary sulcus. Suturing the eyelets together with 9-0 nylon or using rings with a locking mechanism is not recommended. Contraction forces may distort the ring or cause cheese wiring, and none of the locking mechanisms suggested has been proven to be effective.

3.2.2.3 Posterior Capsulorhexis

Primary posterior capsulorhexis (PPC) with optional optic buttonholing is a powerful surgical means to avoid after-cataract formation [16–18]. Insertion of a CTR significantly increases the surgical control of PPC. This is especially true for overly large capsular bags or lax zonules. The CTR evenly stretches out the posterior capsule, which enhances the control of both central puncturing and tearing of the capsule. As the capsule is brought under tension, it is moved forward, thereby increasing its distance to the anterior hyaloid. When tangentially punctured by a needle, the central posterior capsule is easily perforated and the risk of compromising the hyaloid surface decreased. The deepened Berger's space is more readily accessed by OVD and expanded towards the periphery. The equally distributed radial vector forces make both the correct estimation of the diameter and centered and circular shaping of the PPC much easier (Fig. 3.3). When additional posterior optic buttonholing is performed, the radial traction forces emanating from the haptic-optic junctions are absorbed and fully devolved to the extremely elastic posterior capsule [9]. With PPC alone, the uniform radial vector forces avoid ovalization of the PPC opening, which ensures circumferential contact between the PPC rim and the posterior optic surface. This is clinically relevant, since distortion causes gaping at the long axis of the ovalized PPC opening. This may give way to vitreous entanglement should the anterior hyaloid have been inadvertently punctured, which cannot be totally excluded. Circumferential apposition also reduces the risk of delayed PPC reclosure by LECs since a firm capsule-optic contact hinders them from accessing the posterior optic surface and the retrolental space.

3.2.2.4 Combined Cataract and Vitreous Surgery

With an IOL in place, visualization of the peripheral retina and vitreous base is impeded during vitrectomy. With IOL implantation being postponed until the end of surgery, the nondistended posterior capsule runs a risk

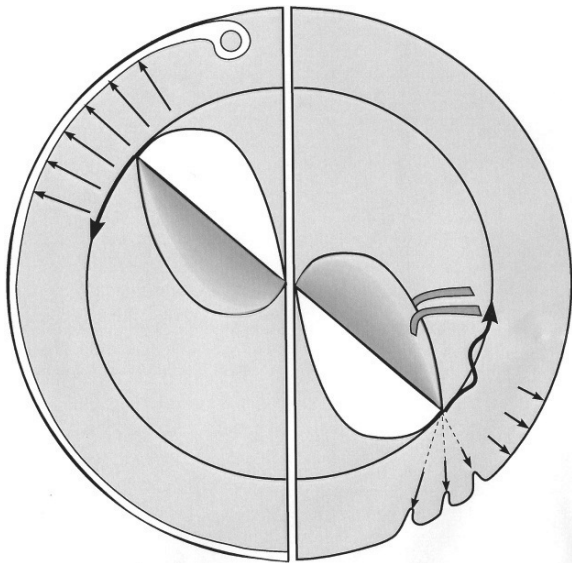


Fig. 3.3 A CTR, by equally distributing the radial vector forces, makes well-centered and circular shaping of the PPC much easier

of being inadvertently damaged by the vitrector. If this happens with the IOL implanted, the IOL may dislocate into the vitreous cavity. A CTR alone does not interfere with peripheral visualization, and significantly reduces the risk of a vitrector bite. If nonetheless this happens, the risk of posterior ring luxation is small. An anchoring suture through one of the eyelets will make retrieval of the ring easy should it occur.

With the necessity of a prolonged silicone oil tamponade, a CTR may guard against protracted zonular failure caused by zonular atrophy and secondary glaucoma caused by dissipation of emulsified silicone oil droplets into the anterior chamber. With the silicone oil in place, a CTR supports the zonules and enhances the control of the cataract surgery. If silicone oil removal is performed during cataract surgery, control of creating a PPC while tamponading the anterior chamber with a high-viscosity OVD is increased, as is stability of the capsular diaphragm while the silicone oil is rinsed out through the PPC opening into the anterior chamber and through the cataract incision out of the eye.

Summary for the Clinician

- A CTR is indicated with localized dehiscence and general weakness of the zonules
- Generally, the CTR is implanted after nucleus and cortex removal
- With larger pre-existing zonular defects, the CTR is inserted preferably before, with intra-operatively occurring defects during phaco and cortex aspiration

- With generalized zonular weakness, the CTR is preferably inserted after the evacuation of the lens contents
- A CTR increases control of a posterior capsulorhexis especially with weak zonules or an oversized capsular bag.
- A CTR protects the capsule diaphragm during vitrectomy without impeding visibility

3.2.3 Modified CTR for Special Purposes

3.2.3.1 CTRs for Iris Defects

CTR for Sector Kolobomas

The idea of integrating a sector shield into a CTR made from tinted PMMA was first brought up by V. Rasch (Fig. 3.2-left). When implanted, the CTR is rotated until the shield covers the iris defect (Fig. 3.4-left). CTRs with 60 and 90° shields are marketed by Morcher (Stuttgart, Germany). Two segmented CTRs can be combined side-by-side to cover larger kolobomas. Alternatively, an integrated system of iris reconstruction elements (Iris Prosthetic System, IPS[®]) is provided by Ophtec (Groningen, The Netherlands), which was developed by H. Hermeking to be used alone or in combination with a standard CTR.

The combined use of a standard and a koloboma shield CTR is especially advantageous following resection of a ciliary body tumor. Following decompression of the lens equator after tumor resection, the sectorial cataract progresses rapidly. While the capsular contour along the severed zonular section is maintained during cataract extraction by a standard CTR, a second CTR with an integrated shield covers the surgical sector koloboma [19]. The two CTRs are safely supported by the residual healthy zonules and provide for perfect and permanent centration of a foldable IOL (R. Menapace: Capsular tension rings for cataract and IOL surgery following penetrating cyclectomy. First Prize ASCRS Video Competition, San Diego, April 1995; Video Journal of Ophthalmology, August 1995, Vol. XI, No. 4).

CTR for Aniridia

V. Rasch also designed a multi-segmented koloboma ring to remedy aniridia. This ring carries 8 equidistant shields (Fig. 3.2-center). Two rings are implanted and offset to each other so that the shields of the anterior ring cover the interspaces between the shields of the posterior ring (Fig. 3.4-right). The IOL is placed behind both rings. This ring is produced by Morcher. Again, Ophtec alternatively

offers the IPS® elements developed by H. Hermeking which are used in conjunction with a standard CTR.

Recently, an artificial iris has been presented by Koch (H.R. Koch. Post-traumatic iris reconstruction, Main Symposium on Surgical Reconstruction of the Traumatized Eye, XXV Congress of the ESCRS, 8–12 September 2007, Stockholm) which allows to exactly mimic the color and structure of the contralateral iris. It is custom-made from a photograph of the contralateral iris and may be tailored according to the extension of the iris defect (Manufacturer: Dr. Schmidt Intraocular-linsen, St. Augustin, Germany; Fig. 3.2-right). It is made from silicone and is implanted folded through a small incision to be sutured to the ciliary sulcus. If long-term results confirm good intraocular tolerance, this device will replace shielded CTR with aniridia and larger iris kolobomas.

3.2.3.2 CTRs for Sulcus Suture Fixation

In cases of a large sectorial zonular defect extending over more than one-half of the circumference, a CTR may not be able to avoid decentration or tilting of the capsule-IOL complex. Therefore, other options must be resorted to. One is to extract the emptied capsular bag and resort to a sulcus-sutured or iris-fixated IOL. Alternatively, additional suture fixation may be used. For this purpose, R.J. Cionni added a fixation hook to the standard ring [15] (Fig. 3.1d). To ease implantation, the hook was positioned 90° away from the trailing ring opening. Thus, three-quarters of the ring are already inserted before the hook enters the eye, thereby reducing the risk of entanglement. For large zonular defects with intact residual zonules, a condition which may apply to Marfan's syndrome, a standard ring is preferably implanted after thorough

a

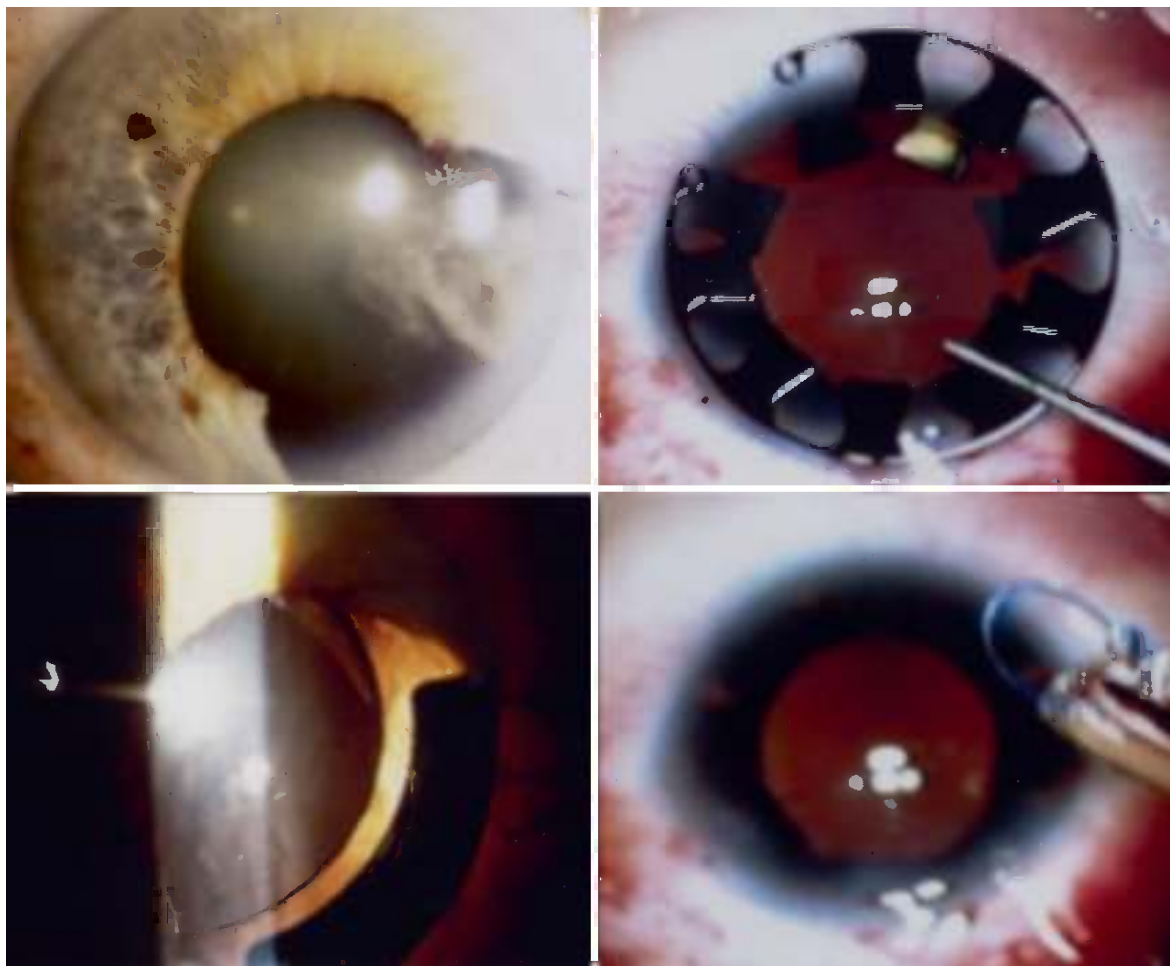


Fig. 3.4 (a) *Left:* Koloboma CTR shielding a large surgical koloboma. *Right:* Two multi-segmented CTRs implanted to remedy congenital aniridia. (b) Artificial silicone iris covering large iris defect (Courtesy P. Szurman, Tübingen)

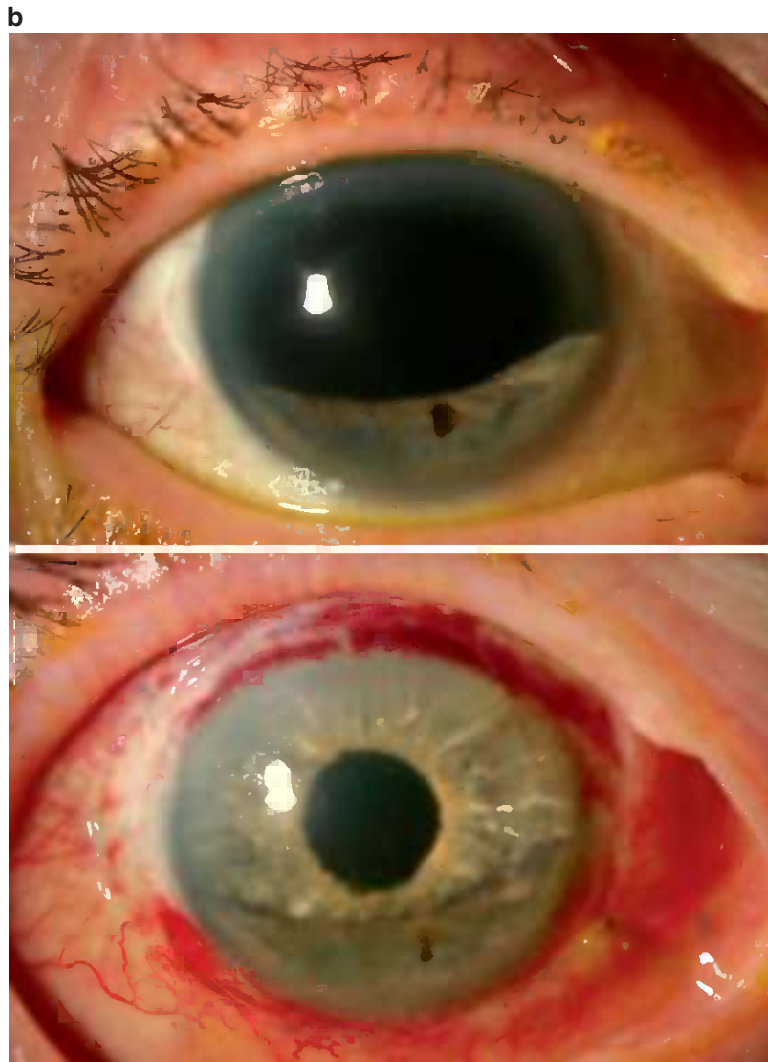


Fig. 3.4 (continued)

cortico-capsular hydro- and viscodissection. Then, a Cionni CTR is added with the hook positioned at the center of the zonular defect to be finally suture-fixated in the sulcus. Knotting the suture should be postponed to the very end of the surgery with the lens in place and the OVD evacuated in order to allow proper estimation of the suture tension for optimal optic centration. A Cionni ring is particularly helpful in the management of Marfan's syndrome [15, 20, 21].

With a zonular defect extending along almost all the circumference, or a severe and progressive zonular weakness causing phacodonesis, two-point sulcus suture fixation may be necessary. For these purposes, R.J. Cionni designed a CTR with two fixation hooks each positioned

90° away of both ring ends (Fig. 3.1e). However, insertion of this ring may be cumbersome, and decentration will ensue when the two trans-scleral sutures are not perfectly positioned 180° apart. Therefore, implantation of two rings with a single hook is preferred. This allows compensation of any offset between the scleral fixation sutures by simply rotating the two rings against each other.

3.2.3.3 Capsular Tension Segments

II Ahmed recently described a capsular tension segment (CTS) which provides intraoperative capsular support when being held with iris retractors inserted through paracentesis openings, and postoperative support after

having been sutured into the ciliary sulcus (Fig. 3.1f). When a large zonular defect or severe zonular weakness requires zonular support before cataract removal, insertion of a CTS causes minimal zonular stress compared to CTR implantation. When used as capsule retractors in place of iris retractors, CTSs avoid the risk of equatorial capsule expansion, retractor dislodgement, and anterior or posterior capsule tears [10].

Summary for the Clinician

- Sector defects of the iris and zonules following cyclectomy are best managed by the combined use of a standard and a koloboma shield CTR
- Aniridia may be remedied with two multisegmented CTRs
- Alternatively, sector kolobomas and aniridia can both be treated by the combined use of a CTR and iris reconstruction elements (Iris Prosthetic System, IPS)
- As another alternative, an artificial silicone iris has recently been developed
- A zonular defect extending over more than half of the circumference requires additional suture-fixation of the CTR
- The Cionni CTR carries a hook for suture-fixation in the sulcus and is especially helpful with Marfan's syndrome
- Very large zonular defects or severe zonular weakness are best managed by two Cionni rings
- Capsular tension segments may be used with iris retractors for intraoperative, and with scleral fixation sutures for postoperative stabilization of the capsular bag

3.2.4 The CTR as a Measuring Gauge

A CTR may be used to measure the actual capsular circumference by determining the distance between the ring ends. With an adequately dilating pupil, the eyelets of a standard CTR may be visualized gonioscopically and the distance in between measured with the slit-beam. Alternatively, radial extensions may be added to the CTR ends which indicate the distance between them (Fig. 3.5-right).

3.2.4.1 Quantification of the Diameter of the Evacuated Capsular Bag

This study was performed with standard CTRs. The capsular circumference was measured at 1 day with

two types of same-style CTRs with different diameters (Morcher Typ14, circle diameter 10 mm, and 14A, 12 mm). From the eyelet distances observed, the capsular diameter was calculated to be 10.34 ± 0.24 mm with the smaller and 11.09 ± 0.32 mm with the larger ring [22]. This revealed a small variability with one and the same ring being used, but a significant difference between the two rings documenting the equatorial stretchability of the capsular bag. The results matched well with those reported for postmortem eyes [24, 25]. The capsular bag diameter (CBD) was shown to significantly correlate with axial length (AL) and keratometry (K). The predictive formula derived from a multivariate regression analysis was $CBD = 7.227 + AL \times 0.139 - K \times 0.002$.

The findings underline that the total diameter of many of currently marketed IOL styles is too large for the human capsular bag and will inevitably create stretch folds and ovalization of the capsular bag. As a result, variability and asymmetry of the shrinking process increases, compromising capsular bending and sealing at the optic rim along the IOL axis.

3.2.4.2 Quantification of Bag Diameter Changes During Capsular Shrinkage

The eyelet distance was followed up thereafter. Shrinkage started at 1 week and continued through the first 3 months. With the smaller Morcher Type 14 CTR (diameter 10 mm) mean decrease of capsular bag circumference at 1 week, 1 month, and 3 months was -0.21 , -0.72 , and -1.34 mm, respectively. With the larger Type 14A CTR (11.2 mm), the respective decreases were -0.05 , -0.45 , and -0.31 mm. Compared to the capsular bag circumference itself, this amounts to a negligible overall shrinkage of 4.1 and 0.9%, respectively. Capsular bag contraction was accompanied by a decrease in the anterior chamber depth and iris-optic distance [22].

Later on, H.R Koch designed a capsular measuring ring made of soft PMMA armed with radially orientated indicators at both ends (CMR12; HumanOptics, Erlangen, Germany) which allows for precise measurement of the capsular diameter even with a smaller pupil. The low resilience minimizes the influence of the CTR on the capsular bag size and on the postoperative contraction. With this device, the postoperative capsular bag contraction during the first 3 months was found to amount to 14.8% [23]. The mean capsular bag size was 10.53 intraoperatively, 10.31 mm at 1 day, 9.62 mm at 1 month, and 9.07 mm at 3 months. Thereafter, no further capsular shrinkage occurred.

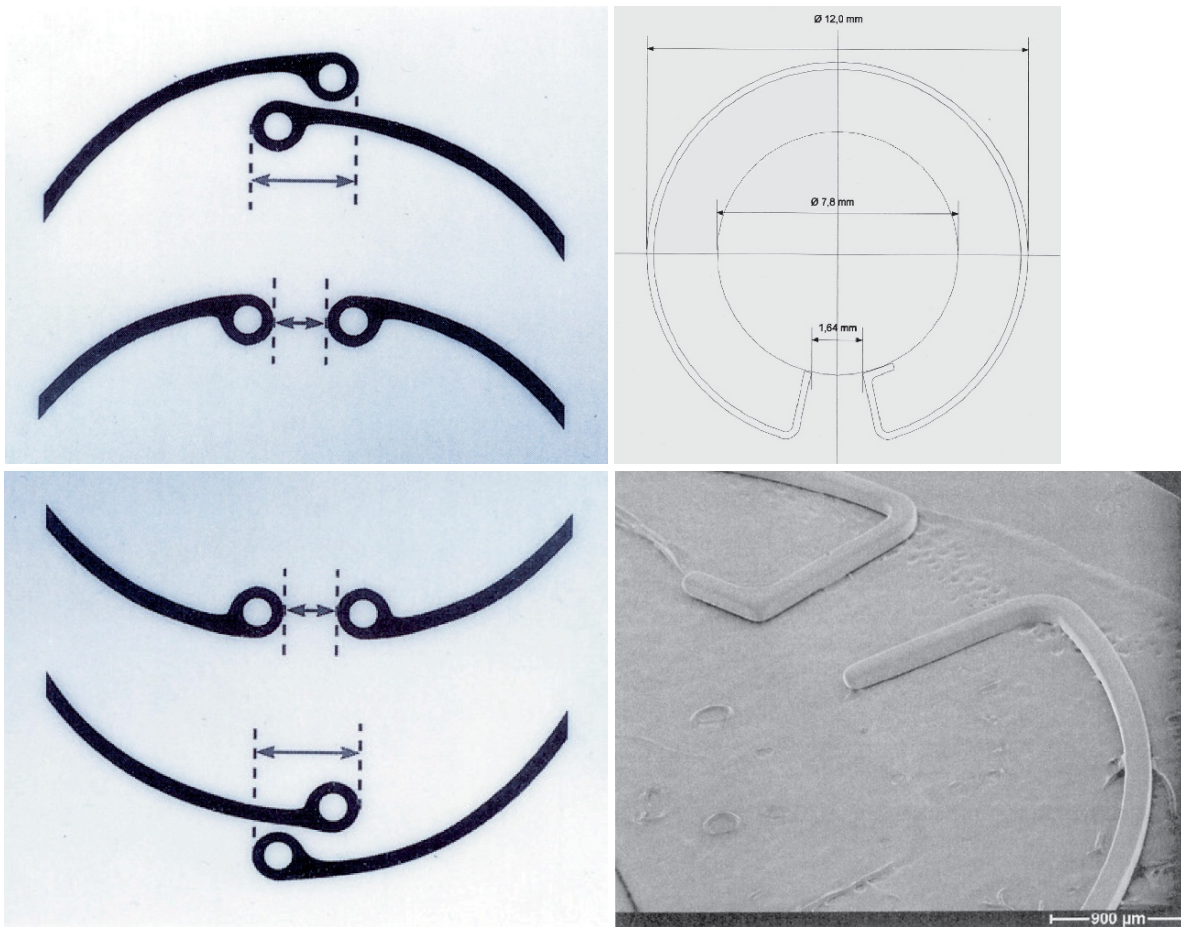


Fig. 3.5 Methods to determine capsular bag diameter and shrinkage. *Left:* Method by R. Menapace using gonioscopic measurement of eyelet distance of standard CTR with slit-beam [22]. *Right:* Method by H.R. Koch using a special measuring CTR with radial indicators which allow for direct read-off of distance (Courtesy by M. Tehrani, [23])

Summary for the Clinician

- CTRs may be used to measure the size of the capsular bag and its shrinkage postoperatively
- The mean capsular diameter as measured with a soft capsular measuring ring was 10.3 mm at day 1, and 9.1 mm after 3 months, with no shrinkage observed thereafter.
- Measurements with different CTRs styles indicate significant equatorial stretchability of the capsular bag and dependency of postoperative shrinkage upon CTR resilience

3.2.5 CTRs and After-Cataract Formation

CTR has been attributed to reduce regenerative after-cataract formation. Theoretically, this might be effected by two mechanisms. (1) The LEC migration-inhibiting

effect of the optic rim is based on the formation of a capsular bend at the posterior optic edge. Capsular bending is impeded by ovalization of the capsular bag and the longitudinal stress folds created by the IOL haptics as particularly evident in pediatric eyes [6]. Both are avoided by implantation of a CTR. (2) By equally putting the posterior capsule on stretch, the posterior capsule is approximated to the optic, which has been shown to reduce the width of the optic–capsule interspace as measured by laser interferometry [9] (Fig. 3.6: laser interferometry). The morphology of proliferating LECs depends on the width of the retro-optical space [26]. With a narrow space, they will only form out optically homogeneous syncytiae or honeycomb structures which do not or only hardly interfere with vision ('small space – no pearls'). Only a wider space will allow the LECs to grow into vision-compromising pearls. A study of my own investigated the presence and width of the retro-optical interspace with various IOLs and the influence of a CTR on it using high-intensity

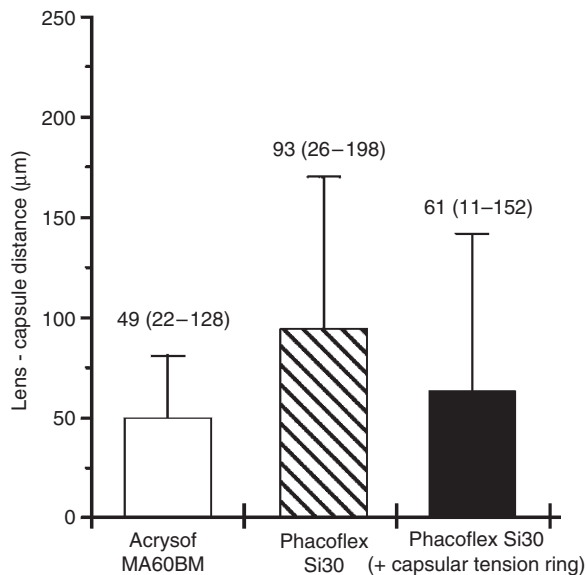


Fig. 3.6 A CTR may reduce the distance between optic and posterior capsule, thereby counteracting vision-impairing pearl formation

slit-beam judgment and laser interferometry. There was no difference between the IOLs alone both with regard to the frequency and width of the interspace. In the presence of a CTR, however, an interspace was less commonly found, and, if present, it was smaller than without a CTR. With a three-piece silicone IOL, a positive optic–capsule distance was detected in 35% of eyes without a CTR, as opposed to only 15% with a CTR. The presence of a CTR reduced the mean distance by one-third from 93 to 61µ [9]. Therefore, LECs will have less chance to access the retrolental space or form vision-impairing pearls when having overcome the barrier of the optic rim (‘small space - no pearls’). (3) The valleys in the stretch folds induced by overly long and rigid haptics are gateways for migrating LECs allowing them to easily access the retrolental area and form out pearls. This is especially true for small capsular bags and weak zonules. A CTR effectively counteracts the formation of such folds and should therefore reduce retrolental regenerative after-cataract formation.

Literature on the clinical effect of a CTR on after-cataract formation is scarce. The two publications in the peer-reviewed literature are retrospective interindividual comparison studies. A study by D’Eliseo et al. compared the 1-year results of 65 pseudoexfoliative eyes with CTR implantation and 36 control eyes. It found a moderate to severe degree of posterior capsule opacification in 36.1% of the eyes with a CTR, as opposed to only 7.7% in the non-CTR eyes [27]. In a study by Kim et al., with a

follow-up of 1–5 years (sample size 41 and 40 eyes with a mean follow-up of 3 and 2 years for the CTR and control group, respectively), eyes with a CTR demonstrated a lower incidence of capsular opacification (7.3 as opposed to 25%), a longer duration to develop, and a reduced YAG laser energy for capsulotomy [28]. Long-term results of a prospective randomized intraindividual comparison study, however, have not yet been published.

Summary for the Clinician

- A CTR may counteract after-cataract formation by avoiding stretch folds and capsular bag ovalization, and by reducing the width of the retro-optical space
- Publications indicate a reduction of posterior capsule opacification and YAG laser capsulotomy rate; however, final clinical proof is lacking

3.2.6 The Capsular Bending Ring

The capsular bending ring (CBR) was brought up by Nishi and Menapace in 1996. It was originally designed to induce a sharp capsular bend in the capsular periphery. Thus, LEC migration should be blocked at its very origin. Since the barrier function of the optic edge is then no longer necessary, the optic rim can be designed so as to minimize edge glare and dysphotopsia. To make bending possible, the CBR was equipped with a rectangular cross-section 0.7 mm in height, and only slightly tumble-polished to preserve the sharpness of the edges. Inherently, the high profile of the CBR additionally prevents the capsular periphery from collapsing, and the anterior capsular leaf from touching down on the anterior optic surface provided the capsulorhexis opening is large. Therefore, the ring has also been termed ‘capsular distance ring’. The latter inherently counteracts fibrosis since the anterior LECs do not undergo myofibroblastic transdifferentiation with consecutive contraction and collagen deposition unless when in direct contact with the optic or the posterior capsule.

In two separate studies conducted by the inventors, the after-cataract preventive effect of the CBR Type 1E manufactured by Morcher (Fig. 3.1g) was investigated. In both studies, a significant reduction of both the regenerative and fibrotic component of after-cataract was found. Figure 3.7 details the 2-year posterior capsule opacification (PCO) score and visual acuity results of the prospective randomized intraindividual comparison study conducted in Vienna: Objective PCO score and

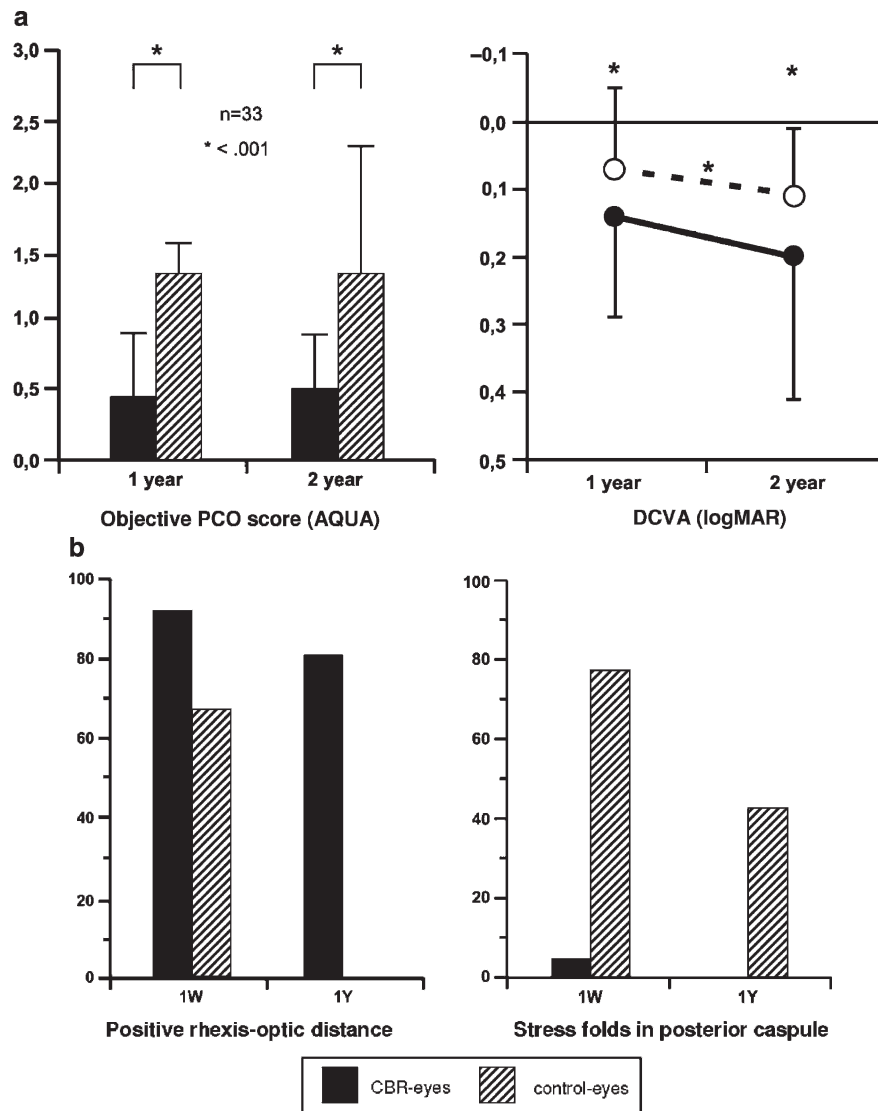


Fig. 3.7 (a) CBR significantly reduces PCO formation after 1 and 2 years, and improves visual acuity (intraindividual comparison) (b) CBR also significantly reduces fibrosis by withholding rhexis-optic contact ('capsular distance ring') and abolishes stress fold formation in the posterior capsule

best corrected distance visual acuity were significantly better with a CBR (Fig. 3.7a). Rhexis-optic contact and capsular stress folds, already significantly reduced at 1 week, were completely lacking by 1 year (Fig. 3.7b). Figure 3.8 exemplifies the impact of a CBR on fibrotic anterior capsule whitening and shrinkage, on stress fold formation in the posterior capsule, and on regenerative PCO. Accordingly, anterior capsule fibrosis was also significantly lower. A detailed workup of the 3-year results confirmed the sustained efficacy and safety of additional CBR implantation [29].

In order to avoid fibrotic shrinkage of the capsular bag, additional anterior capsule polishing is recommended. This is best performed with the CBR already implanted. Other than with an IOL optic alone [26], the barrier effect of a CBR will not be compromised by polishing, since it is not dependent upon the fibrotic sealing of both capsular leaves along the optic rim [29].

CBR implantation is especially useful with peripheral retinal diseases (enhanced peripheral visibility) and uveitis (lack of epithelial cell ongrowth from rhexis unto optic).

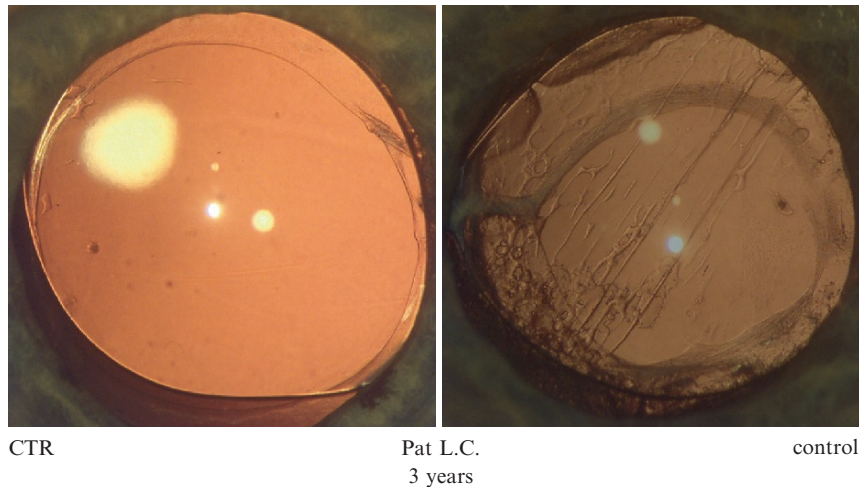


Fig. 3.8 Eyes of same patient elucidating impact of CBR on fibrotic whitening and shrinkage of anterior, and stress folds and opacification of posterior capsule

Summary for the Clinician

- The capsular bending ring (CBR) features a rectangular profile with sharp edges
- By inducing the capsular at the equator, a barrier is erected at the very origin of LEC migration
- Significant reduction of posterior capsule opacification has been demonstrated over 3 years
- Since the CBR also serves as a capsular distance ring, it avoids fibrosis with consecutive whitening and contraction of the anterior capsule leaf

3.2.7 Full-Circle Capsular Bending Rings

3.2.7.1 'Tailed' Capsular Bending Ring

The CBR significantly reduces both fibrotic and regenerative after-cataract. However, due to the variations in capsular bag size, a gap may be left between the ring ends. This results in incomplete circumferential bending, opening up a gateway for equatorial LEC immigration (Fig. 3.9-left). In order to provide circumferential bending with any capsular bag size, the original CBR Type 1E was modified in that one of the eyelets was omitted and the end elongated. This 'tailed' CBR was termed type 1F (Fig. 3.1h). By doing so, the tailed end overlaps the eyelet-armed end in any case, and thereby excludes gaping (Fig. 3.9-right). The tailed end carries a hole that takes up the hook of the inserter plunger. For loading, the plunger pulls the ring into the injector tube until only

the eyelet is exposed (Fig. 3.10). The eyelet-armed end of the CBR features an increasing radius of curvature for two purposes: First, zonulo-capsular stress and the risk of capsular entanglement during injection into the capsular bag are significantly reduced. Second, the eyelet can be easily visualized and engaged by a lens rotator to be pulled centrally and then gently laid back upon the tailed end, thereby securing adequate overlap. Thus, this design provides both circumferential bending and adaptation to any given capsular bag size and shrinkage.

3.2.7.2 Foldable Closed Ring

As an alternative, a closed CBR was designed by Dick which would inherently avoid gaping. In order to allow insertion through a small incision, the ring was made foldable. To achieve this, the ring was composed of 16 segments that are alternately made of rigid methyl methacrylate (MMA) and flexible 2-hydroxyethyl methacrylate (HEMA) linked to each other by copolymerization. The central section of the segments narrows in the middle to enhance stiffness of the ring and flexibility of the HEMA elements. External ring diameter is 10.2 mm. The rigid MMA elements are somewhat shorter, the flexible elements somewhat longer than 2 mm. The segments have a rectangular cross-section with a height of 0.8 mm and a thickness varying between 0.2–0.3 (center of MMA/HEMA segments) and 0.5 mm (junctions). The edges are sharp to induce maximum capsular bending (Fig. 3.1i).

A study was conducted to establish whether the ring will adapt to any given capsular bag diameter and resist

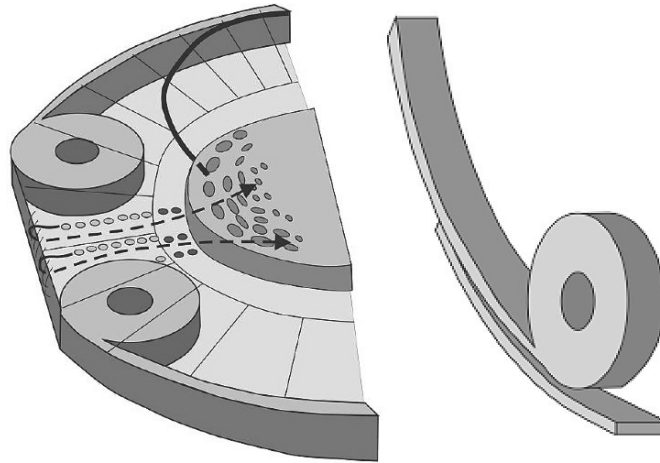


Fig. 3.9 *Left:* Eyelets of standard CBR (Type 1E) may gape when implanted in large capsular bag which opens up gateway for LEC immigration. *Right:* 'Tailed' CBR (Type 1F) secures circumferential bending with any capsular bag size

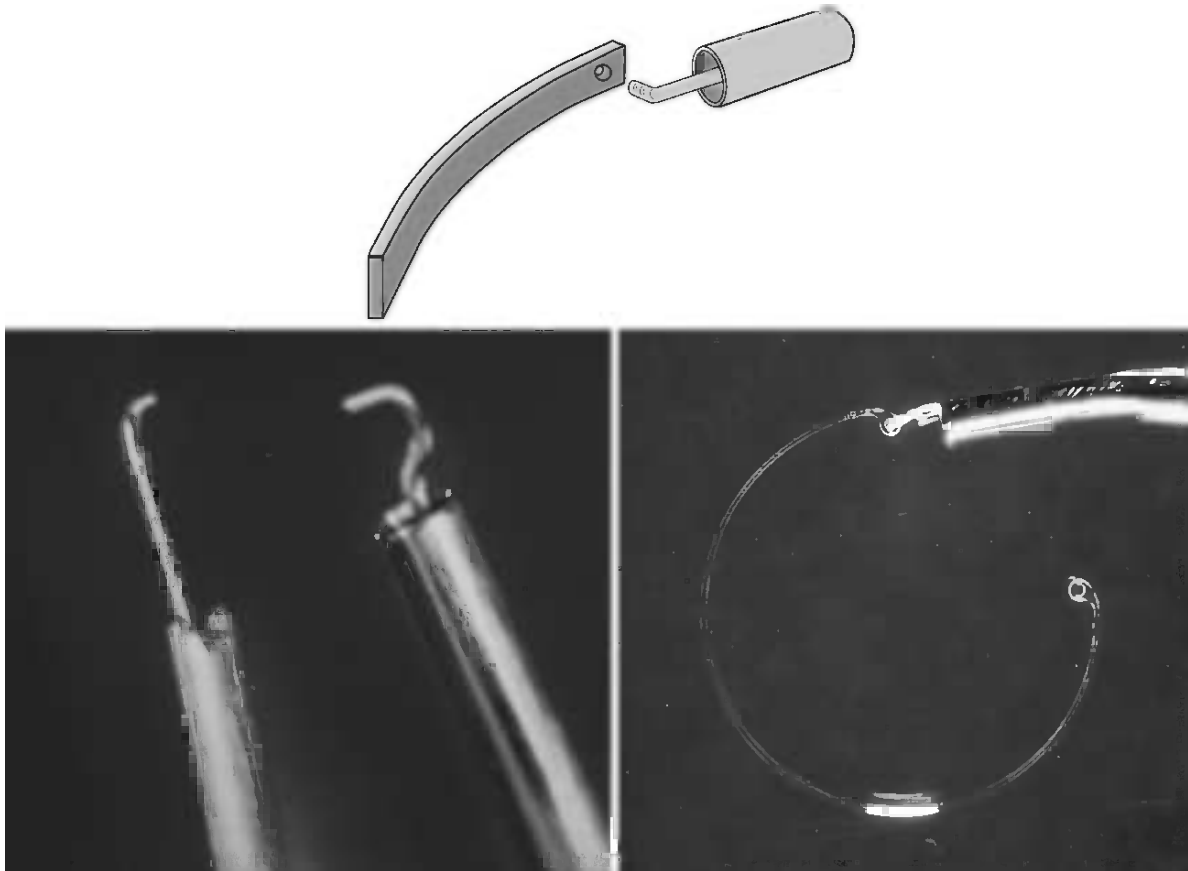


Fig. 3.10 Modified instrument allowing for one-handed single-movement injection of tailed CBR into the bag

capsular shrinkage [30]. To do so, a capsular measuring ring was additionally implanted and shrinkage intraindividually compared to that associated with a capsular measuring ring alone. No statistically significant difference was found between both eyes. No excessive shrinkage occurred within both groups. As the authors correctly noted, however, it remains to be established whether this closed ring will fully counterbalance the forces of capsular shrinkage in eyes prone to build up considerable shrinkage forces like those with pseudoexfoliation syndrome. These eyes have been demonstrated to occasionally exhibit excessive capsular shrinkage in despite of the presence of a capsular ring [31–34]. In such a case, a closed ring will inevitably be deformed and will bow inward or out of plane as observed after suturing the eyelets of a standard CTR together [9], or with IOLs featuring a closed silicone haptic [35]. Therefore, meticulous additional anterior capsule polishing is strongly recommended in eyes selected to receive a foldable closed capsule ring to remove the anterior LEC layer which is the substrate of fibrotic capsular shrinkage [12, 13].

A recent study investigated the effect of a sharp-edged silicone CBR on after-cataract. The CBR was part of a ring haptic IOL with two or three broad junctions serving as stiffeners to reduce haptic deformation within a shrinking capsular bag. In the 20 eyes followed-up for 3 years, LEC migration unto the posterior capsule was completely blocked except in one eye where the IOL with only two junctions allowed for inward-kinking of the ring haptic. In this case, additional anterior capsule polishing may also have been efficient in avoiding haptic deformation.

Summary for the Clinician

- Tailed and foldable closed rings exclude gaping of the ring ends which otherwise opens a gateway for LEC immigration
- Tailed rings adapt to any size or shrinkage of the capsular bag
- Foldable closed rings may be bent inwards in case of excessive capsular shrinkage. Therefore, additional anterior capsule polishing is mandatory
- Bending rings integrated in a silicone IOL implant allow for exquisitely sharp edges and have been shown to completely block LEC migration over 3 years

3.3 Surgical Technique

3.3.1 Timing of Ring Insertion

Generally, a capsular ring should be implanted into the evacuated capsular bag following meticulous cleaning. Inserting the ring before phacoemulsification induces increased capsular torque [15] and impedes aspiration of cortex fibers (clothesline phenomenon). If necessary, an indented CTR may be used to facilitate cortex removal [36]. The specific insertion techniques used with zonular dehiscence or weakness have been described in Sect. 2.2.

3.3.2 Insertion Techniques and Instruments

CTRs can be inserted both bimanually, using a forceps and a Y-spatula, or with appropriate injectors. Some CTRs are delivered preloaded in a single-use injector system. Bimanual implantation minimizes capsular deformation and zonular stress and the risk of capsular entanglement as it allows for inserting and advancing the CTR at a very acute angle with regard to the capsular equator. To allow for this, the lateral aspect of cataract incision tunnel may be extended towards the direction the CTR will be inserted. Alternatively, one may insert the CTR through an oblique paracentesis. Capsular entanglement itself will be immediately obvious as it is heralded by a springy resistance. Injector implantation is more convenient for many surgeons. However, care must be taken not to induce unnecessary zonular stress. Capsular entanglement cannot be felt but is only made visible by traction folds, and the risk of unperceived equatorial perforation is higher. To minimize the risk, only the tip of the injector must be inserted into the eye and obliquely orientated for ring insertion.

With a large capsular bag and lax zonular apparatus, or with large and/or rigid capsular rings (e.g., Morcher CTR Type 14A or CBR Type 14E) the leading end of a ring may be more easily caught up in the capsular bag equator. If stress must be minimized as in the case of a weak zonular apparatus (e.g., pseudoexfoliation syndrome with lentodonesis) or if such entanglement happens, a lens rotation hook may be used to bend the leading end of the ring centrally. Alternatively, a 10-0 nylon suture may be threaded through the leading eyelet and both ends externalized through the cataract incision [9]. In case of capsular entanglement, which most likely occurs opposite to the cataract incision, the eyelet can be freed and visualized by gently pulling on the U-suture. Decreasing the radius of curvature of the ring end to be inserted first [e.g., Morcher CTR Type 13 (Fig. 3.1c) or CBR Type 1F

(Fig. 3.1h)] or both (e.g., Ophtec) also avoids equatorial stress and entanglement. Generously expanding the capsular equator with a high-viscosity OVD (e.g., Healon GV) is also recommended in these cases.

A small anterior capsulorhexis increases zonular traction as its rim is dragged along at the crossover point. Supporting the ring with a Y-spatula proximal to the rhexis edge crossover reduces the traction and at the same time avoids inadvertent slippage of the ring into the sulcus.

Very flexible CTRs may be inserted folded by compressing them symmetrically until the trailing loops overlap, the CTR thus assuming a fish-like configuration. The apex or mouth of the fish is inserted through the incision into the capsular bag, and the remaining arms of the CTR are then placed in the bag with two forceps [37]. This technique minimizes tangential and shearing forces on the capsule, but requires an adequately large capsulorhexis opening.

3.3.3 Sizing of the Capsulorhexis

With a CTR, the anterior capsulorhexis should be dimensioned not smaller as necessary to provide a 0.25–0.5 mm circumferential overlap of the optic necessary to induce capsular bend formation at the posterior optic edge. With a CBR, the anterior capsulorhexis should be made as large as possible since, by principle, capsular bending is no longer effected at the optic edge due to the capsular distance effect, and since this avoids rhexis contact with the optic and thus fibrosis.

Summary for the Clinician

- Generally, a capsular ring should be implanted into the evacuated capsular bag following thorough cortex fibre aspiration
- Though use of an injector is more convenient, bimanual implantation minimizes capsular deformation and zonular stress and the risk of capsular entanglement
- Zonular stress can be reduced and capsular entanglement reversed by using a CBR with an inward-bent tip, or by pulling the tip inwards with a hook or an anchor-suture threaded through the leading eyelet before insertion
- The fish-tail insertion technique avoids the risk of entanglement, but requires a large capsulorhexis
- The anterior capsulorhexis with a CTR should be sized so as to only barely overlap the optic, while it should be made as large as possible with a CBR

3.4 Complications, Prophylaxis and Management

3.4.1 Intraoperative Complications

Intraoperatively, the ring may erroneously be inserted directly into the sulcus or secondarily flip over the rhexis edge into the sulcus when inserted bimanually. The latter can be safely avoided by supporting the ring with a Y-spatula positioned proximal to the rhexis edge crossover. If misplacement happens, the ring must be retrieved with a blunt hook (e.g., push-pull or lens manipulator) to be either relocated directly into the capsular bag or into the anterior chamber first from where it is either removed from the eye or maneuvered into the bag. Care must be taken not to engage the capsule with the tip of the hook which otherwise may result in capsular tearing or zonular desinsertion. If unclear during surgery, positioning of the CTR can be ascertained postoperatively using high-resolution ultrasonography [38]. Capsular rings have not been described to cause complications when left in the sulcus, but may cause chronic pressure rise and mild iritis when left in the chamber angle [39].

Intravitreal misplacement of a CTR may cause retinal tears and chronic cystoid macular oedema [40]. If capsular tearing occurs during implantation, the ring must be retracted and an adequate IOL fixated in the sulcus. Unnoticed equatorial perforation of the capsular bag has also been reported [41]. According to an auditorium poll at the 2002 European Vitreoretinal Society meeting in Greece, the incidence of intravitreal CTR misplacement is generally underestimated. Such rings may then be extracted through a pars plana sclerotomy. Following thorough vitrectomy, the CTR may either be removed with an injector by inserting the plunger hook into an eyelet and retracting the ring into the injector tube [42], or manually by cutting the ring in its middle with scissors and pulling the two halves out separately by using one hand to straighten and the other hand to extract the bent rigid segments [43].

3.4.2 Postoperative Complications

3.4.2.1 Capsular Contraction

Postoperatively, excessive fibrotic shrinkage of the capsulorhexis opening ('capsular contraction syndrome' [44], 'capsulorhexis phimosis') may occur. This is typically associated with pseudoexfoliation syndrome and causes elongation with consecutive weakening and atrophy of the zonular fibers. Shrinkage may be reduced by making the capsulorhexis large enough, or additionally polishing the anterior capsule leaf, or by implanting two CTRs.

3.4.2.2 (Sub-) Luxation of CTR-IOL-Bag Complex

Apart from pseudoexfoliation [45, 46], retinitis pigmentosa, status after vitrectomy [47], and long axial length [48] constitute the major predisposing factors for spontaneous capsular bag dislocation [49]. A possible influence of a CTR on the progression of zonular degradation is not established. Mean delay between surgery and dislocation was 7 years (range 57–115 months) without CTR implantation, while in two reports of late dislocation after additional CTR implantation it was also 6 and 7 years, respectively [50, 51]. Making a large anterior capsulorhexis with only a slight optic overlap is essential in reducing the risk for subsequent fibrotic contraction. Silicone IOLs should be avoided with pseudoexfoliation as they induce more fibrosis than acrylic IOLs. Since it is a progressive disease, delayed spontaneous subluxation or luxation of the whole capsular complex into the vitreous cavity is an inherent potential risk of any eye with pseudoexfoliation syndrome. Therefore, securing the bag with two Cionni rings during cataract surgery may be advisable in the presence of significant phacodonesis. If decentration of a CTR-IOL-bag complex sets in, early reintervention is strongly recommended to avoid subsequent dislocation of the complex into the vitreous. Two surgical options are available. (1) A 30-gauge hypodermic needle is inserted ab externo through the ciliary sulcus bevel-up and the tip guided behind the diaphragm until it becomes visible just inside the CTR. A 10-0 prolene suture armed with a straight needle is inserted through a paracentesis on the opposite side and advanced in front of the diaphragm to perforate the capsular periphery and be fed into the bevel of the needle, which is then externalized by pulling the hypodermic needle back and out of the globe. Then, the procedure is repeated, this time laterally offsetting the site of ab externo sulcus perforation and positioning the tip of the hypodermic needle in front of the diaphragm. After adjusting suture tension, the suture ends are knotted and the knot is buried [52]. A modified procedure has been described in which the capsule diaphragm is perforated by the 30-gauge hypodermic needle from beneath to be then fed with the straight needle inserted through a paracentesis 180° away [53]. (2) If reopening of the fused capsular leaves is feasible, the diaphragm may be stabilized by capsular tension segments sutured into sulcus [54]. If the capsular complex is completely luxated into the vitreous cavity, it must be retrieved after vitrectomy using vitreous forceps and then preferably removed out of the eye to be replaced by a sulcus-sutured or an iris-fixated IOL. In addition to the use of heavy liquids, scleral indentation [55], or vitrector aspiration [56] may be necessary to tilt the complex into a position where it can be grasped with forceps. With a foldable lens, the whole complex can

be folded inside the eye, after orienting the eyelets opposite to the incision and bisecting the ring, and removed from the eye through a 3.5- to 4.0-mm incision. Alternatively, refixation of the complex with sutures in the sulcus after floating the complex up to the retro-pupillary plane with a heavy liquid may be considered when the IOL features a large nonfoldable optic, and provided the capsular bag is not shrunken. A third suture may be necessary to correct for tilting [57].

In summary, the CTR is extremely useful and versatile surgical instrument which, in its many modifications, has helped prevent or solve many surgical problems and complications. If there were no cost restraints, routine implantation of a CTR would be advisable in almost any cataract case.

Summary for the Clinician

- Erroneous misplacement must prompt immediate CTR removal. When in the anterior chamber or vitreous cavity, chronic hypertension and inflammation, or retinal tears and macular edema may ensue.
- Excessive capsular bag shrinkage has been observed even with a CTR in place. Pseudoexfoliation syndrome is a major risk factor. Making the anterior capsulorhexis wide enough, avoiding silicone IOLs, and inserting an additional CTR are preventive measures.
- Delayed (sub-) luxation of the whole CTR-IOL-bag complex may occur. Prophylactic primary use of two suture-fixated Cionni rings is recommended with severe phacodonesis. Imminent dislocation should prompt early intervention. A dislocated complex may be repositioned either by direct sulcus suturing or after engaging the reopened capsular fornix with capsular tension segments.

References

1. Hara T, Hara T, Yamada Y (1991) "Equator ring" for maintenance of the completely circular contour of the capsular bag equator after cataract removal. *Ophthalmic Surgeon* 22:358–359
2. Nagamoto T. Origin of the capsular tension ring (2001) *J Cataract Refract Surg* 27:1710–1711
3. Nagamoto T, Bissen-Miyajima H (1994) A ring to support the capsular bag after continuous curvilinear capsulorhexis. *J Cataract Refract Surg* 20:417–420
4. Kurz S, Dick HB (2004) Spring constants of capsular tension rings. *J Cataract Refract Surg* 30:1993–1997

5. Lee DH, Shin SC, Joo CK (2002) Effect of a capsular tension ring on intraocular lens decentration and tilting after cataract surgery. *J Cataract Refract Surg* 28:843–846
6. Pandey SK, Werner L, Wilson ME Jr, Izak AM, Apple DJ (2004) Capsulorhexis ovaling and capsular bag stretch after rigid and foldable intraocular lens implantation: experimental study in pediatric human eyes. *J Cataract Refract Surg* 30:2183–2191
7. Boomer JA, Jackson DW (2006) Effect of the Morcher capsular tension ring on refractive outcome. *J Cataract Refract Surg*. 32:1180–1183
8. Sun R, Gimbel HV (1998) In vitro evaluation of the efficacy of the capsular tension ring for managing zonular dialysis in cataract surgery. *Ophthalmic Surg Lasers* 29:502–505
9. Menapace R, Findl O, Georgopoulos M, Rainer G, Vass C, Schmetterer K (2000) The capsular tension ring: designs, applications, and techniques. *J Cataract Refract Surg* 26:898–912
10. Ahmed II, Cionni RJ, Kranemann C, Crandall AS (2005) Optimal timing of capsular tension ring implantation: Miyake-Apple video analysis. *J Cataract Refract Surg* 31:1809–1813
11. Joo CK, Shin JA, Kim JH (1996) Capsular opening contraction after continuous curvilinear capsulorhexis and intraocular lens implantation. *J Cataract Refract Surg* 22:585–590
12. Menapace R, Di Nardo S (2006) Aspiration curette for anterior capsule polishing: laboratory and clinical evaluation. *J Cataract Refract Surg* 32:1997–2003
13. Sacu S, Menapace R, Wirtitsch M, Buehl W, Rainer G, Findl O (2004) Effect of anterior capsule polishing on fibrotic capsule opacification: three-year results. *J Cataract Refract Surg* 30:2322–2327
14. Liu CS, Eleftheriadis H. Multiple capsular tension rings for the prevention of capsular contraction syndrome (2001) *J Cataract Refract Surg* 27:342–343
15. Cionni RJ, Osher RH, Marques DM, Marques FF, Snyder ME, Shapiro S (2003) Modified capsular tension ring for patients with congenital loss of zonular support. *J Cataract Refract Surg* 29:1668–1673
16. Georgopoulos M, Menapace R, Findl O, Petternel V, Kiss B, Rainer G (2003) After-cataract in adults with primary posterior capsulorhexis: comparison of hydrogel and silicone intraocular lenses with round edges after 2 years. *J Cataract Refract Surg* 29:955–960
17. Menapace R (2006) Routine posterior optic buttonholing for eradication of posterior capsule opacification in adults: report of 500 consecutive cases. *J Cataract Refract Surg* 32:929–943
18. Menapace R (2008) Posterior capsulorhexis combined with optic buttonholing: an alternative to standard in-the-bag implantation of sharp-edged intraocular lenses? A critical analysis of 1000 consecutive cases. *Graefes Archives Clin Experiment Ophthalmol* (in press). Review
19. Menapace R, Zehetmayer M (1995) Einsatz des Kapselspannrings im Rahmen von Phakoemulsifikation und Linsenimplantation nach durchgreifender Resektion eines Ziliarkörpertumors. *Proceedings 9. Kongress der Deutschsprachigen Gesellschaft für Intraokularlinsenimplantation und refraktive Chirurgie*, Kiel. Springer, Berlin Heidelberg New York, pp 123–130
20. Bahar I, Kaiserman I, Rootman D (2007) Cionni endocapsular ring implantation in Marfan's syndrome. *Br J Ophthalmol* 91:1477–1480
21. Moreno-Montañés J, Sainz C, Maldonado MJ (2003) Intraoperative and postoperative complications of Cionni endocapsular ring implantation. *J Cataract Refract Surg* 29:492–497
22. Strenn K, Menapace R, Vass C (1997) Capsular bag shrinkage after implantation of an open-loop silicone lens and a poly (methyl methacrylate) capsular tension ring. *J Cataract Refract Surg* 23:1543–1547
23. Tehrani M, Dick HB, Krummenauer F, Pfirrmann G, Boyle T, Stoffelns BM (2003) Capsule measuring ring to predict capsular bag diameter and follow its course after foldable intraocular lens implantation. *J Cataract Refract Surg* 29:2127–2134
24. Galand A, Bonhomme L, Collée M (1984) Direct measurement of the capsular bag. *J Am Intraocul Implant Soc* 10:475–476
25. Richburg FA, Sun HS (1983) Size of the crushed cataractous capsule bag. *J A Intraocul Implant Soc* 19:333–335
26. Menapace R (2004) Prevention of posterior capsule opacification. In: *Cataract and refractive surgery, Essentials in ophthalmology*. Springer, Berlin Heidelberg, pp 101–122
27. D'Eliseo D, Pastena B, Longanesi L, Grisanti F, Negrini V (2003) Prevention of posterior capsule opacification using capsular tension ring for zonular defects in cataract surgery. *Eur J Ophthalmol* 13:151–154
28. Kim JH, Kim H, Joo CK (2005) The effect of capsular tension ring on posterior capsular opacity in cataract surgery. *Korean J Ophthalmol* 19:23–28
29. Menapace R, Sacu S, Georgopoulos M, Findl O, Rainer G, Nishi O (2008) Efficacy and safety of capsular bending ring implantation for after-cataract prevention: 3-year results of a randomized clinical trial. *J Cataract Refract Surg*
30. Kurz S, Krummenauer F, Dumbach C, Pfeiffer N, Dick B (2006) Effect of a closed capsular ring on capsular bag shrinkage in cataract surgery. *J Cataract Refract Surg* 32:1615–1620
31. Faschinger CW, Eckhardt M (1999) Complete capsulorhexis opening occlusion despite capsular tension ring implantation. *J Cataract Refract Surg* 25:1013–1015

32. Moreno-Montañés J, Sánchez-Tocino H, Rodríguez-Conde R (2002) Complete anterior capsule contraction after phacoemulsification with acrylic intraocular lens and endocapsular ring implantation. *J Cataract Refract Surg* 228:717–719
33. Sudhir RR, Rao SK (2001) Capsulorhexis phimosis in retinitis pigmentosa despite capsular tension ring implantation. *J Cataract Refract Surg* 27:1691–1694
34. Waheed K, Eleftheriadis H, Liu C (2001) Anterior capsular phimosis in eyes with a capsular tension ring. *J Cataract Refract Surg* 27:1688–1690
35. Bühl W, Menapace R, Georgopoulos M, Leydolt C, Kriechbaum K, Findl O. Effect of two different ring haptic silicone IOL designs on posterior capsule opacification. Abstract XXV Congress of the European Society of Cataract and Refractive Surgeons (ESCRS), Stockholm, 8–12 September 2007
36. Henderson BA, Kim JY (2007) Modified capsular tension ring for cortical removal after implantation. *J Cataract Refract Surg* 33:1688–1690
37. Angunawela RI, Little B (2007) Fish-tail technique for capsular tension ring insertion. *J Cataract Refract Surg* 33:767–769 Comment in: *J Cataract Refract Surg* 2007;33:1840
38. Boomer JA, Jackson DW (2006) Anatomic evaluation of the Morcher capsular tension ring by ultrasound biomicroscopy. *J Cataract Refract Surg* 32:846–848
39. Little BC, Richardson T, Morris S (2004) Removal of a capsular tension ring from the anterior chamber angle. *J Cataract Refract Surg* 30:1832–1834
40. Levy J, Klempner I, Lifshitz T (2005) Posteriorly dislocated capsular tension ring. *Ophthalmic Surg Lasers Imaging* 36:416–418
41. Bopp S, Lucke K (2003) Chronic cystoid macular edema in an eye with a capsule defect and posteriorly dislocated capsular tension ring. *J Cataract Refract Surg* 29:603–608
42. Ma PE, Kaur H, Petrovic V, Hay D (2003) Technique for removal of a capsular tension ring from the vitreous. *Ophthalmology* 110:1142–1144
43. Bopp S, Lucke K (2004) Removal of a capsular tension ring. *Ophthalmology* 111:196–197
44. Davison JA (1993) Capsule contraction syndrome. *J Cataract Refract Surg* 19:582–589
45. Freissler K, Küchle M, Naumann GO (1995) Spontaneous dislocation of the lens in pseudoexfoliation syndrome. *Arch Ophthalmol* 113:1095–1096
46. Jehan FS, Mamalis N, Crandall AS (2001) Spontaneous late dislocation of intraocular lens within the capsular bag in pseudoexfoliation patients. *Ophthalmology* 108:1727–1731 Comment in: *Ophthalmology* 2002;109:1951–1952
47. Yasuda A, Ohkoshi K, Orihara Y, Kusano Y, Sakuma A, Yamaguchi T (2000) Spontaneous luxation of encapsulated intraocular lens onto the retina after a triple procedure of vitrectomy, phacoemulsification, and intraocular lens implantation. *Am J Ophthalmol* 130:836–837
48. Zech JC, Tanniére P, Denis P, Trepsat C (1999) Posterior chamber intraocular lens dislocation with the bag. *J Cataract Refract Surg* 25:1168–1169. Comment in: *J Cataract Refract Surg* 2000; 26:476–477
49. Hayashi K, Hirata A, Hayashi H (2007) Possible predisposing factors for in-the-bag and out-of-the-bag intraocular lens dislocation and outcomes of intraocular lens exchange surgery. *Ophthalmology* 114:969–975
50. Oner FH, Kocak N, Saatci AO (2006) Dislocation of capsular bag with intraocular lens and capsular tension ring. *J Cataract Refract Surg* 32:1756–1758
51. Scherer M, Bertelmann E, Rieck P (2007) Late spontaneous in-the-bag intraocular lens and capsular tension ring dislocation in pseudoexfoliation syndrome. *J Cataract Refract Surg* 32:672–675. Comment in: *J Cataract Refract Surg* 2007;33:176; author reply 176
52. Moreno-Montañés J, Heras H, Fernández-Hortelano A (2005) Surgical treatment of a dislocated intraocular lens-capsular bag-capsular tension ring complex. *J Cataract Refract Surg* 31:270–273
53. Moreno-Montañés J, Heras H, Fernández-Hortelano A (2006) Dislocated capsular tension ring. *Ophthalmology* 113:2114–2115
54. Ahmed II, Chen SH, Kranemann C, Wong DT (2005) Surgical repositioning of dislocated capsular tension rings. *Ophthalmology* 112:1725–1733; Comment in: *Ophthalmology* 2006; 113:2114–2115; author reply 2115
55. Lim MC, Jap AH, Wong EY (2006) Surgical management of late dislocated lens capsular bag with intraocular lens and endocapsular tension ring. *J Cataract Refract Surg* 32:533–535
56. Deka S, Deka A, Bhattacharjee H (2006) Management of posteriorly dislocated endocapsular tension ring and intraocular lens complex. *J Cataract Refract Surg* 32:887–889
57. Saravanan VR, Singh G, Narendran V, Sathyan P (2006) Managing the IOL-CTR-CB complex. *J Cataract Refract Surg* 32:1898–1899

Intraocular Lens Complications and Management

Diamond Y. Tam, Iqbal Ike K. Ahmed

Core Messages

- IOL subluxation may result in visual symptoms (including halos, diplopia, glare), increased refractive cylinder, increased higher order aberrations, uveitis–glaucoma–hyphema (UGH) syndrome, pigment dispersion syndrome, cystoid macular oedema, and corneal decompensation
- IOL related complications may be related to pre-existing loose zonules such as in congenital conditions, progressive conditions such as pseudoexfoliation syndrome (XFS), capsular contraction syndrome, iatrogenic intraoperative inadvertent injury, inadvertent bag/sulcus placement of an IOL, improper sizing or positioning, and trauma
- A detailed clinical examination must be performed including gonioscopy and dilated examination to ascertain the IOL position as well as its relation to other ocular comorbidities. Ancillary testing, including ultrasound biomicroscopy may be useful or required to assess the IOL position as well as to plan surgical approaches
- In planning appropriate management, the location of the IOL (i.e., in-the-bag or out-of-the-bag) should be noted, as should the IOL design
- Surgery to reposition the subluxed IOL includes capsular Fixation, scleral sutured refixation, iris sutural refixation, or explantation and replacement of a different IOL

4.1 Introduction

In 5 B.C., Sanskrit manuscripts first described couching, the procedure by which a needle is placed into the eye and an opalescent lens pushed into the vitreous cavity in order to clear the visual axis. In 1748, Jacques Daviel performed the first extracapsular cataract extraction, and then, in 1967, Charles Kelman invented what is known today as phacoemulsification, considered by many in the Western world to be the current standard for cataract surgery [1]. While cataract extraction has been performed since Daviel first introduced the procedure, the intraocular lens (IOL) did not become available until 1949, when Harold Ridley, an ophthalmologist at Moorfield's eye hospital, London, observed that two fighter pilots who had penetrating globe injuries with material from the polymethylmethacrylate (PMMA) canopies had a surprising lack of an intraocular immune response. Thus, the first IOL, made of PMMA, was implanted by Ridley in 1949. In the 1980s and 1990s, foldable IOLs became the mainstay of implants due to the smaller incisions required.

While the evolution of IOLs has brought us to modern day small incision phacoemulsification where the

vast majority of IOLs are placed in the capsular bag in the posterior chamber, decentration and dislocation of IOLs continues to be a pertinent issue with the prevalence of conditions such as pseudoexfoliation (XFS), capsular contraction syndrome, and trauma. In addition, iatrogenic zonular or capsular injury intraoperatively, inadvertent bag/sulcus haptic placement, and improper lens sizing or placement, especially for anterior chamber IOLs (ACIOL), contribute to both short- and long-term IOL decentration and dislocation.

4.2 IOL Complications

4.2.1 Presentation

Multiple studies have demonstrated that IOL dislocation or decentration occurs with an incidence rate between 0.2 and 3.0% [2, 4]. Signs and symptoms most common at the time of patient presentation include glare, halos, edge effect, reduced visual acuity, increased cylinder manifesting as a refractive shift or instability, iris chafing, uveitis–glaucoma–hyphema (UGH) syndrome, cystoid macular

oedema, and corneal decompensation [3]. Other presenting symptoms include diplopia, photosensitivity, and ghost images. Many of these symptoms may be attributed to the edge of the optic, a peripheral Sommering's ring, or capsular opacity entering the pupillary aperture.

Slit-lamp examination of the patient with an ACIOL which is dislocated may reveal a distorted or peaked pupil, anterior chamber inflammation due to iris irritation, corneal edema in an undersized ACIOL which is mobile in the anterior chamber, a haptic entering the posterior chamber through an iridectomy, vitreous present in the anterior chamber, elevated intraocular pressure (IOP), or hyphema (Figs. 4.1–4.3). In addition, cystoid macular edema may be present due to chronic inflammation. Gonioscopy is a useful adjunct in the examination of a patient with an ACIOL to determine the position of the haptics, the status of angle structures, identifying a microhyphema, or identifying iris tuck by a haptic. Furthermore, if surgical explantation is planned, gonioscopy of the ACIOL haptics to determine the

presence of peripheral anterior synechia or a fibrous cocooning of the haptic is important in planning the technique.

In the patient with a suspected dislocation of the posterior chamber IOL (PCIOL), the findings may be as subtle as a refractive shift, astigmatic correction required in a patient with no corneal cylinder, and optical aberrations. They may also be as dramatic as an entire PCIOL in the anterior chamber, a PCIOL haptic emerging through the pupil and causing corneal edema, or a completely luxated PCIOL sitting on the posterior pole. On slit-lamp examination, it is important to note the location of the design and location of the PCIOL. Helpful management classifications include 'in-the-bag' or 'out-of-the-bag' subluxations. Most in-the-bag PCIOL decentrations are typically in the retropupillary area or in the vitreous cavity (Figs. 4.4 and 4.5). Out-of-the-bag PCIOL subluxations may be wholly or partially in the anterior chamber, wholly or partially in the ciliary sulcus, or in the vitreous cavity (Figs. 4.6–4.9).

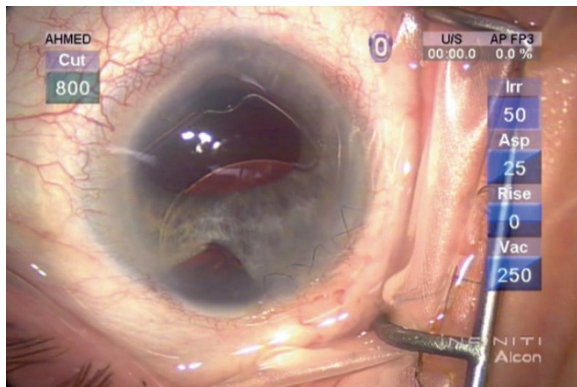


Fig. 4.1 One haptic and part of the optic of an open loop haptic ACIOL has prolapsed through a large peripheral iridectomy

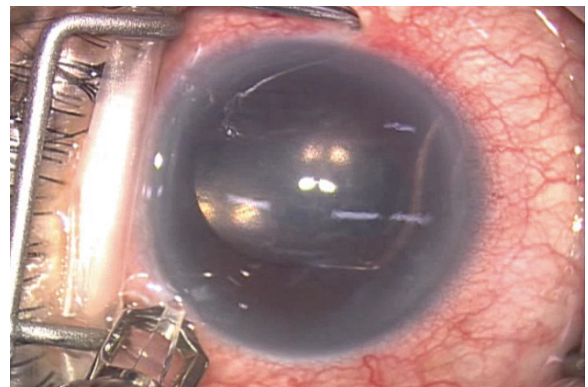


Fig. 4.3 An ACIOL of incorrect size, in this case, a nasally dislocated undersized lens, which has caused corneal endothelial trauma and resultant edema

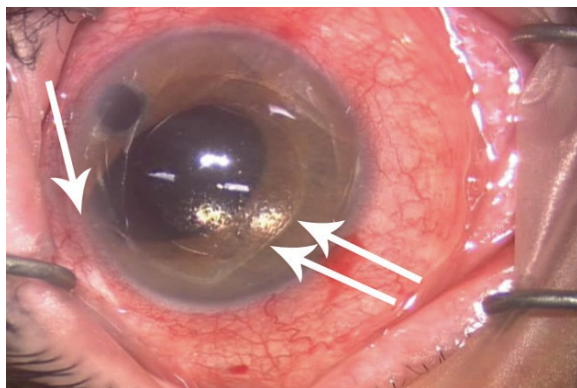


Fig. 4.2 One haptic of this ACIOL has caused iris tuck and peaking of the pupil in that direction (*single arrow*). Chronic anterior chamber inflammation has also resulted in pigmented deposits on the surface of the IOL (*double arrow*)

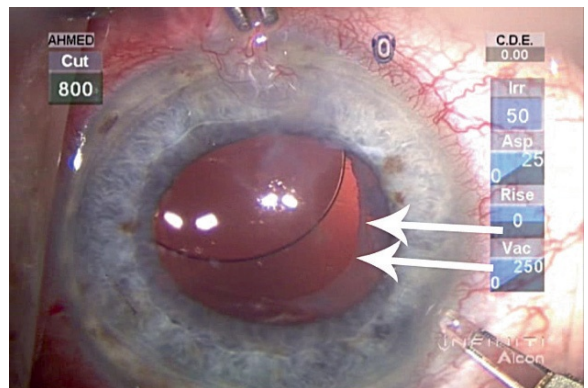


Fig. 4.4 A PCIOL located in the anterior vitreous cavity. The intact anterior capsulorhexis is shown by the *arrows*. Posterior capsule is absent in this case

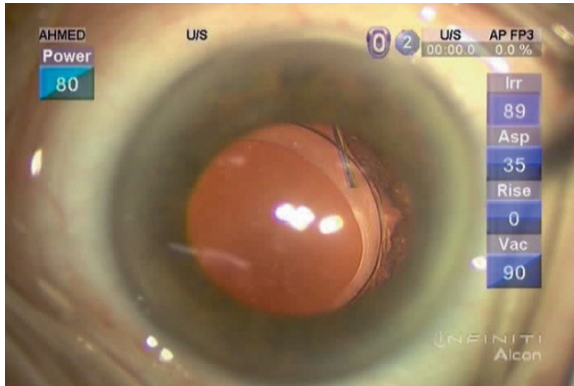


Fig. 4.5 A PCIOL located in the capsular bag, but with profound zonular weakness and absence. Note the abnormally widened sulcus space between the IOL-capsular bag complex and the iris

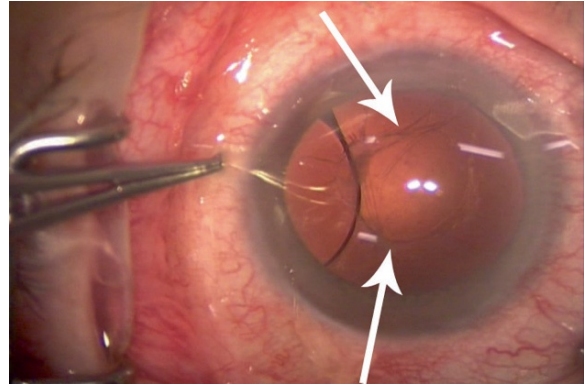


Fig. 4.8 A one piece foldable acrylic PCIOL subluxed into the anterior vitreous cavity. The intact anterior continuous curvilinear capsulorhexis is seen (arrows), but a large posterior capsular opening is present

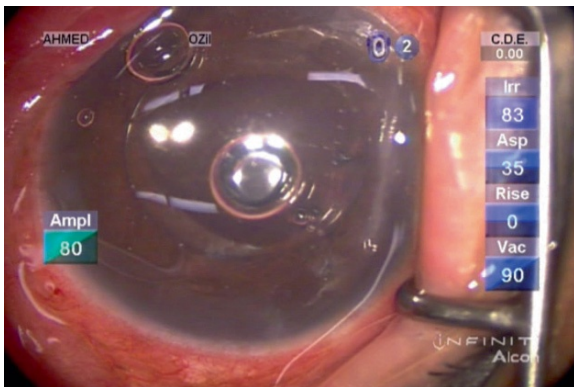


Fig. 4.6 A one piece foldable acrylic IOL, designed for endo-capsular implantation, located wholly in the anterior chamber with an irregular pupil due to vitreous prolapse into the anterior chamber in this patient

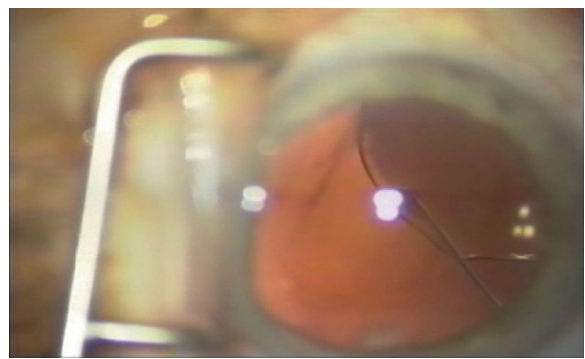


Fig. 4.9 Dislocated three-piece out-of-the-bag IOL freely mobile in the vitreous cavity

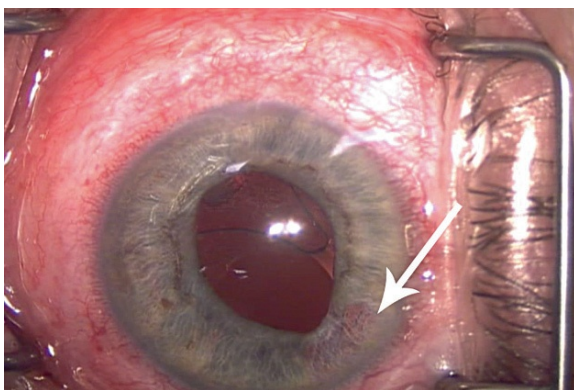


Fig. 4.7 A one piece foldable acrylic PCIOL located in the ciliary sulcus and was seen to be mobile on clinical slit lamp examination. Note the retroillumination defect on the iris due to chafing on the posterior surface of the iris by the IOL (arrow)

It is also important for the examiner to determine the suspected cause of IOL dislocation, particularly examination for clues of pseudoexfoliation syndrome (XFS). As XFS is a progressive zonulopathy, this diagnosis has implications for management and intervention. For example, a mild IOL decentration in an XFS patient is more likely to progress to subluxation or complete luxation than a similar presentation due to a one-time traumatic event, thus more likely requiring surgical intervention. Careful examination of the cornea, anterior chamber, and iris must also be undertaken in a suspected malpositioned PCIOL. Fine keratic precipitates may be visible as evidence of chronic or intermittent inflammation. The anterior chamber may reveal inflammation, a hyphema, or vitreous prolapse. Gonioscopy should also be performed to determine the status of the iridocorneal angle and the angle opening compared to the contralateral eye. Asymmetry such as by an IOL subluxed forward may indeed cause angle

closure and even peripheral anterior synechiae formation. Trabecular meshwork pigment should be assessed, as well as careful observation of the pupil margin, as these examination findings may serve to provide a clue to the diagnosis of XFS. Retroillumination of the iris is also essential to examination of the suspected malpositioned PCIOL. A retroillumination defect may be seen in the shape or outline of a haptic revealing the clock hour position of the haptic, and confirming its likely location as the ciliary sulcus (Fig. 4.10). This aspect of the examination is especially important in patients who dilate poorly with pharmacologic mydriatics, such as patients with XFS.

Following the undilated examination, pharmacological dilation should be attempted and a full dilated examination of the PCIOL should be performed. The position of the IOL should be noted and documented including whether it is completely in the capsular bag, with or without an intact posterior capsule, completely in the ciliary sulcus, in a bag-sulcus position, partially in the bag and partially in the vitreous cavity, or free floating in the vitreous cavity. Zonular integrity should be noted, visibly as any pseudophacodonesis or iridodonesis, or if pupillary dilation is good, the zonules may be directly visualized. Documentation of the type of IOL, the material, as well as the presence of any capsular tension devices is critical to surgical planning as well as the chosen modality of refixation, or to whether the decision is made to exchange the IOL for another. Not uncommonly, an IOL may be dislocated out of view even in a well-dilated pupil. In these cases, scleral depression may be required with indirect ophthalmoscopy to visualize the IOL and its extent of dislocation. The IOL may be suspended by inferior zonular attachments and thus have fallen like a 'trap door' out of view of a dilated pupil. Once the pupil is dilated, a detailed fundoscopic examination must also be performed to rule out retinal detachment, tears, cystoid macular edema,

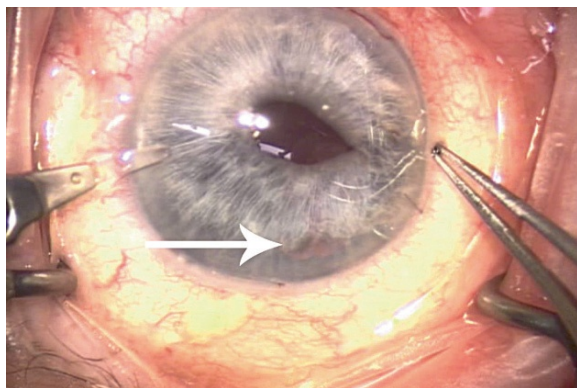


Fig. 4.10 A retroillumination defect is seen in the iris (arrow) revealing the location of the haptic of a malpositioned IOL




Fig. 4.11 An anterior segment optical coherence tomography (AS-OCT) image showing a tilted IOL in the retro-pupillary plane



Fig. 4.12 An AS-OCT image showing the square edge of an acrylic haptic impinging on peripheral iris and ciliary body

and other posterior segment pathology as well. If a retinal detachment or other posterior segment surgical disorder is present, referral to a retina surgeon may be appropriate prior to management of the IOL dislocation. Adjunctive testing, which may be useful in the assessment of a dislocated ACIOL or PCIOL, can include specular microscopy to perform an endothelial cell assessment, anterior segment optical coherence tomography (AS-OCT), and ultrasound biomicroscopy (UBM). (Figs. 4.11–4.12).

4.2.2 Causes

Before the advent of the continuous curvilinear capsulorrhexis and before in-the-bag IOL placement was the standard of care, IOL dislocations were usually outside the capsule and termed sunrise or sunset syndrome, depending on IOL location [5, 6]. Out-of-the-bag IOL dislocations are largely due to complicated surgery or decentered implantation. The sunrise syndrome typically occurs in the setting of an unrecognized placement of a superior haptic in the sulcus, where the zonules have been traumatized, and inferior haptic in the capsular bag. As the inferior capsule contracts, the IOL is forced superiorly through the already weakened or absent zonular apparatus. Sunset syndrome is a result of unrecognized inferior zonulopathy or absence and placement of an IOL in the ciliary sulcus which subsequently dislocates

inferiorly with the assistance of gravity. The term 'pea podding' refers to the situation when a bag-sulcus fixated PCIOL is completely or partially forced out of the capsular bag as a result of capsular contraction in the presence of an anterior capsular tear (Fig. 4.13–4.14).

Recently, an increase in in-the-bag IOL dislocations has been observed, typically due to XFS, uveitis, trauma, post-vitrectomy, or a long axial length [7]. Dislocations can also be categorized as being early versus late, where early dislocations may be due to insufficient support of the lens either by the capsular bag or sulcus [8], asymmetric or bag-sulcus haptic placement [2], zonular instability or rupture iatrogenically at the time of surgery [9], XFS, congenital syndromes, posterior capsule rupture, or pre-existing zonular dialysis [3]. Late dislocations, designated as

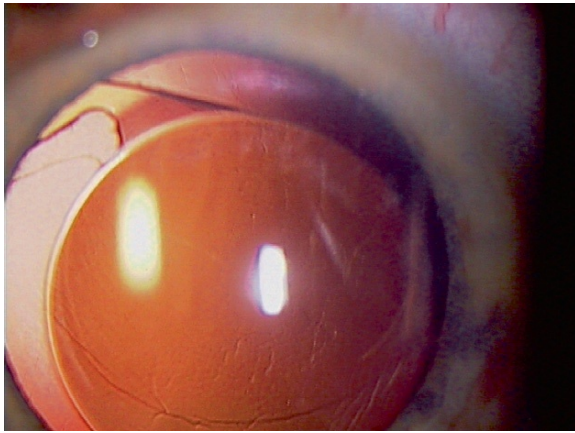


Fig. 4.13 A pea-podded IOL partially in a bag-sulcus position with the superior haptic and optic prolapsed out of the capsular bag




Fig. 4.14 Another example of an IOL which has been partially pea-podded out of the capsular bag inferiorly while still in the capsular bag superiorly. The slit beam image shows the inferior optic tilted forward

those occurring after 3 months, may be caused by progressive zonulopathy in XFS, trauma [7], or capsule contraction causing zonular rupture [10].

Although relatively uncommon in the era of small incision endocapsular surgery and IOL implantation, IOL-related complications fall into four general categories: traumatic, inflammatory, infectious, and optical [3]. Traumatic injury may be iatrogenic during cataract extraction or IOL insertion, incorrect choice of lens size resulting in lens movement postoperatively causing damage to intraocular structures, or a postoperative event. Capsular and/or zonular trauma during phacoemulsification may compromise support for an in-the-bag or sulcus supported PCIOL, thus leading to postoperative decentration. During insertion of an IOL, the capsular bag or zonular apparatus may sustain trauma preventing proper centration of the IOL and, in some cases, this results in vitreous in the anterior chamber and loss of posterior capsular support for an endocapsular IOL. Improper IOL size may manifest as corneal dysfunction or decompensation from, for example, an anterior chamber IOL that is too small and moves in the anterior chamber, or one that is too large and vaults forward towards the cornea. Chronic inflammation may be a result of iris chafing from the IOL optic or, more commonly, haptics, or an anterior chamber IOL trapping iris in the iridocorneal angle. Widely popular is the one-piece foldable acrylic IOL, but it is critical that the haptics of this lens be placed in the capsular bag or behind the anterior capsule, as its bulky and flexible haptics may cause iris chafing and even persistent hyphema or UGH syndrome when situated in the ciliary sulcus. This is an underdiagnosed cause of postoperative chronic uveitis after cataract surgery in a patient who has had no previous history of uveitis. Release of inflammatory mediators from this mechanical irritation can lead to other complications such as chronic uveitis, hyphema, cystoid macular edema (CME), or glaucoma. Infectious complications refer to endophthalmitis while optical complications may result from inaccuracies in IOL calculations or selection, or postoperative IOL malposition, tilt, decentration, dislocation, or dysphotopsia. Postoperative lens opacification/calcification may also result in the need to explant the IOL (Fig. 4.15).

4.3 Management of the Malpositioned IOL

4.3.1 General Principles

The choice of whether intervention is necessary in the case of a malpositioned IOL is governed by the symptoms of the patient. In some cases, with a slightly decentered

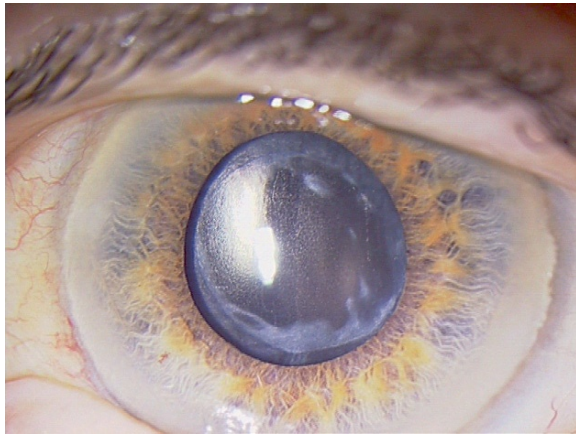

Fig. 4.15 Calcification of the optic of a Hydroview H60M IOL

IOL, observation may be appropriate if the symptoms are minimal or limited to dim light conditions whereupon the pupil is dilated and the patient has optic edge effects. In this case, medical therapy may be the first line of treatment with prescription of a miotic agent such as pilocarpine or brimonidine. The presence of an IOL which is the cause of other comorbidities in the eye such as corneal decompensation, chronic inflammation, or glaucoma must be repositioned or explanted and exchanged as observation or medical therapy may not be sufficient to control and certainly will not improve the chronic sequelae resulting from the IOL. With regards to how a surgeon decides to proceed, other factors must also be considered, including the patient's age, overall health and fitness for surgery, visual demands, and the condition of the fellow eye.

Various options exist to ameliorate the problems caused by intraocular lenses. Although uncommon, IOL explantation without intraocular lens implant is sometimes indicated, most commonly due to corneal edema precluding an adequate view of the anterior segment for safe IOL implantation. Less commonly, a highly myopic patient may be left aphakic for refractive purposes. IOL exchange has been used for replacement of ACIOLs causing intraocular inflammation or glaucoma, and of both AC and PCIOLs of incorrect power, or with opacification [3, 11]. IOL exchange has also been used in cases of IOL calcification, decentration, dislocation, dysphotopsia, and glare [12].

If an IOL needs to be repositioned, lens repositioning with or without suture fixation may be an option, depending on the type of lens which is present and the amount of capsular support and zonular integrity. ACIOL subluxations are handled somewhat differently than PCIOLs that are subluxed in that invariably most ACIOL malpositions require explantation and exchange while PCIOL subluxations may be amenable to suture refixation.

In some cases of PCIOL subluxation, capsular fixation may be achieved if adequate support exists. If suture fixation is required, iris or scleral fixation are the options and, again, the type of IOL, the degree of dislocation, and the presence of any capsular support devices in the bag factor into the decision of the most appropriate means of fixation. Lens exchange may be necessary, and if so, one can implant an IOL in the anterior chamber or posterior chamber. Open-loop ACIOLs are significantly better than the previous closed-loop design that has been associated with a high complication rate and worse BCVA [13]. Insertion of an ACIOL is the simplest surgical procedure for correction of aphakia. Disadvantages of ACIOLs include the need for accurate sizing, a surgical incision of at least 6 mm, risk of corneal decompensation in the short- and long-term, worsening of or the onset of glaucoma, and chronic inflammation, cystoid macular edema, pseudophakic pupillary block, and hyphema from angle trauma [14, 15]. Furthermore, ACIOL insertion may be traumatic with trapping of the iris by the haptics. Other anterior chamber options include the iris claw IOL (Ophtec, The Netherlands) which has the advantages over the ACIOL of not requiring sizing issues (as it is a fixed 8.5 mm in length), the IOL may be placed to be centered over the pupil, the surgeon maintains full visualization of the haptics, mydriasis and iris vasculature is unaffected, and no angle structures are contacted. This IOL has also been shown to be safe towards the corneal endothelium in the aphakic eye, or the eye with a deep anterior chamber [16, 17]. The disadvantages of this IOL are that sufficient iris tissue is required and that adjunctive pupilloplasty may be required. The options for placing an IOL in the posterior chamber include iris-suturing using a McCannel-type technique, which produces good anatomical and visual outcomes, but may cause iris erosion, neovascularization, chaffing, iridodialysis, pigment dispersion syndrome, peripheral anterior synechiae, glaucoma and haptic migration or slippage, and suture breakage [18–20]. Scleral-sutured PCIOLs, which can also produce reasonable outcomes, may be technically more demanding in that needle passages behind the iris are required that may potentially increase the risk of intraocular hemorrhage along with other risks such as suture breakage, externalized sutures, IOL tilt, and endophthalmitis [21].

4.3.2 IOL Repositioning: Surgical Principles

Once a complete examination has been performed and the decision has been made that the existing IOL will be repositioned, the surgeon must decide the means by which to fixate the IOL. If sufficient capsular support is present, the IOL may be placed in the ciliary sulcus with

optic capture on an intact anterior or posterior continuous curvilinear capsulorhexis, or sometimes if rarely, fully into the capsular bag.

4.3.2.1 Capsular Fixation

Capsular fixation refers to the use of the capsular bag or anterior/posterior capsular shelf to fixate a subluxed PCIOL. In most instances, there is some capsular fibrosis present which can be used for support if intact with good zonular support.

Repositioning of the IOL with capsular bag fixation, which is typically performed for inadvertent bag-sulcus positioning of a PCIOL, requires sufficient zonular support and an intact capsular bag (i.e., posterior capsule intact). If the capsular bag is decentered or has greater than 3–4 clock hours of dialysis, fixation by alternative means should be sought.

These cases typically have one haptic and the optic partially in the bag, with the remaining capsular bag leaflets fused together. If an intact capsular bag is present, careful viscodissection of the anterior capsule away from the posterior capsule may be performed with the assistance of Sinsky or Kuglen hooks, or anterior segment microinstrumentation such as micrograspers (MST, Redmond, WA) (Figs. 4.16–4.18). The existing IOL is then manipulated into the capsular bag, which is inflated with a cohesive ophthalmic viscodevice, using microforceps or with a Sinsky hook. In certain instances if required, a capsular tension ring may be placed into the now fully reopened capsular bag. This repositioning may be performed with two paracentesis-type incisions positioned at the surgeon's right and left hand positions when sitting temporally. Suture closure of these wounds may be necessary depending on their sealability at the conclusion of surgery.

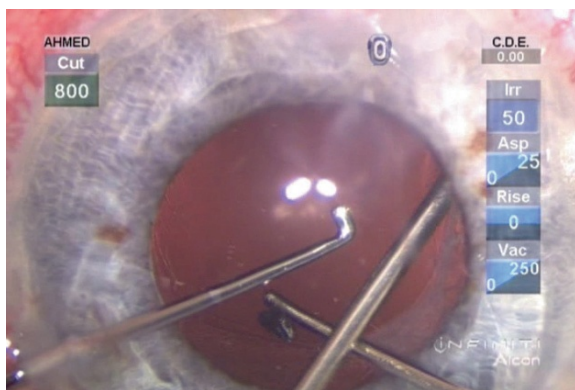


Fig. 4.16 A fibrosed capsular bag is re-opened with the combination of a Sinsky hook, a Kuglen hook, and generous injection of ophthalmic viscosurgical device (OVD)

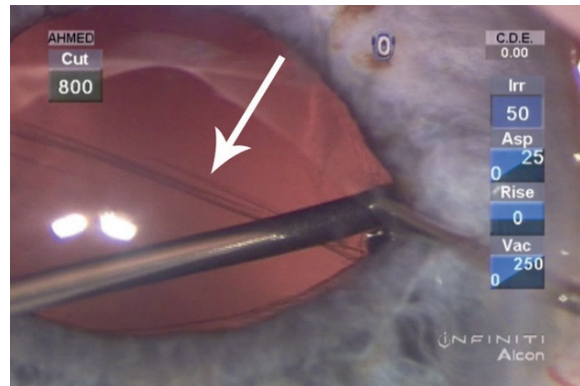


Fig. 4.17 As a Kuglen hook retracts the anterior capsule, OVD is injected to expand the capsular bag equator. Note the striae in the intact posterior capsule

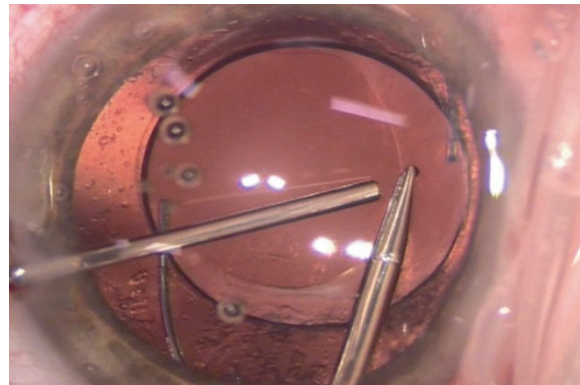


Fig. 4.18 Microforceps may be used to assist in lifting the anterior capsule off an IOL optic. OVD is then used to further viscodissect the IOL from its capsular adhesions

Alternatively, the anterior capsule shelf may be used for support of a sulcus placed PCIOL – which may be optic captured into an appropriately sized capsulorhexis if possible. The advantage of this technique is that it may be used in cases of posterior capsule loss, and does not require suture fixation. However, it is critical that the zonular apparatus is stable, and at least an intact anterior capsular shelf exists. Certain PCIOLs (i.e., larger rigid PMMA designs) may be more advantageous for this type of fixation as they may be less likely to sunset within the sulcus space if optic capture into the capsule is not possible.

Capsular fixation may be achieved with anterior optic capture where the optic sits anterior to the capsulorhexis and the haptics behind the capsule (Fig. 4.19), or vice versa where the haptics lie in the ciliary sulcus and the optic is posterior to the capsular remnant (Fig. 4.20). The position of the IOL preoperatively affects the decision to proceed with anterior or posterior optic capture. A subluxed PCIOL resting partially or completely in the sulcus

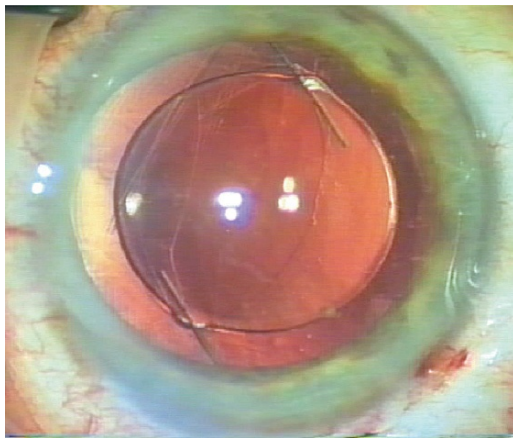


Fig. 4.19 A three-piece IOL, which has been anteriorly captured, with the haptics behind the anterior capsule and the optic anterior to it

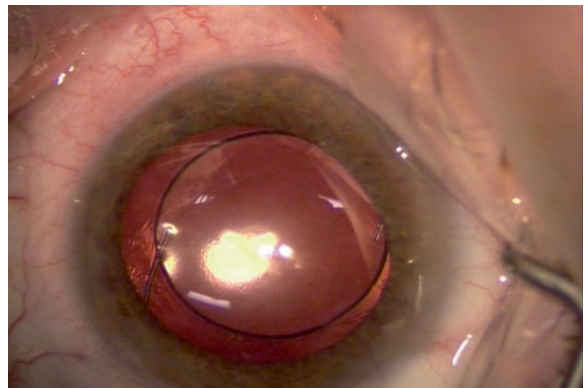


Fig. 4.21 A decentered three-piece acrylic foldable IOL in the ciliary sulcus

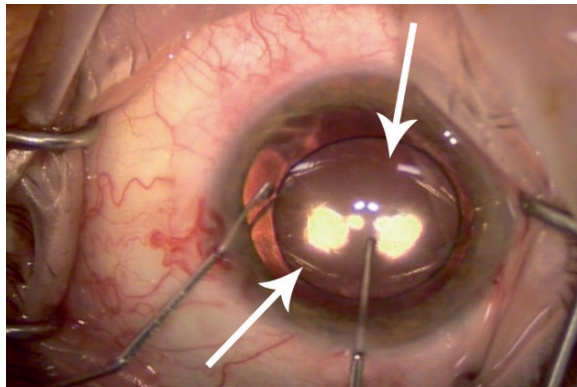


Fig. 4.20 A posterior optic capture has been performed of this three-piece foldable acrylic IOL. The haptics are sitting anterior to the anterior capsule with the optic posterior to it. Arrows indicate the ovalization of the continuous curvilinear capsulorhexis induced by the haptic-optic junction achieved during optic capture

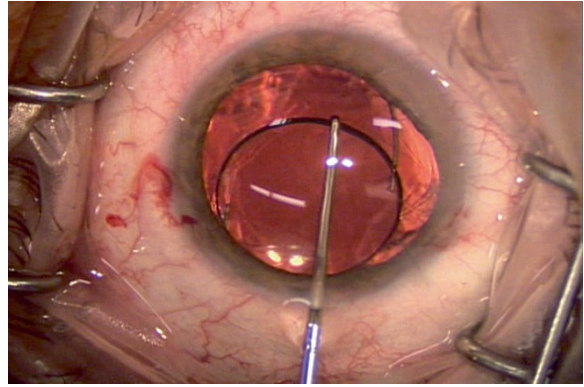


Fig. 4.22 A Sinsky hook is being used to maneuver the dislocated IOL into an optic capture position

preoperatively may be more easily repositioned with posterior optic capture, (Figs. 4.21–4.24) while a dislocated IOL which sits preoperatively behind the capsule in the anterior vitreous may be repositioned more easily with anterior optic capture. In order to secure an IOL which is dislocated in the vitreous cavity, a pars plana entry may be required 3–4 mm behind the corneoscleral limbus after a conjunctival peritomy. A pars plana vitrectomy may also be necessary to free a dislocated IOL of vitreous entrapment in order to reposition the IOL without inducing vitreous traction. Prior to initiating vitrectomy, the IOL must be secured by micrograspers in one hand, otherwise the IOL may further dislocate onto the posterior

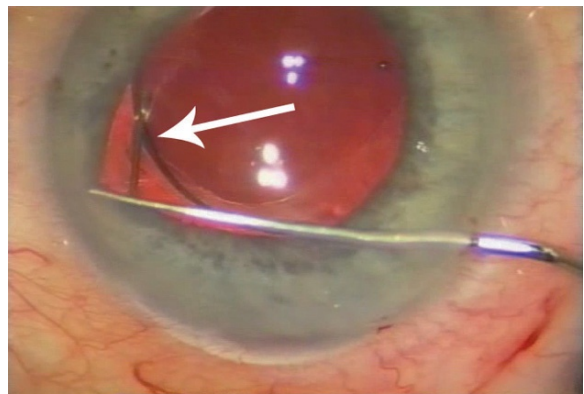


Fig. 4.23 A Kuglen hook has retracted the iris to show the peaking of the continuous curvilinear capsulorhexis induced by the haptic-optic junction in this posteriorly captured three-piece foldable acrylic PCIO

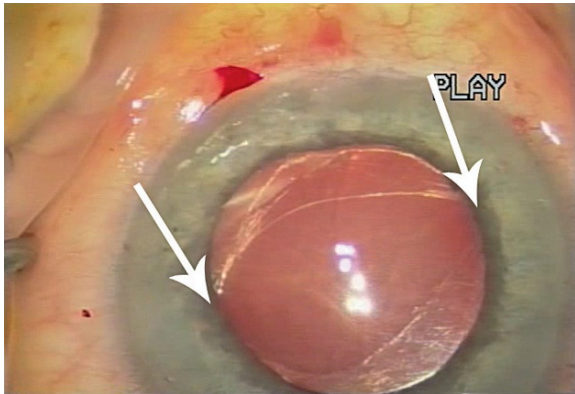


Fig. 4.24 Ovalization of the continuous curvilinear capsulorhexis is seen in an optic-captured IOL revealing the haptic positions (arrows)

pole necessitating the assistance of a retinal surgeon. An anterior chamber maintainer should be placed in a corneal incision to ensure that the pressure in the eye is maintained (Figs. 4.25–4.29).

In the case of posterior optic capture, the surgeon must be aware of the material of the IOL and its compatibility with the ciliary sulcus and undersurface of the iris. The one-piece acrylic IOL (e.g., SA60AT, SN60WE, Tecnis ZCB900) which has advantages of being flexible, slow to unfold in the eye, and gentle on the capsular bag and zonules during insertion, but also has thick and bulky haptics which are not designed to sit in the ciliary sulcus. When positioned here, these haptics commonly cause iris chafing, occasionally hyphema, and elevated IOP (the UGH). If this lens is present, in order to achieve capsular fixation, the haptics must be positioned behind the capsule, or else the IOL must be exchanged for a different type of lens (Fig. 4.30). The haptics of the one-piece acrylic IOL should never be placed in the sulcus or fixated to the

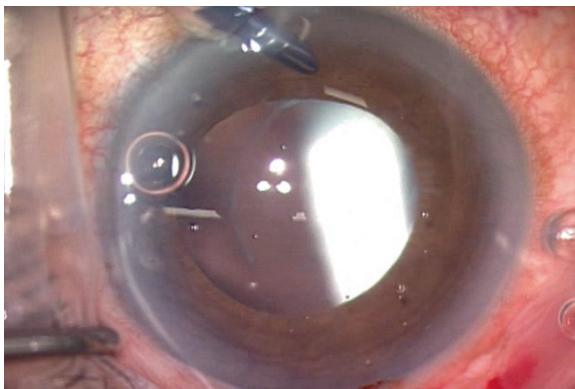


Fig. 4.25 An anterior chamber maintainer has been placed in this case of a dislocated in-the-bag PCIOL with a significant calcified Sommering's ring visible in the vitreous cavity

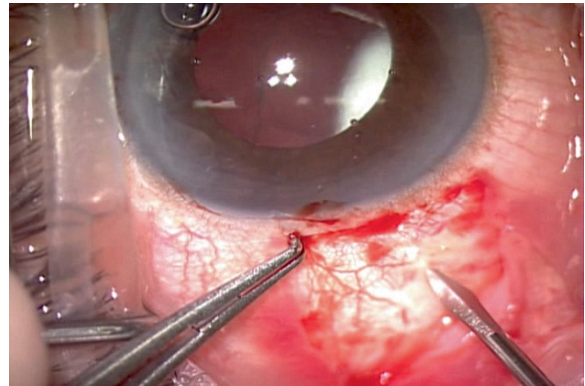


Fig. 4.26 A conjunctival peritomy has been created, and a microvitreoretinal blade is used to create a pars plana entry to allow for ease of access to this dislocated PCIOL in the vitreous cavity

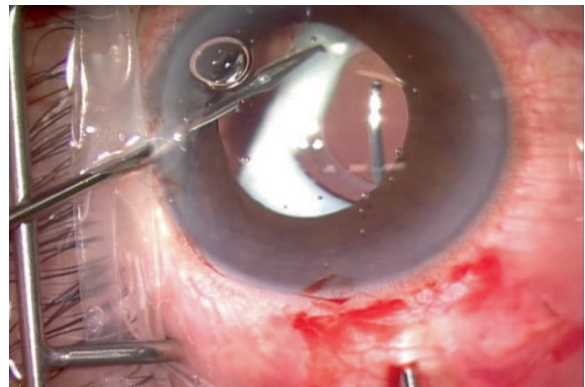


Fig. 4.27 Microforceps have been used to grasp the IOL-capsular bag complex at the haptic-optic junction, while a Sinsky hook inserted through the pars plana has been used to support the IOL

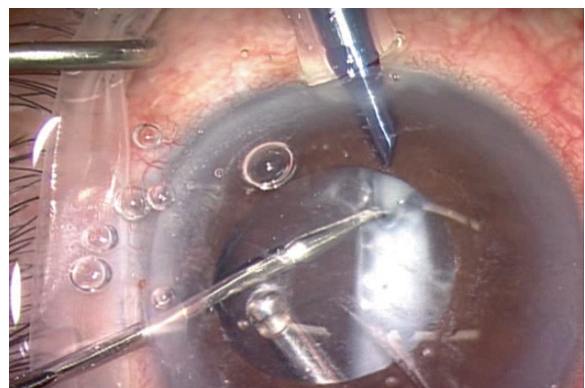


Fig. 4.28 A vitreous cutter is inserted in the pars plana to free the subluxed IOL-capsular bag complex of vitreous adhesions prior to prolapsing it forward into the anterior chamber. Note that the vitreous surface has been stained with triamcinolone to assist in visualization. Care should be taken not to disturb the Sommering's ring during vitreous cutting. The anterior chamber maintainer provides infusion while the IOL is secured at all times with the microforceps and should not be released until fully in the anterior chamber

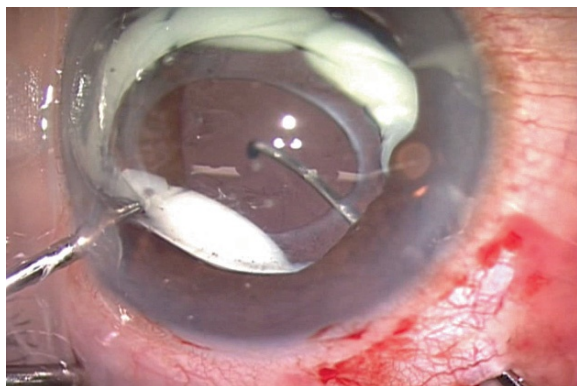


Fig. 4.29 Once the IOL-capsular bag complex has been freed of vitreous adhesions, the complex is prolapsed forward into the anterior chamber with the microforceps and a Sinsky hook is inserted through the pars plana to support and rotate the IOL forward

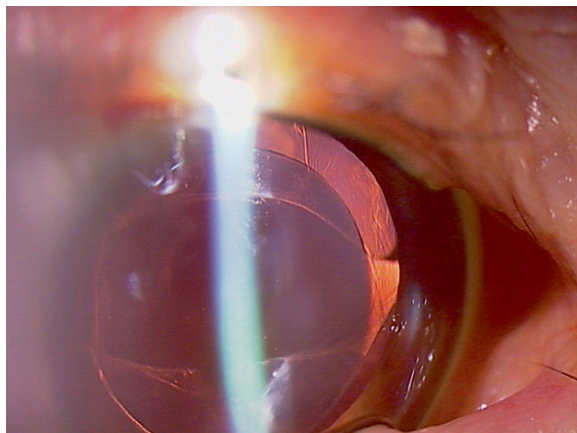


Fig. 4.30 A one-piece acrylic IOL which has been anterior optic captured showing the haptics behind the anterior capsule with the optic in front of it

posterior iris surface. It is the authors' preference that if a prior existing lens in the sulcus has caused irritation of the iris or ciliary body causing chronic inflammation or the UGH syndrome, the lens should be removed from the sulcus and an IOL placed elsewhere out of contact with the posterior iris surface.

When considering capsular fixation strategies, particularly if repositioning a lens freely into the ciliary sulcus, one must be confident that at least a good anterior capsule shelf exists, and there are no major zonular defects present. If not stable, a sulcus placed IOL will likely sunset. Furthermore, if a large Sommering's ring is present, there may be insufficient space in the sulcus to place an IOL, or this may result in lens tilt.

4.3.2.2 Scleral Sutured Repositioning

Scleral suture repositioning of a dislocated IOL should be considered for a decentered IOL in the capsular bag where a suture can be looped around one or both haptics (Figs. 4.31–4.33). Additionally, if a capsular tension ring (CTR) is present, it should strongly merit consideration for scleral suture repositioning as the CTR can provide a 'backbone' for scleral fixation of the capsular bag/IOL/CTR complex, and removal of these devices may be challenging (Fig. 4.34). Iris suturing of capsular bags with a ring in place is not recommended as this may cause pseudophakic pupillary block as the IOL is brought forward to the pupillary plane and the capsular tension ring within the bag further mechanically blocks aqueous from

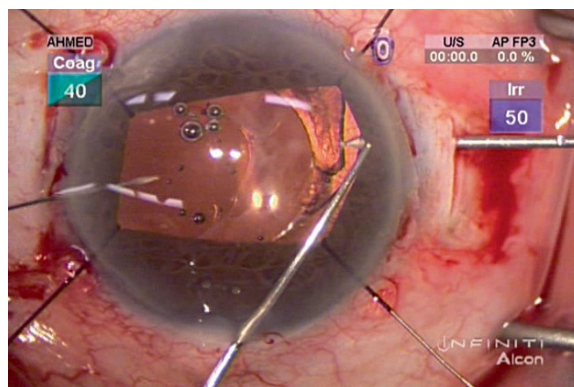


Fig. 4.31 Scleral suturing of an in-the-bag one-piece foldable acrylic IOL. A 9-0 polypropylene suture needle is seen on the left through a corneal paracentesis, while a 26-gauge hypodermic needle has punctured the sclera, on the right, through the ciliary sulcus. A Kuglen hook has retracted iris tissue to assist in visualization of needle position

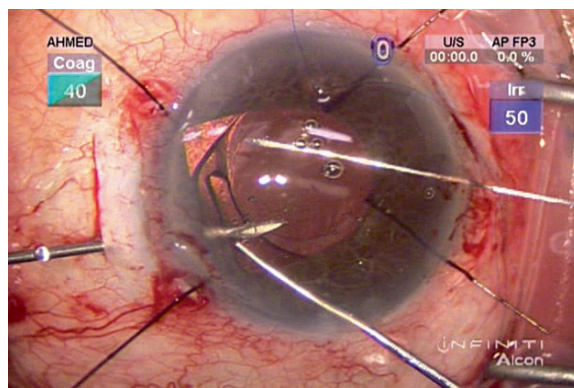


Fig. 4.32 The opposite haptic is sutured to the sclera in a similar fashion. The Kuglen hook may be used to provide counter-traction for the passage of the hypodermic needle through the capsular leaflets

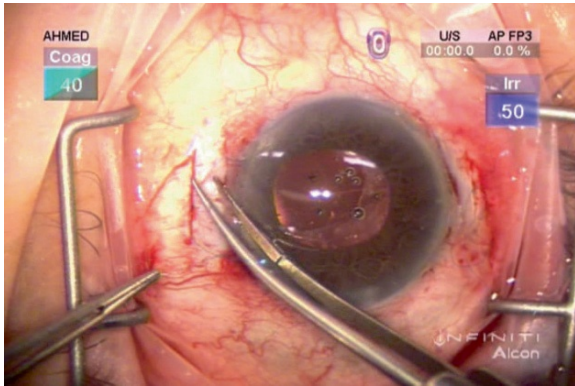


Fig. 4.33 The two loose ends are tied externally in the bed of the scleral scratch and rotated into the sclera

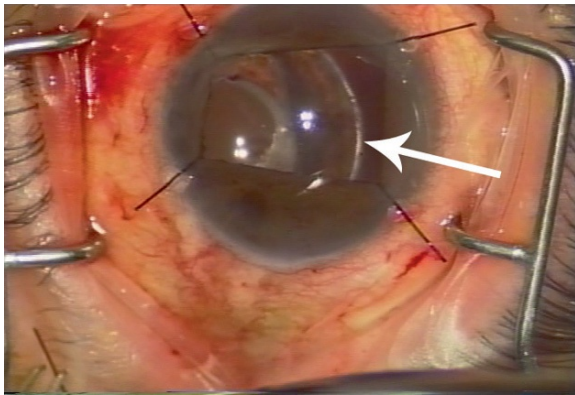


Fig. 4.34 A dislocated IOL-CTR-capsular bag complex. *Arrow* indicates the light reflection off the capsular tension ring

traveling forward into the anterior chamber. In some cases, an aqueous misdirection syndrome may be precipitated if this is performed.

Attempts to fixate a freely mobile PCIOL of any design to the sclera is risky unless a suture knot can be placed around the haptic as these lenses do not typically have fixation eyelets for suture placement. Looping the haptics with suture risks rotation of the haptics out of the loop. Although there are techniques to externalize haptics for suture knotting, it is the authors preference to avoid scleral fixation of an out-of-the-bag IOL. Conditions are different when the PCIOL is in the bag as these haptics can be simply looped with little risk of rotation as the fibrotic bag around the haptic typically 'holds' the suture loop in place.

Most open haptic PCIOLs – whether one- or three-piece – are amenable to scleral suture fixation when in the capsular bag. As plate lenses do not have an haptic to loop, scleral fixation is not possible unless a CTR is in the capsular bag.

Once it has been determined that scleral suture repositioning will be performed, the position of the sutures to be placed and the number of sutures required for repositioning and stabilization must be determined. Anywhere from one to three sutures may be required for adequate stabilization of the IOL to the sclera. If the IOL is dislocated in one direction and zonular integrity is observed in the direction of the subluxation, one suture placed around the haptic in the vicinity of the zonular absence may be sufficient to recenter and stabilize the IOL. However, if severe zonular weakness is noted and one suture is insufficient to stabilize the IOL, another suture at 180° from it may be needed to loop around the second haptic. When there are additional devices in the capsular bag such as a capsular tension ring, while two sutures may be sufficient to recenter the IOL, profound zonular weakness may place the IOL/CTR/capsular bag at increased risk for tilting resulting in refractive instability postoperatively. In these cases, three equidistant sutures may be required to adequately stabilize the IOL. With this arrangement, the resultant suture positions are as close to 120° apart from each other as possible. When the zonular dialysis is localized, typically a single suture is sufficient to fixate and stabilize a IOL/CTR/capsular bag complex, as the CTR acts as a backbone of support (Figs. 4.35–4.37) [3, 22, 23].

A conjunctival dissection is performed in the area of anticipated suture placement using blunt-tipped scissors such as Westcotts and a grasping forceps. As suture placement will be approximately 1.5–2 mm posterior to the limbus and further posterior in highly myopic eyes, the limbal conjunctival peritomy need not be a large one. A very superficial scleral scratch incision of approximately

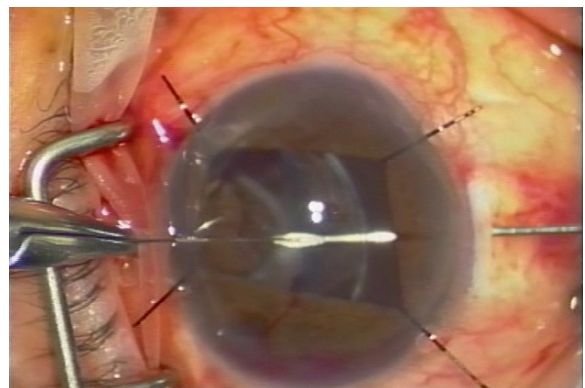


Fig. 4.35 In a similar fashion to scleral suture fixation of an IOL haptic, the suture is looped around the capsular tension ring which acts as a backbone of support for the entire IOL-CTR-capsular bag complex

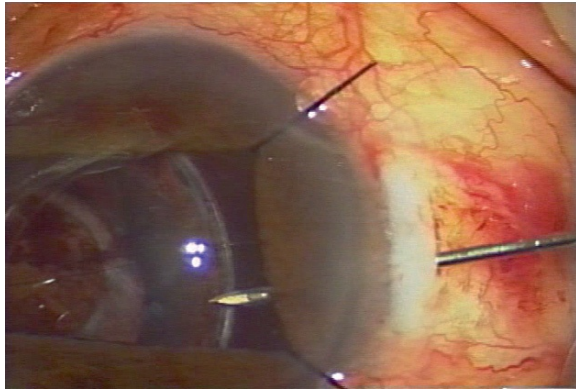


Fig. 4.36 A second needle pass is made completely anterior to the capsule and ring to loop the capsular tension ring

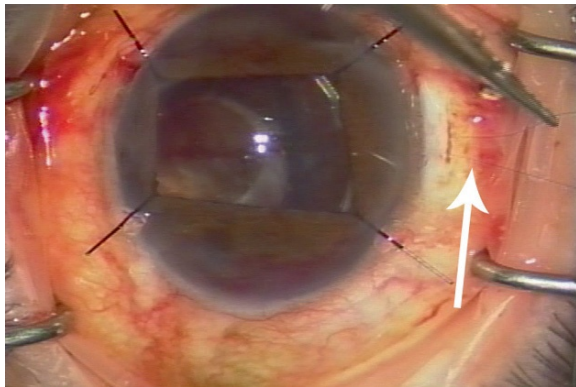


Fig. 4.37 The two externalized suture ends (*arrow*) are used to gently pull and re-center the dislocated IOL-CTR-capsular bag complex

2 mm in length is made in the sclera circumlimbally after measurement with a caliper to the appropriate distance posterior to the limbus. Light cautery is applied to the sclera for hemostasis. A corneal paracentesis is then created 180° from the desired position of suture fixation and the anterior chamber filled with viscoelastic for protection of the cornea as well as maintaining formation of the anterior chamber to prevent vitreous prolapse if none is present already. Anterior vitrectomy may be required with or without the assistance of intracameral triamcinolone staining to clear the anterior chamber of vitreous prior to suture passage through the anterior chamber. Once the anterior chamber is free of vitreous, a 26-gauge short hypodermic needle is used to pierce the sclera within the scleral groove and passed into the posterior chamber behind and subsequently through the posterior and anterior capsular leaflets and into the anterior cham-

ber. One end of a double-armed 9-0 polypropylene suture on a long straightened needle is then placed through the corneal paracentesis and docked into the lumen of the 26-gauge hypodermic needle. The needle/suture complex is then retracted out of the eye through the scleral groove. A second pass is carried out in similar fashion, though with the hypodermic needle passing completely anterior to the capsular bag and the other straightened 9-0 polypropylene needle docked into the hypodermic needle lumen once again. Once this is retracted, a loop now exists around the haptic with two free ends external to the sclera. The needles are cut off and the ends tied in a slipknot fashion to allow adjustment of the tension of the sutures while visually assessing IOL centration and tilt. The knot is then rotated carefully into the sclera with a non-toothed forcep or a Sinsky hook. To maintain anterior chamber stability, it is the authors' preference to remove viscoelastic from the anterior chamber using a dry technique with a blunt 27-gauge cannula. Care must be taken not to collapse the anterior chamber potentially bringing vitreous forward. It is not uncommon that the IOP will be elevated postoperatively as viscoelastic clears from the eye. Even if most or all viscoelastic is evacuated from the anterior segment, it is common for viscoelastic to escape into the posterior segment. Topical antihypertensive drops as well as oral acetazolamide should be used to control the IOP according to the amount of residual viscoelastic left in the eye at the conclusion of surgery. The conjunctiva should be closed with vicryl sutures and the corneal incisions closed if necessary with nylon sutures (Figs. 4.38–4.45).

It is the authors preference to use 9-0 polypropylene to reduce the risk of postoperative suture breakage.

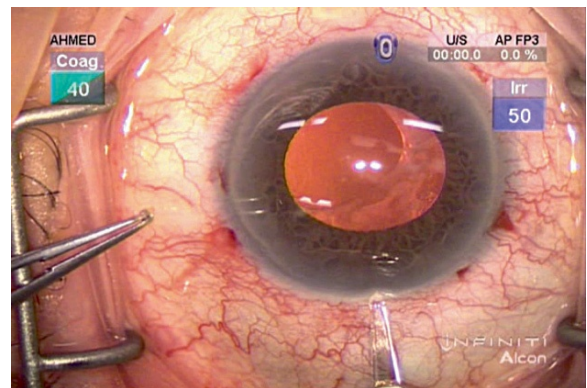


Fig. 4.38 Planning of incisions prior to surgical IOL repositioning or exchange is critical to intraoperative success. Here, multiple incisions have been made around the circumference of the limbus, as evidenced by the small spots of heme seen in this photo, to prepare for the placement of flexible iris retractors, as well as incisions for surgical instrumentation

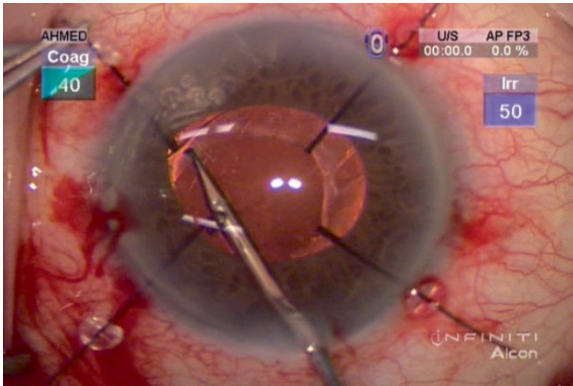


Fig. 4.39 Microforceps are used to grasp the anterior capsule to help fixate and provide counter-traction while a flexible iris retractor is placed on the capsular edge. Two iris hooks are seen to be on the capsule on the *right*

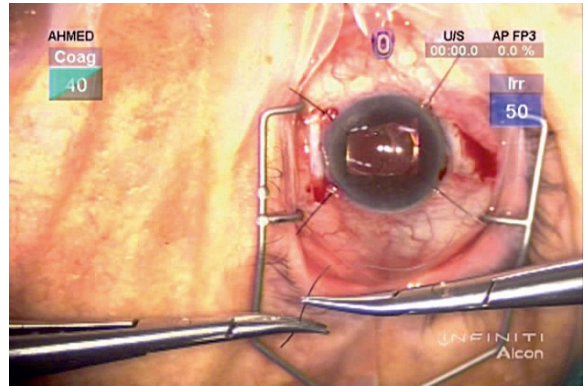


Fig. 4.42 The 9-0 polypropylene suture needle is straightened with two needle drivers

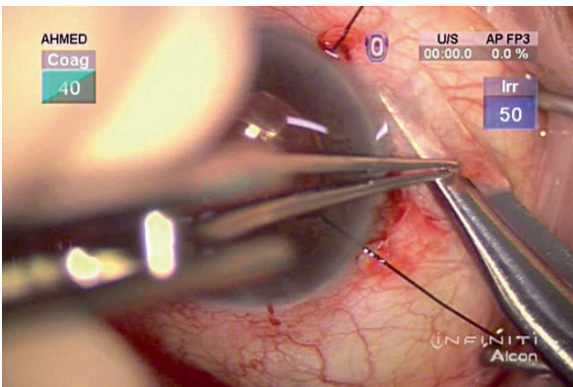


Fig. 4.40 In order to scleral suture, a dislocated IOL, a conjunctival peritomy must be created with blunt-tipped scissors using blunt and sharp dissection

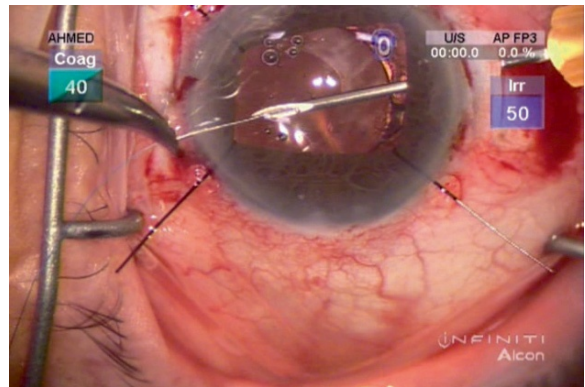


Fig. 4.43 The suture needle is then docked into the lumen of a 26-G hypodermic needle and then retracted out of the eye through the scleral needle entry

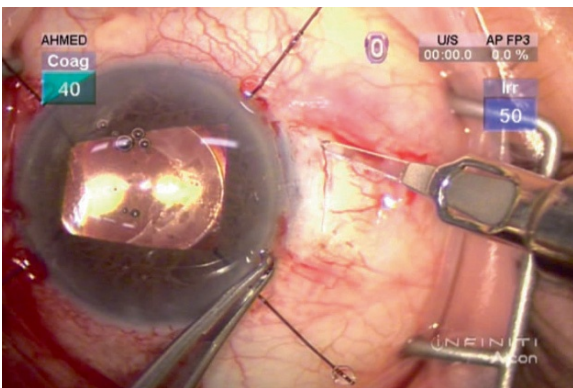


Fig. 4.41 A superficial scleral scratch incision is made to approximately 5% scleral depth of approximately 2–3 mm in length

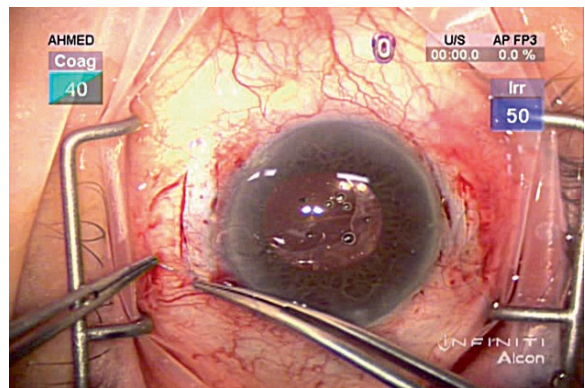


Fig. 4.44 Suture tension once tied is adjusted via a slipknot. When two or more sutures are required to fixate an IOL, it is critical to adjust the tension of each suture to achieve the desired IOL position and centration. Care must be taken not to overtighten sutures as this may cause further decentration of an IOL

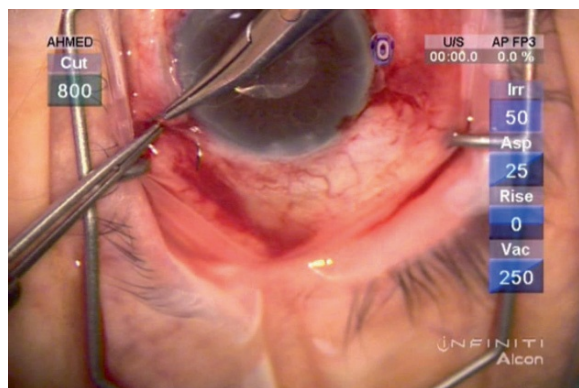


Fig. 4.45 Once suture tension is satisfactory, the knots are rotated into the sclera with non-toothed forceps or a Sinsky hook and then the conjunctiva is closed

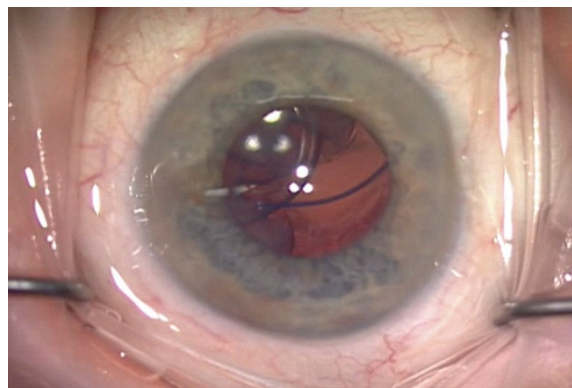


Fig. 4.47 A dislocated three-piece IOL in the ciliary sulcus with a capsular remnant present and a partial Sommering's ring, seen to the left

4.3.2.3 Iris Sutured Repositioning

Iris suturing of decentered PCIOLs is ideal for out-of-the-bag lenses (Figs. 4.46–4.47). It is the authors' preference to avoid directly suturing an in-the-bag IOL to the posterior iris due to risk of irido-capsular adhesion formation and/or shallowing of the anterior chamber due to the bulk size of the IOL/bag complex. In these situations, if iris-suture fixation is contemplated, the IOL should be removed from the bag first and the capsule evacuated from the eye.

Iris sutured repositioning should be reserved for specific haptic materials and design of IOL so as to avoid irritation or chafing of the posterior pigmented iris surface. PMMA haptics of the open haptic foldable lenses (i.e., acrylic or silicone) are best suited for this modality of suture fixation. Additionally, the posterior vault of the optic in these IOLs maintain the optic away from the posterior iris and result in an anterior positioning of the haptics resulting in its outline being readily visible on the iris

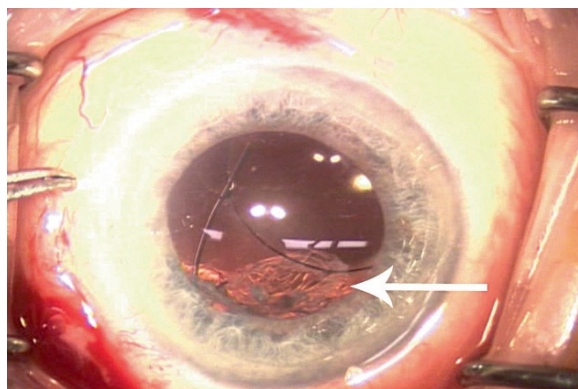


Fig. 4.46 A dislocated three-piece IOL which is freely floating in the anterior vitreous cavity. The capsule has contracted and fibrosed into a small remnant (arrow)

surface for suture passage. This visualization is of great value when passing sutures behind the iris to loop the IOL haptics. It is the authors' experience, however, that the haptics on the one-piece PMMA IOLs are difficult to suture to the iris due to difficulty visualizing the haptics under the iris. This is due to the combination that many older style PMMA IOLs are excessive large and do not have a vaulted design, as well as the haptic–optic junction of these IOLs being stiff and not flexible. As mentioned previously, the one-piece acrylic IOLs are not amenable to iris suture and this should not be considered a viable option of repositioning of these IOLs.

In order to properly fixate an IOL to the iris, capsular remnants and especially a residual Sommering's ring – if present – should be divorced from the IOL and removed. This may be done by supporting the bag temporarily in the retropupillary plane with iris hooks and removing the IOL from the bag first using micrograspers and hooks (Figs. 4.48–4.50). Alternatively, the IOL/bag complex can be brought into the anterior chamber first, and then the bag can be removed from the lens (Figs. 4.51–4.53). Removing the lens from the capsular bag lowers the incidence of pseudophakic pupillary block, which may be induced by bringing the IOL optic to the pupillary margin. Furthermore, a residual Sommering's ring may prevent proper visualization of the haptic outline through the iris, and may induce tilting of the IOL postoperatively.

The entire procedure may be done through multiple small corneal paracentesis type incisions. Iris suturing begins by ensuring that the IOL is secured, using anterior segment microforceps (MST), or Sinsky and Kuglen hooks. Occasionally, a pars plana incision may also be required to support the IOL or to gain access to it with minimal vitreous traction. Vitreous adhesions should be removed using a vitreous cutter while being absolutely certain that the IOL has been secured, lest the IOL slip on

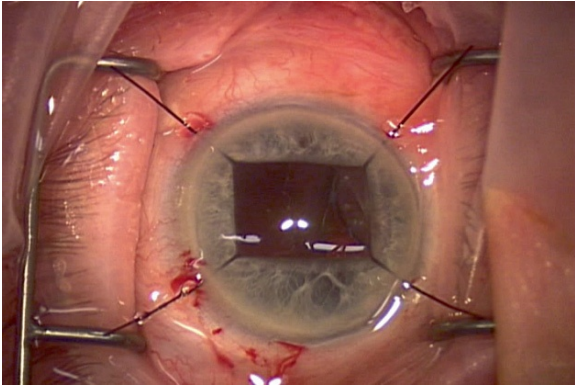


Fig. 4.48 Iris retractors have been placed to assist in visualization of this dislocated in-the-bag IOL. These iris retractors will also be used secure the IOL via the anterior continuous curvilinear capsulorhexis margin

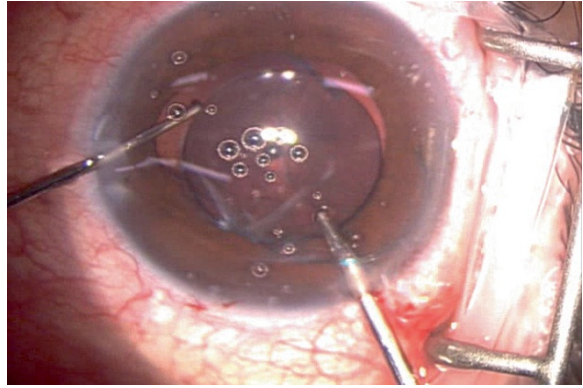


Fig. 4.51 In this case, the entire IOL-capsular bag is being brought into the anterior chamber with microforceps and a Sinskey hook

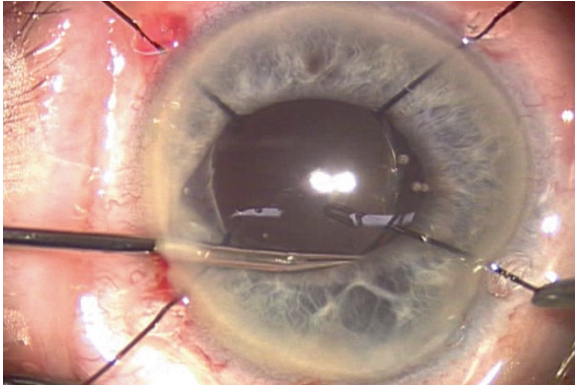


Fig. 4.49 The iris hooks are placed on the anterior capsular rim with the assistance of microforceps

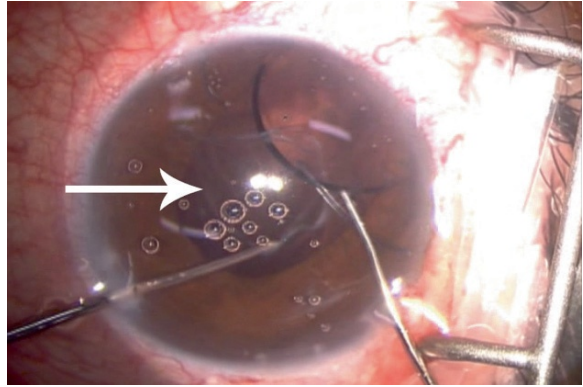


Fig. 4.52 The IOL is separated from the capsular bag (*arrow*), here with Sinskey and Kuglen hooks

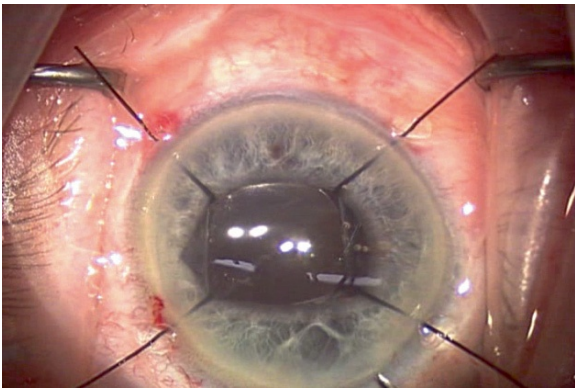


Fig. 4.50 The dislocated IOL-capsular bag complex has been secured with four iris hooks retracting the anterior capsule as well as the iris

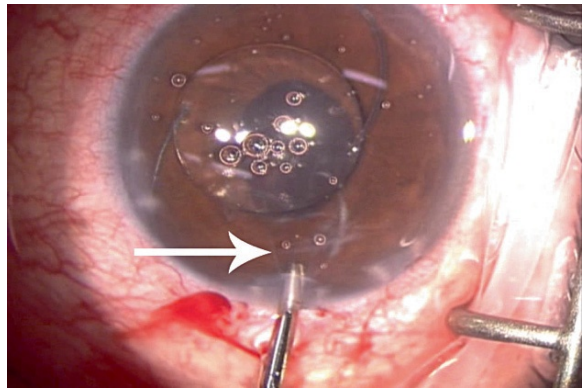


Fig. 4.53 Microforceps are used to remove the capsular bag in one piece (*arrow*)

to the posterior pole. Care must be taken not to injure the iris with the vitreous cutter. The entire IOL and capsular bag complex should be brought into the anterior chamber. Once this has occurred, preservative free 1:100 acetylcholine (Miochol[®]-E; Novartis Pharmaceuticals, East Hanover, NJ) should be injected intracamerally to induce miosis sequestering the IOL in the anterior chamber. Once the IOL has been isolated, the haptics are placed behind the iris using Sinsky and Kuglen hooks, or the assistance of microforceps. At this point, the pupil will be fairly ovalized in the shape of a 'cat's eye' pupil. A single-armed 10-0 polypropylene suture on a long curved needle is then passed through a corneal paracentesis incision being careful not to include corneal tissue in the suture bite. The needle is passed through the iris at approximately the mid-haptic point, traveling beneath the haptic, and then back anteriorly through the iris again to emerge in the anterior chamber. A 27-gauge cannula is inserted through a separate corneal paracentesis incision and the needle is docked into this cannula. The needle is carefully removed from the eye leaving a suture suspending the haptic behind the iris. This suture is then tied using a McCannel suture technique [18], a Siesper sliding knot technique or variations therein [24, 25], or tied intraocularly with microtying forceps (MST). This is repeated for the second haptic. Suture tension should be adjusted carefully to avoid trapping excess iris tissue into the suture knot resulting in bunching up of the iris tissue and an ovalized pupil. Care should be taken to ensure that the knots lie flat on the iris surface. Once both haptics have been secured, the sutures are cut with intraocular microscissors, or with Vannas scissors. The optic, at this point, should be gently pushed into the posterior chamber with a Sinsky hook, and IOL stability and pupil shape and size should be confirmed to be adequate. Once again, removal of viscoelastic from the anterior chamber should be performed by a dry technique with care taken not to collapse the anterior chamber. Oral and topical antiglaucoma agents should also be utilized postoperatively to prevent an acute spike in the IOP (Figs. 4.54–4.62).

It has been the authors' experience that a routine iridotomy or surgical iridectomy is not typically required in these patients as there is sufficient movement and space between the IOL optic and the pupillary margin, as well as the 10-0 polypropylene needle tracks acting as small iridotomies preventing pseudophakic pupillary block.

4.3.3 IOL Explantation and Exchange – Surgical Principles

Explantation of the pre-existing subluxed IOL may be necessary for various reasons. Opacification of an IOL

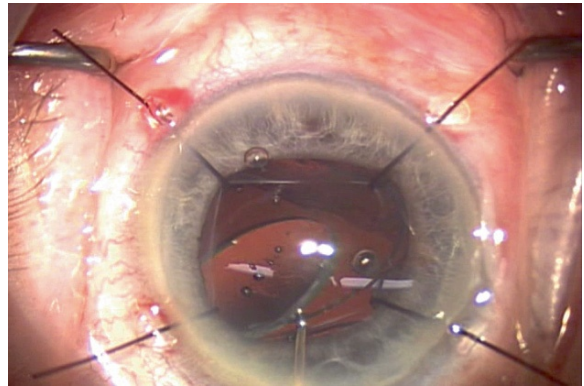


Fig. 4.54 Once the capsular bag has been stabilized with iris retractors, the IOL can be brought out of the capsular bag into the anterior chamber with generous viscodissection and a combination of microinstrumentation and Sinsky or Kuglen hooks

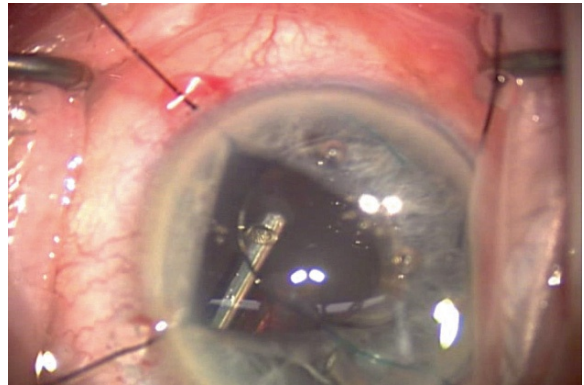


Fig. 4.55 With the IOL securely in the anterior chamber, a vitreous cutter through the pars plana is used to remove the residual capsular remnant

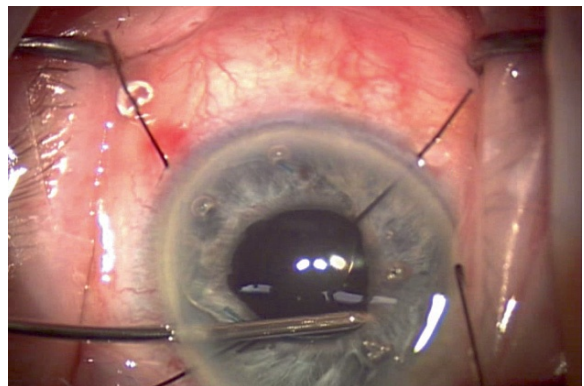


Fig. 4.56 The haptic of the three-piece IOL is grasped with microforceps and placed behind the iris. The same is done for the other haptic

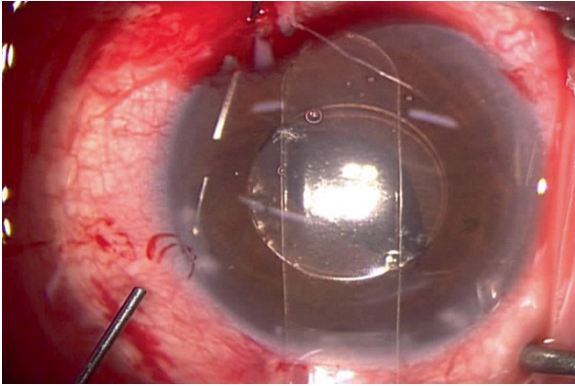


Fig. 4.57 An ovalized pupil results from the haptics placed behind the iris with the optic in the anterior chamber. In this case, a lens glide is used to support the IOL for security purposes. A 10-0 polypropylene suture on a curved needle is used to place a suture pass through the iris, under the haptic, and back through the iris into the anterior chamber

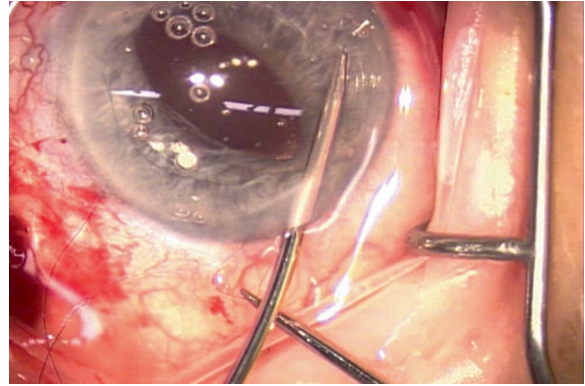


Fig. 4.60 The sutures may also be tied using a modified McCannel technique where one pair of forceps remains extraocular while the other travels intraocularly. This obviates the need to bring the iris to the incision to tie the suture knot

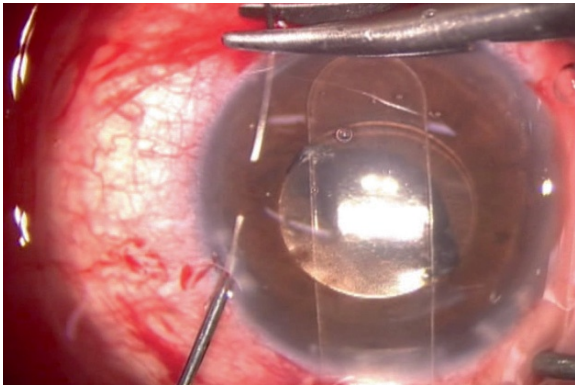


Fig. 4.58 The suture needle is docked into the lumen of a blunt 27-G cannula, and retracted from the eye to create a loop around the iris and IOL haptic

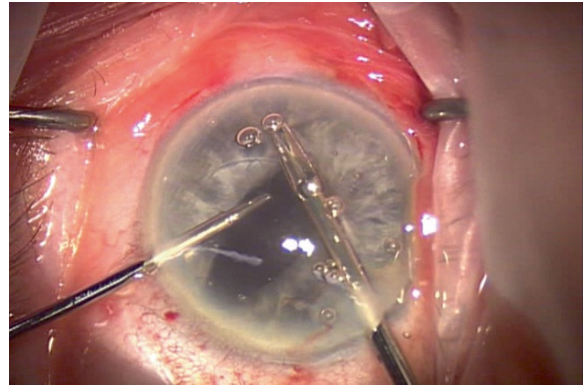


Fig. 4.61 Once a locked and secured knot has been tied, it can be brought to the nearest incision to be cut, but again, the authors prefer cutting the suture ends with microscissors for more controlled manipulation of the suture as well as minimizing trauma to iris tissue

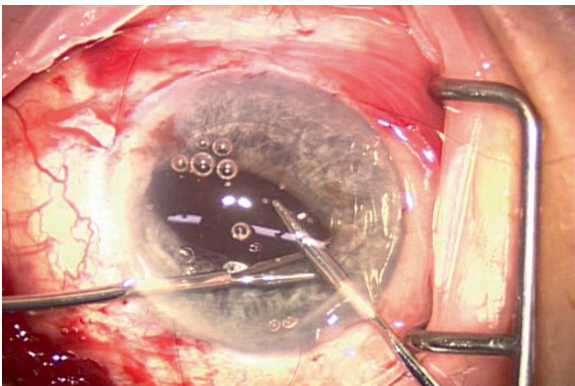


Fig. 4.59 While the iris suture can be tied using a McCannel technique, or a Siesper sliding knot or its variants, the authors prefer intraocular microtying with two microtying forceps because of the advantages of less trauma to iris tissue and maintenance of anterior chamber stability in the closed system

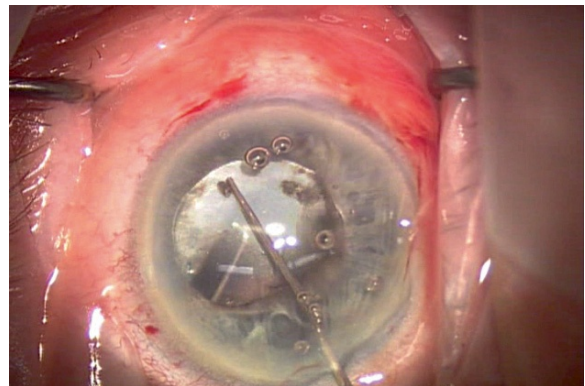


Fig. 4.62 Once the sutures have been successfully looped around the haptics, the optic is positioned into the posterior chamber using a Kuglen or Sinskey hook as seen here

optic [26], insufficient capsular support for the type of IOL in place, chronic inflammation and/or irritation of the posterior iris surface and ciliary body by an IOL, corneal decompensation due part or whole of the IOL in the anterior chamber, a structurally defective or damaged IOL, or an IOL which is not amenable to refixation with or without sutures, are all potential reasons for explanation of an IOL. The most important principle during IOL explantation is security of the IOL. During surgical manipulations, such as vitreous management and attempting to bring the IOL forward into the anterior chamber, it is not difficult to lose hold of the IOL thus allowing it to possibly fall on to the posterior pole. Once the IOL has been brought wholly into the anterior chamber and is free of vitreous adhesions, the pupil should be pharmacologically constricted with 1:100 acetylcholine to prevent loss of the IOL into the posterior segment as well as to barricade vitreous from prolapsing forward. Gener-

ous amounts of dispersive viscoelastic should be used to cover the pupil as well as coat the corneal endothelium to sandwich the IOL and prevent vitreous prolapse as well as minimize corneal trauma. Foldable lenses may be cut in half with an IOL cutter or folded to be removed through a small corneal incision (i.e., 3.5 mm). In the case of a non-flexible and brittle PMMA PC or ACIOLs, a large 6–7 mm corneal incision must be fashioned (Figs. 4.63–4.70).

If a secondary IOL is to be placed at the time of explantation, the options include the placement of an iris sutured IOL, placement of a scleral sutured IOL with pre-existing haptic eyelets designed for suture placement, or placement of an IOL in the anterior chamber. If sufficient iris tissue is not present for fixation of a suture to the iris or placement of an IOL in the anterior chamber, an IOL with an artificial iris diaphragm may be required (e.g., Morcher, Stuttgart, Germany, or HumanOptics, Erlangen, Germany) (Fig. 4.71). The anterior chamber lens options

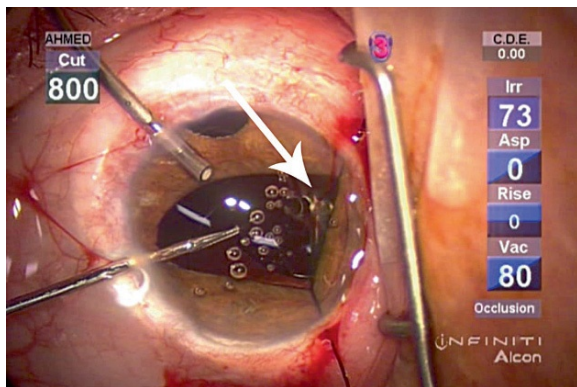


Fig. 4.63 The dislocated polymethylmethacrylate (PMMA) lens is secured with microforceps while the vitreous cutter is used to free the IOL of vitreous incarceration

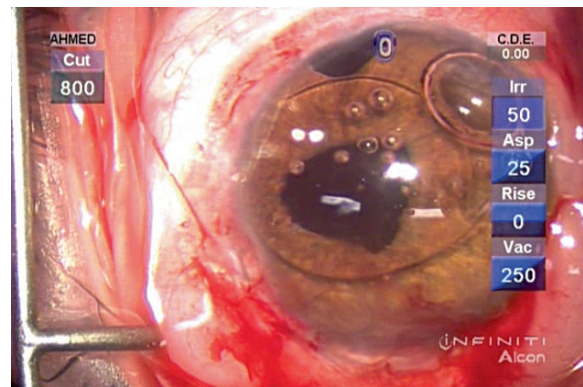


Fig. 4.65 Intracameral acetylcholine 1:100 has been instilled in the anterior chamber causing miosis which sequesters the IOL in the anterior chamber

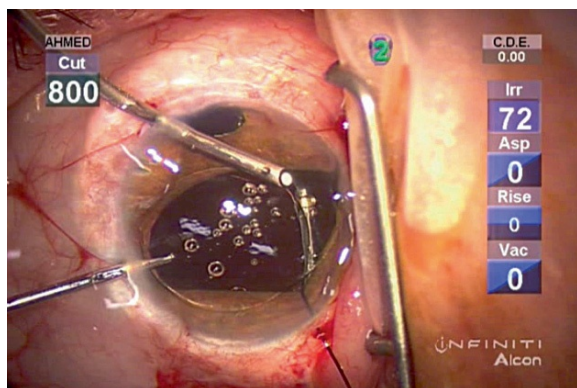


Fig. 4.64 The vitreous cutter may also be used to assist in bringing the IOL forward into the anterior chamber once freed of vitreous adhesions

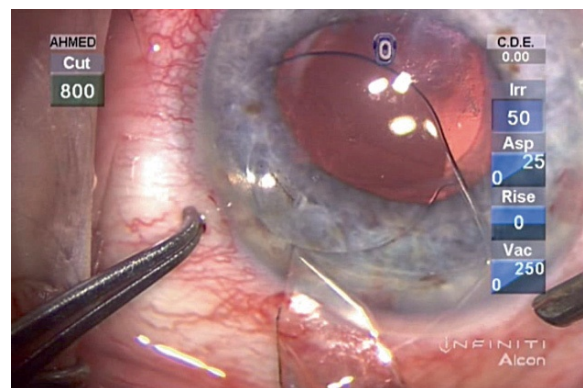


Fig. 4.66 When explantation of a rigid PMMA IOL is necessary, a large 6-mm incision is required to accommodate the size of the optic

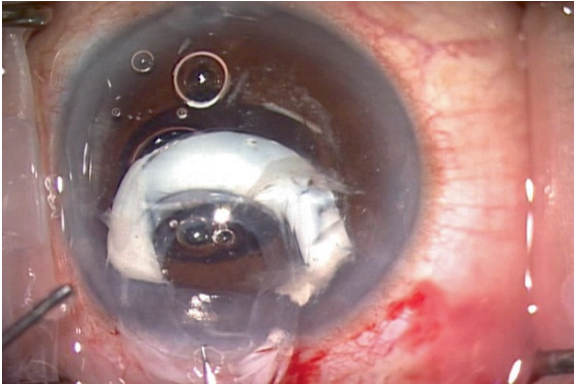


Fig. 4.67 A PMMA IOL along with capsular bag and Sommering's ring should all be explanted together being careful to not disrupt the Sommering's ring

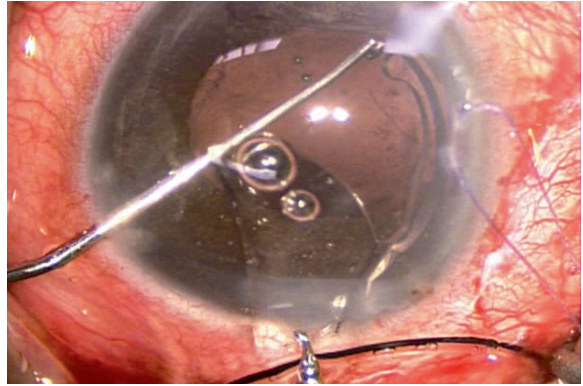


Fig. 4.70 The second half of the IOL is then explanted. A Kuglen or Sinsky hook may also be used to position the segment for ease of removal as well as for counter-traction on the eye

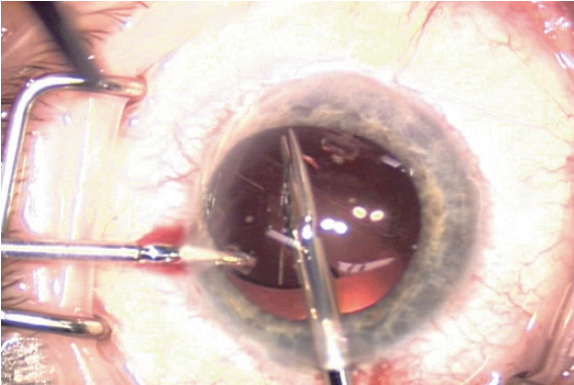


Fig. 4.68 IOLs composed of flexible materials such as acrylic and silicone can be cut if explantation is required. Here, fixation with microforceps is seen while an IOL cutter is used to cut the optic in half, allowing removal through a 3-mm incision

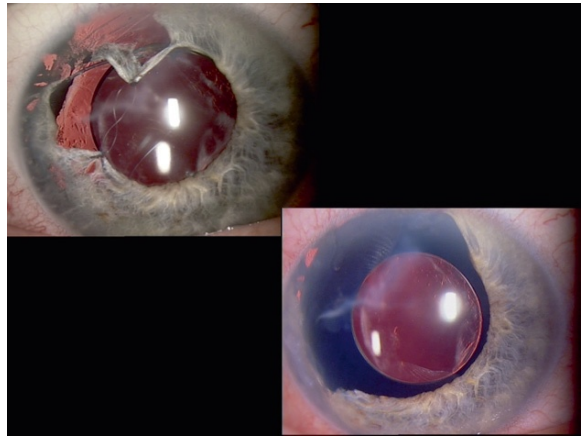


Fig. 4.71 An eye with a large iris defect has had the IOL exchanged and a Morcher 67-G aniridia IOL sutured in its place. The black artificial iris diaphragm is seen to cover the area of missing iris tissue

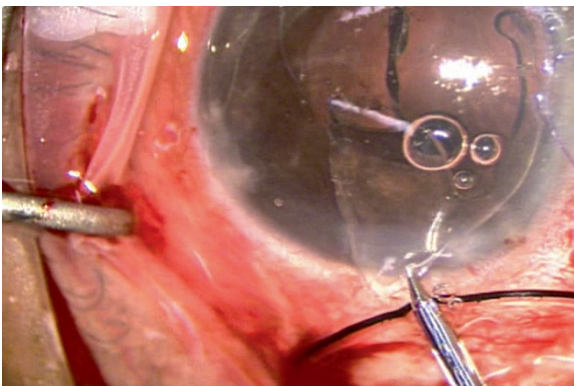


Fig. 4.69 The first half of a foldable one-piece acrylic IOL is explanted using microforceps

include the open loop haptic design, or an iris claw IOL. While the traditional angle fixated open loop ACIOL has disadvantages which are outlined earlier in this chapter, the authors' preference is to use the iris-claw IOL (Ophtec) because of its advantages as also outlined earlier. (Figs. 4.72–4.76).

4.4 Conclusion

As cataract surgery has evolved to modern day small incision phacoemulsification with endocapsular IOL implantation, complications related to the IOL have become less common. However, pseudoexfoliation syndrome, recognized or unrecognized intraoperative iatrogenic capsular

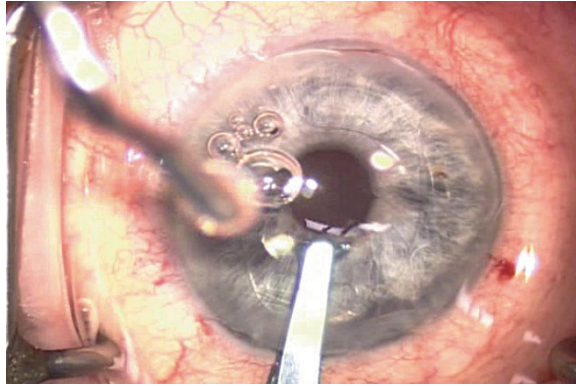


Fig. 4.72 The iris claw IOL is placed into the anterior chamber through a 6-mm incision

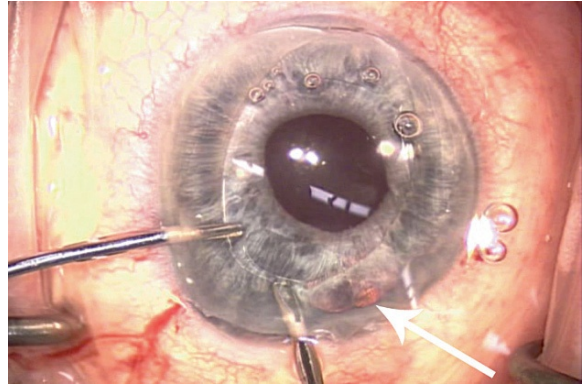


Fig. 4.75 The iris may also be enclavated into the claw haptic using microforceps to grasp the iris tissue. Note the iris retroillumination defect from the prior one-piece acrylic IOL placed in the sulcus causing posterior iris surface chafing (*arrow*)

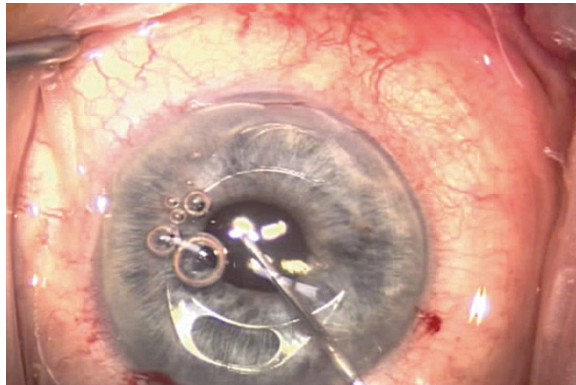


Fig. 4.73 A Sinsky hook is used to position the iris claw IOL centered over the pupil

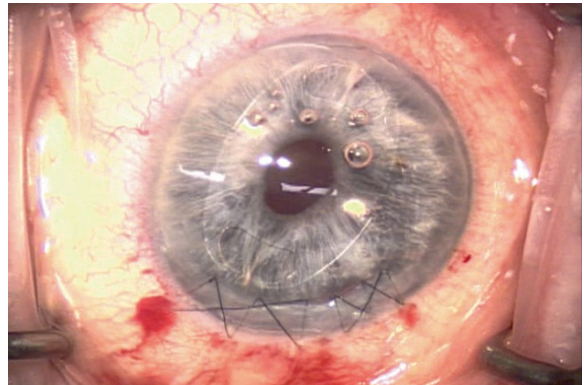


Fig. 4.76 The iris claw IOL is secured on the iris, centered over the pupil, and wounds closed with 10-0 nylon suture

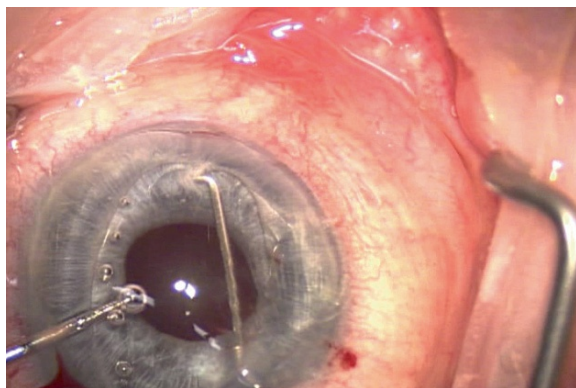


Fig. 4.74 The iris tissue can be brought in between the claw style haptics with an enclavation needle while stabilizing the IOL with microforceps

and zonular trauma, postoperative accidental trauma, inadvertent errant placement of the IOL during surgery, and incorrect sizing of IOLs remain reasons why IOL complications, subluxation, and decentration, will continue to be an issue despite advances of cataract surgery.

The surgical management of the malpositioned IOL includes attempts at repositioning by either capsular fixation, scleral suture repositioning, or iris suture repositioning, or IOL explantation and exchange. The specific choice depends on IOL design and material, IOL location, underlying support, and other factors. Each case must be treated on an individual basis with risks, benefits, and options communicated between the ophthalmic surgeon and the patient. When managed with proper atraumatic surgical techniques, patients with IOL-related complications can have excellent outcomes.

Summary for the Clinician

- The most common presenting signs and symptoms of IOL dislocation are glare, halos, edge effect, reduced visual acuity, monocular diplopia, increased cylinder manifesting as a refractive shift or instability, iris chafing, uveitis–glaucoma–hyphema syndrome, and cystoid macular edema.
- A malpositioned IOL may be a cause of other intraocular conditions such as chronic inflammation, hyphema, glaucoma, cystoid macular edema and corectopia.
- A thorough slit lamp examination, gonioscopy, undilated and dilated examination should be performed to assess the IOL position and determine its relation, if any, to other coexisting intraocular conditions. Supplementary testing such as anterior segment optical coherence tomography, endothelial cell specular microscopy, and ultrasound biomicroscopy may be useful to pinpoint IOL position, for surgical planning and assessing postoperative and intraoperative risk.
- Management of IOL dislocation is guided by a patient's symptoms. Observation or medical therapy with miotics may be sufficient.
- Refixation of the IOL to the capsule or capsular bag requires either an intact capsular bag or an intact anterior or posterior capsulorhexis with adequate zonular integrity. The IOL may be positioned entirely in the bag if the entire bag is present, or the optic may be captured into the capsulorhexis either anteriorly or posteriorly. Care must be taken to determine if the haptics are suitable for situation in the sulcus. Haptics such as the bulky haptics on the one-piece acrylic lens are not suitable for sulcus placement and thus should never be placed there.
- Scleral sutured re-fixation, typically reserved for in-the-bag PCIOLs, using 9-0 polypropylene suture involves looping a suture around a haptic and fixing it to the scleral wall and tying the suture externally. Anywhere from one-point to three-point fixation may be required, especially if a capsular tension device is present, depending on the overall integrity of the zonules.
- Iris sutured re-fixation using 10-0 polypropylene suture involves divorcing the capsular bag and residual Sommering's ring from the IOL if present, prolapse of the IOL optic into the anterior chamber, suturing the haptics to the pigmented undersurface of the iris, and then placing

The optic back into the posterior chamber. Certain haptics are better suited for this mode of re-fixation, such as the PMMA haptics of foldable lenses. The haptics of the one-piece acrylic IOL should not be placed in the sulcus or fixated to the undersurface of the iris.

- IOL explantation may be required due to optic opacification, structural damage to the IOL, insufficient capsular support for the type of IOL present, chronic inflammation or corneal decompensation due to the IOL, or an IOL not amenable to suturing or capsular re-fixation.
- Excellent outcomes are possible in patients with subluxed or decentered IOLs when managed with appropriate techniques and when the correct procedure is chosen.

References

1. Olson RJ, Mamalis N, Werner L, Apple DJ (2003) Cataract treatment in the beginning of the 21st century [perspective]. *Am J Ophthalmol* 136:146–154
2. Gimbel HV, Condon GP, Kohonen T, Olson RJ, Halkiadakis I (2005) Late in-the-bag intraocular lens dislocation: incidence, prevention, and management. *J Cataract Refract Surg* 31:2193–2204
3. Chan CC, Crandall AS, Ahmed IIK (2006) Ab externo scleral suture loop fixation for posterior chamber intraocular lens decentration: clinical results. *J Cataract Refract Surg* 32:121–128
4. Carlson AN, Stewart WC, Tso PC (1998) Intraocular lens complications requiring removal or exchange. *Surv Ophthalmol* 42:417–440
5. Boke WR, Kruger HCA (1985) Causes and management of posterior chamber lens displacement. *J Am Intraocular Implant Soc* 11:179–184
6. Smith SG, Lindstrom RL (1985) Malpositioned posterior chamber lenses: etiology, prevention, and management. *J Am Intraocular Implant Soc* 11:584–591
7. Hayashi K, Hirata A, Hayashi H (2007) Possible predisposing factors for in-the-bag and out-of-the-bag intraocular lens dislocation and outcomes of intraocular lens exchange surgery. *Ophthalmology* 114:969–975
8. Schneiderman TE, Johnson MW, Smiddy WE, Flynn HW Jr, Bennett SR, Cantrill HL (1997) Surgical management of posteriorly dislocated silicone plate haptic intraocular lenses. *Am J Ophthalmol* 123:629–635
9. Wilson DJ, Jaeger MJ, Green WR (1987) Effects of extracapsular cataract extraction on the lens zonules. *Ophthalmology* 94:467–470

10. Jehan FS, Mamalis N, Crandall AS (2001) Spontaneous late dislocation of intraocular lens within the capsular bag in pseudoexfoliation patients. *Ophthalmology* 108:1727–1731
11. Marques FF, Marques DMV, Osher RH, Freitas LL (2007) Longitudinal study of intraocular lens exchange. *J Cataract Refract Surg* 33:254–257
12. Jin GJC, Crandall AS, Jones JJ (2005) Changing indications for and improving outcomes of intraocular lens exchange. *Am J Ophthalmol* 140:688–694
13. Bayramlar H, Hepsen IF, Cekic O, Gunduz A (1998) Comparison of the results of primary and secondary implantation of flexible open-loop anterior chamber intraocular lenses. *Eye* 12:826–828
14. Hennig A, Evans JR, Pradhan D, Johnson GJ, Pokhrel RP, Gregson RM, Hayes R, Wormald RP, Foster A (1997) Randomized controlled trial of anterior-chamber intraocular lenses. *Lancet* 349:1129–1133
15. Lyle WA, Jin JC (1993) Secondary intraocular lens implantation: anterior chamber vs posterior chamber lenses. *Ophthalmic Surg* 24:375–381
16. Tahzib NG, Nuijts RM, Wu WY, Budo CJ (2007) Long-term study of Artisan phakic intraocular lens implantation for the correction of moderate to high myopia. *Ophthalmology* 114:1133–1142
17. Guell JL, Velasco F, Malecaze F, Vazquez M, Gris O, Manero F (2005) Secondary Artisan-Verisyse aphakic lens implantation. *J Cataract Refract Surg* 31:2266–2271
18. McCannel MA (1986) A retrievable suture idea for anterior uveal problems [Classic Ideas] *Ophthalmic Surg* 17:739–741
19. Smiddy WE (1989) Dislocated posterior chamber intraocular lens: a new technique of management. *Arch Ophthalmol* 107:1678–1680
20. Shin DH, Hu BV, Hong YJ, Gibbs KA (1988) Posterior chamber lens implantation in the absence of posterior capsular support [letter]. *Ophthalmic Surg* 19:606; reply by WJ Stark, CL Goodman, DF Goodman, JD Gottsch, 606–607
21. Condon GP, Masket S, Kranemann C, Crandall AS, Ahmed II (2007) Small-incision iris fixation of foldable intraocular lenses in the absence of capsular support. *Ophthalmology* 114(7):1131–1138
22. Ahmed II, Chen SH, Kranemann C, Wong DT (2005) Surgical repositioning of dislocated capsular tension rings. *Ophthalmology* 112:1725–1733
23. Ahmed II, Tam DY (2008) February Consultation #4. *J Cataract Refract Surg* 34(2):188–189
24. Sieser SB (1994) The closed-chamber slipping suture technique for iris repair. *Ann Ophthalmol* 26:71–72
25. Osher RH, Snyder ME, Cionni RJ (2005) Modification of the Sieser slip-knot technique. *J Cataract Refract Surg* 31(6):1098–1100
26. Apple DJ, Peng Q, Arthur SN, Werner L, Merritt JH, Vargas LG, Hoddinott DS, Escobar-Gomez M, Schmidbauer JM (2002) Snowflake degeneration of polymethyl methacrylate posterior chamber intraocular lens optic material: a newly described clinical condition caused by unexpected late opacification of polymethyl methacrylate. *Ophthalmology* 109(9):1666–1675

Toric Intraocular Lenses for Correction of Astigmatism in Primary Cataract Surgery 5

Thomas Kohnen, Victor Derhartunian, Daniel Kook, Oliver K. Klaproth

Core Messages

- Toric intraocular lenses (TIOL) correct astigmatic aberrations and thus enhance uncorrected and best-corrected visual acuity after cataract surgery.
- In addition to the usual preoperative cataract surgery examinations, it is essential to measure corneal topography to exclude irregular astigmatism and to determine the steep astigmatic meridian.
- Rotational alignment of TIOL has to be performed very precisely, as cyclorotational error negatively impacts cylinder correction and thus optical quality.
- In cases of postoperative rotational misalignment, TIOL can be rotated or laser refractive surgery can be performed to correct residual refractive errors.

5.1 Background

5.1.1 Astigmatism

Astigmatism is an optical aberration caused by the toricity of an optical system. If two meridians of an optical system with the least and highest refractive power are positioned perpendicular to each other, the resulting aberration is defined as regular astigmatism. Instead of one focal point, regular astigmatism results in two perpendicular focal lines and a circle of least confusion (Fig. 5.1). Regular astigmatism is defined as ‘with-the-rule’ (WTR) when the steepest meridian of the optical system is positioned between 75 and 105° (Fig. 5.2b) and as ‘against-the-rule’ (ATR) when the steepest meridian is positioned between 165 and 195° (Fig. 5.2c). Astigmatism in other directions (15–75° and 105–165°) is defined as oblique. In contrast to regular appearances of astigmatism, irregular astigmatism is characterized by, e.g., three or more main meridians of the optical system (generating higher order aberrations like trefoil, quadrafoil, etc.). Corneal dystrophies like keratoconus also result in irregular astigmatism. This astigmatism does not follow a typical kind of regular pattern. Figure 5.2d shows an irregular post laser in situ keratomileusis (LASIK) astigmatism. As technical-optical systems

can be designed with regular toricity, they are able to correct astigmatic aberrations of another toric optical system, just like spherical optics correct defocus aberrations of defocused optical systems (Fig. 5.2a). This is also the basic principle of toric intraocular lenses (TIOL) (Fig. 5.3).

5.1.2 Incidence of Astigmatism in the Cataractous Population

Cataract surgery with spherical IOL corrects defocus aberrations and improves transmission of the optical system by replacing the cloudy natural crystalline lens. The circle of least confusion is positioned on the fovea in this case, and astigmatism is not corrected. The incidence of regular corneal astigmatism greater than 1.5 D in cataractous patients is about 15–20% [1]. This equals approximately a difference of 0.3 mm in corneal curvature in the main perpendicular meridians (5.1). Due to this high percentage, it is obvious that astigmatism has to be taken into account to achieve good optical quality within the majority of cataract patients, as the ability of spectacle-free vision is highly appreciated and desired by these patients. Higher astigmatism (> 4.0 D) is often caused by intraocular surgery, corneal dystrophies or trauma, but may also occur as a natural phenomenon [1].

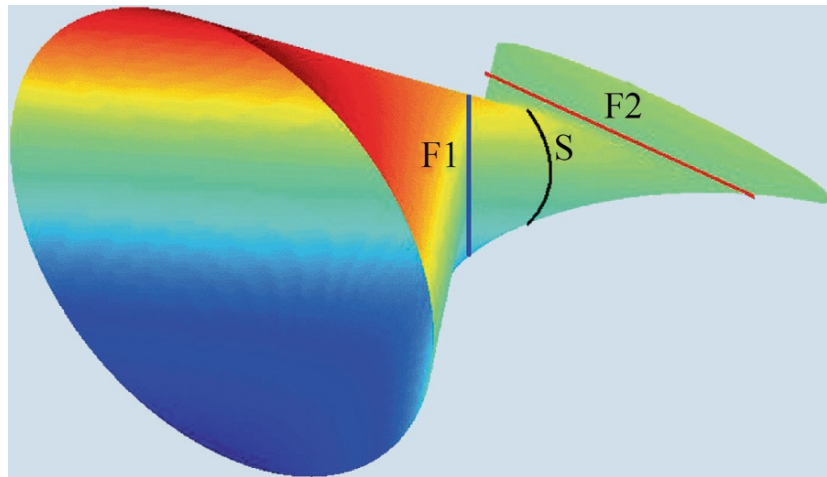


Fig. 5.1 Sturm Conoid. A bundle of rays is focused by an astigmatic optical system to two focal lines (F1 and F2). Between the foci the circle of least confusion can be found. (S)

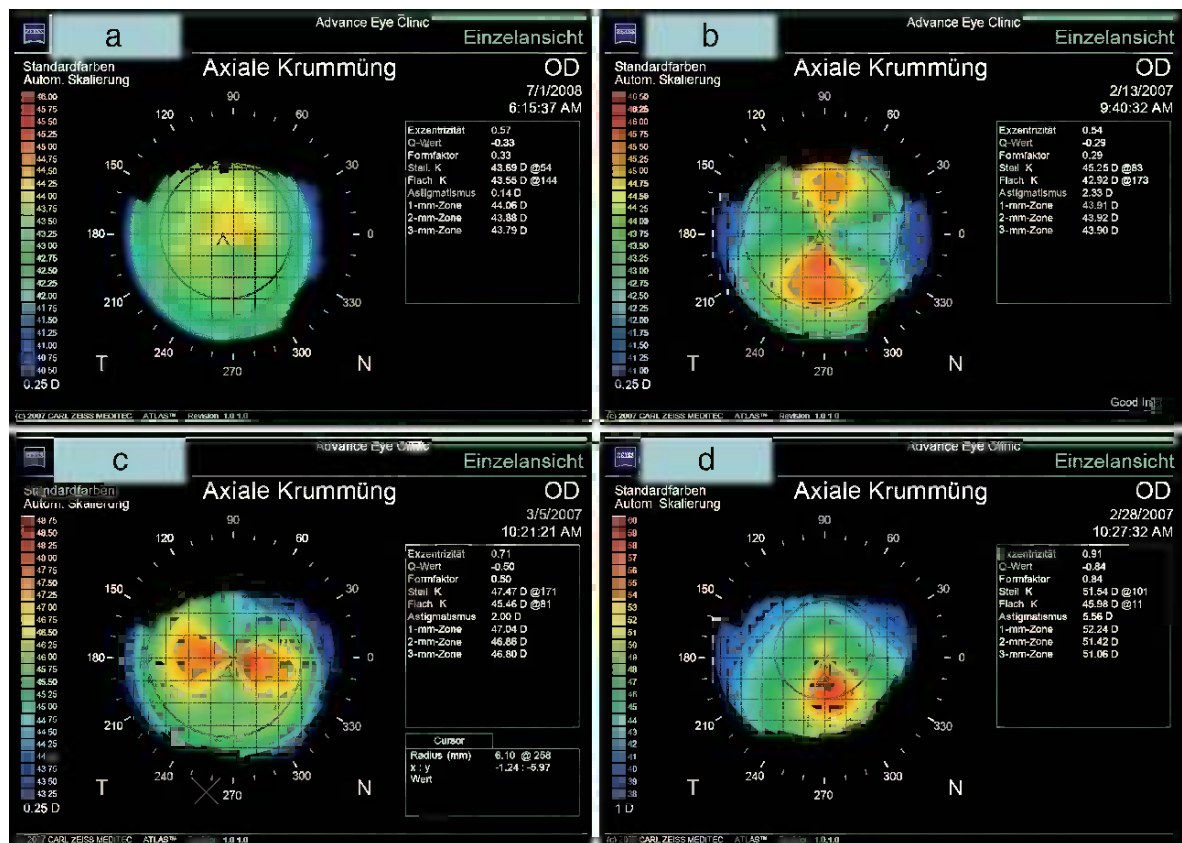
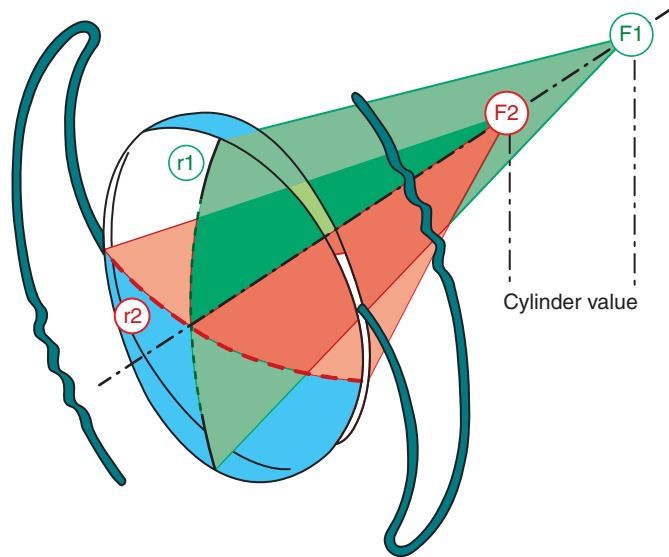


Fig. 5.2 Topographic maps of different appearances of corneal astigmatism. (Atlas 9000; Carl Zeiss Meditec, Jena, Germany), warm colors indicate steeper curvature and thus higher refractive power. (a) Almost nonastigmatic eye, (b) regular astigmatism with the rule, (c) regular astigmatism against the rule, (d) irregular astigmatism. Adapted from Langenbacher A, Anja Viestenz N, Szentmáry W, Behrens-Baumann A, Viestenz Berechnung torischer Intraokularlinsen Ophthalmologie (2008) 105:685–692

Fig. 5.3 Optic principle of TIOL. The reciprocal difference between the meridional refractive powers ($1/(F1-F2)$) characterizes the lenses' cylindrical power. This picture has been taken from the article "Toric intraocular lenses and correction of astigmatism" published in/Der Ophthalmologe/[11], modified and translated



$$\begin{aligned} D &= \frac{n_2 - n_1}{r} \\ n_1 &= n_{\text{air}} = 1 \\ n_2 &= n_{\text{cornea}} \approx 1.337 \end{aligned} \quad (5.1)^1$$

where D is refractive power [D], R is the radius [mm], n_1 is the refractive index of the medium in front of an optical effective surface, and n is the refractive index of the medium behind an optical effective surface.

Corneal (and TIOL) refractive power is described with the keratometric (K)- values as radii (mm) or diopters (D) (5.1) and the axis of the cylindrical power ($^\circ$). The axis is orientated perpendicular to the flattest meridian of the optical system when the cylindrical power is given in negative values. Thus, the following example of WTR astigmatism: sph.: -5.0 D cyl.: -2.0 D axis: 90° can also be described in terms of refractive power of the main meridians: $M_{\text{steep}} = -7.0$ D in 0° and $M_{\text{flat}} = -5.0$ D in 90° .

Astigmatism can generally be located in two different parts of the optical system of the eye: cornea, lens, or both. This issue is important, as the natural lens is extracted in cataract surgery and the lenticular part of ocular astigmatism is eliminated. The residual astigmatism is of corneal origin only. This has to be taken into consideration while determining whether to choose a spherical, aspheric,

toric, or atoric IOL. Corneal astigmatism, measured by keratometry or topography, is used to calculate the toric component of the intraocular lens. Figure 5.4 shows an

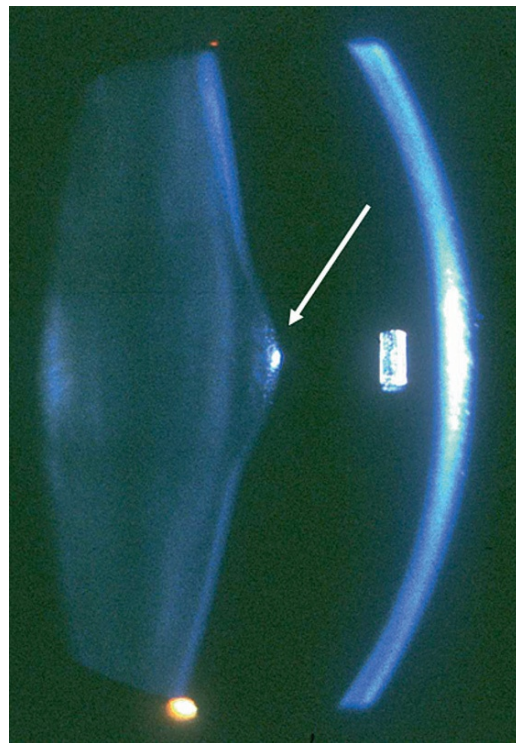


Fig. 5.4 Slit lamp image of an irregular lenticular astigmatism (anterior lenticonus)

¹ Refractive power of an optical effective surface, n_{cornea} is not a fixed value. Different authors and technical devices assume different values here.

irregular lenticular astigmatism (anterior lenticonus), which would have major impact on preoperative subjective refraction, but would not influence the postoperative astigmatism at all, if the crystalline lens is removed.

5.1.3 Surgical Correction of Astigmatism

The correction of regular astigmatism in cataractous patients results in an increasing uncorrected and mostly also best corrected visual acuity. Usually, correction is achieved by toric optics like glasses or contact lenses (soft or rigid). However, these traditional ways of correction cannot be used for all patients and do have several limitations, especially in cases of higher astigmatism. Therefore, total astigmatism is often minimized using different surgical procedures. One way is to use a particular incision site for cataract surgery in order to flatten the steep meridian of the cornea; however, today's incisions are very small and usually do not induce corneal astigmatism more than 0.25D. Thus, incisions needed to be enlarged for this method, but this has largely been abandoned because of its unpredictable astigmatic outcome. This correction by surgically induced astigmatism (SIA) [2, 3] requires a corneal incision, or with less effect a scleral tunnel incision, on the steep corneal meridian, parallel to the limbus [4]. Additional limbal relaxing incisions (LRI) are also possible. Another way of correcting astigmatism is excimer laser ablation, which can apply a toric ablation profile, also in addition to a spheric (or toric) IOL. Both described methods have a limited range of applicability. Predictability of SIA is often poor, and modern small or micro incision cataract surgery (MICS) techniques with incisions smaller than 2 mm do not induce and therefore reduce astigmatism. Due to postoperative corneal stability and corneal biomechanics, very high corneal astigmatism (> 5.0 D) can often not be corrected by refractive laser surgery. In this case, it is possible to combine both methods, or to use incisional techniques, like limbal relaxing incisions (LRI) in combination with one of the techniques mentioned above [5]. Major problems with incisional techniques are the lack of predictability, possible regression, and poor quality of vision under dim illumination. In addition, there is a limited scope of application, as postkeratoplasty astigmatism or astigmatism caused by keratoconus often cannot be treated adequately. In general, treatments of cylinders up to 2.5D should be performed with LRI, and larger cylinders (up to approximately 3.5D) with laser refractive surgery. TIOL can be an alternative solution in all such cases and also for higher cylinders [6, 7]. Implanted through small SIA neutral incisions, they offer the advantage of high predictability and also reversibility. More and more clinical trials have shown these advantages [8–11].

5.2 Toric IOL Technology

5.2.1 Concepts of TIOL for Primary Cataract Surgery

Toric IOL (TIOL) for primary cataract surgery are classified like spherical IOL. Available are models for 'in-the-bag' implantation and sulcus fixated models. Today, most TIOL are of the first type. Indications for the use of sulcus or in-the-bag fixated TIOL are equal to those of other TIOL, always taking into consideration that stability, especially rotational stability, is extremely important.

5.2.2 Advantages and Disadvantages of TIOL

Spheric IOL, implanted in eyes with a toric cornea, do only correct the spherical component. The resulting optical system has a circle of narrowest constriction which is placed on the fovea (Fig. 5.1), instead of a focal point or two focal lines. TIOL may correct astigmatism from approximately 1 to 30D. It has to be taken into consideration that total correction of astigmatism is not always the most comfortable correction for patients. Residual astigmatism may offer benefits like a minimum of pseudoaccommodation and less meridional aniseiconia, as differences in meridional magnification still appear, even if both meridians are corrected. TIOL allow the surgeon to calculate patients' postoperative astigmatism to its individual needs. On that score, it is helpful to ask the patients for their individual spectacle-wearing habits. If astigmatism has never been fully corrected, a total correction may result in marked discomfort. Tentative wear of astigmatism correcting eye glasses or contact lenses can give a hint to the surgeon about the preferred correction of the patient. However, in cataract patients, this method is limited by blurred vision due to the opacified natural lens.

Displacement of TIOL in the z-axis does not cause noticeable unwanted residual aberrations, as it just results in a small degree of defocus. In contrast, dislocation in x- or y-direction and tilt cause more aberrations. Most aberrations, however, are caused by cyclorotation around the z-axis of the TIOL. Rotation has a severe impact on the cylindrical power of the TIOL [12, 13]. With a rotational misalignment of 15° , only half of anticipated cylindrical correction is achieved. Misalignment of 30° results in no cylindrical correction at all, and 90° misalignment instead of reducing even doubles the amount of preexisting cylindrical power [11]. Therefore, TIOL have to be aligned with due diligence and need to be carefully controlled for postoperative rotational stability. Lenses with known poor rotational stability

are not suitable for correcting astigmatism and should not be implanted.

5.3 Handling of TIOL

5.3.1 Preoperative Measurements

For a comprehensive preselection of patients several measurements are essential. At first, main inclusion criteria should be evaluated. These are stable K - and refraction values. Before performing measurements, patients should take a 1-week period of soft contact lens restriction and 2 weeks or more with rigid contact lenses, respectively. Contact lenses may have an influence on the elevation of the anterior corneal surface (Fig. 5.5). Of course, the availability of cylindrical power of the specific IOL also has to be taken into consideration. All other indications and contraindications are the same as in all cataract patients [14].

In addition to keratometric measurements, it is necessary to perform topographic measurements, because

the keratometric values only show the conditions in the central cornea (approximately 3 mm in diameter; values differ according to the keratometric device used). To exclude irregular astigmatism (e.g., keratoconus), one has to evaluate the peripheral cornea. This can be done by different kinds of keratometric maps. Those maps show keratometric conditions of the whole cornea as axial or tangential K -values. Local disorders can be shown better in tangential than in axial keratometric maps, due to their higher local resolution [15]. (Figure 5.6 shows the axial (a) and tangential (b) keratometric map of the same cornea.) Tangential curvature is based on equation for curves on the corneal surface along the tangential planes of intersection representing curvature at a single point on the surface. Axial curvature, however, is the average of tangential curvature over an interval from the central corneal axis to a single surface point along tangential planes of intersection.

A subjective measurement of refraction is mandatory, because of the individual patient's perception habits. Full correction in sphere and cylinder is not always desired by the patients.

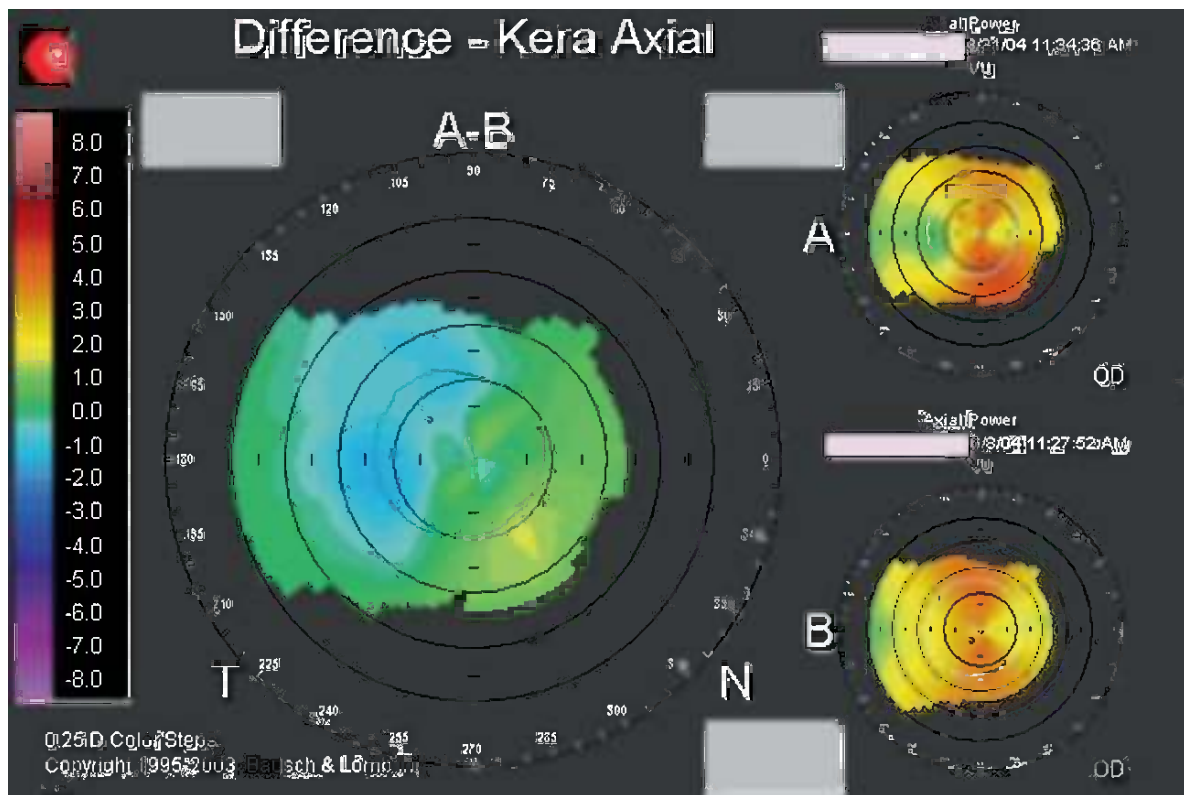


Fig. 5.5 Keratometric difference map between 3 days and 9 weeks after laser refractive surgery (Orbscan; Bausch & Lomb, Rochester, NY, USA). *Left image* Difference map, *upper right picture* 3 days postoperative, *bottom right* 9 weeks postoperative

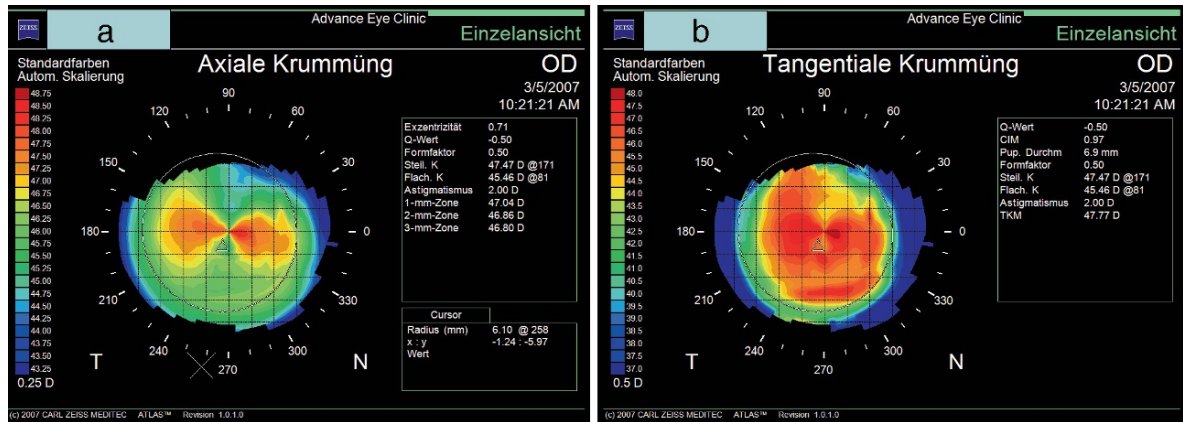


Fig. 5.6 Example for differences of axial and tangential keratometric maps of the same eye with ATR astigmatism (Atlas). (a) Axial imaging, (b) tangential imaging with higher local resolution. The tangential map shows the same eye, but with higher local resolution of curvature

5.3.2 TIOL Calculation

To calculate TIOL power, different parameters are needed. Axial length, refractive power of the cornea, and anterior chamber depth are essential data. Keratometric devices like Javal-, Zeiss-, Schiötz-principle-ophthalmometers, Placido- or Scheimpflug-keratographs, e.g., Orbscan Placido-Slit lamp Topograph (Bausch & Lomb Surgical, Rochester, NY, USA), Pentacam Scheimpflug-camera (Oculus Optikgeräte, Wetzlar, Germany), or IOL-Master (Carl Zeiss Meditec, Jena, Germany) measure corneal curvature. These curvature data are used to calculate the dioptric power of the cornea (5.1). But as different devices use different initial values for the corneal refractive index, dioptric values calculated with devices may vary. Therefore, it is generally advisable to calculate IOL power using corneal radii not dioptric power data. In this way, a device-independent IOL power calculation is feasible. Further, the sampling is different in devices as they use different numbers and locations of measurement points, and the accuracy and reproducibility of the devices themselves may also vary. The latter errors can only be avoided by individual nomograms.

Incision size plays an important role in IOL calculation, especially for TIOL. The smaller the incision, the less SIA is induced, the better are the postoperative results [3]. Further, predictability of postoperative astigmatism is improved. In practice, each surgeon should evaluate individual induced SIA for the preferred IOL. Therefore, incisions should always be located at the same position (which, in contrast to spherical IOL, should not be the steep meridian but one particular meridian in every eye, e.g., exactly in a temporal direction). Another option is

to calculate exactly the induced astigmatism for incisions in the surgeon's preferred location. Postoperative refraction and K -values should be monitored. Knowledge of personal SIA again improves predictability of resulting astigmatism and thus patients' postoperative optical quality [16]. In some manufacturers TIOL calculation software and order forms, the surgeon's individual SIA is required for calculation or ordering TIOL (Fig. 5.7). Combining techniques of TIOL implantation, SIA, and incisional surgery also minimize residual postoperative astigmatism [2, 17].

Different methods and schemes for calculation of TIOL power have been described [11, 18]. The easiest and safest way of lens calculation in practice is simply to follow the manufacturer's instructions. Order forms or calculation programs ask you for the required metrics.

5.3.3 Implantation of TIOL

To achieve good visual outcome, it is necessary to align TIOL as precisely as possible. Especially, cyclorotation of the lens around the z -axis must be prevented, as described above. Therefore, the following technique may be advisable:

1. A reference axis (e.g., in 90° , Fig. 5.8 or $0-180^\circ$, Fig. 5.9a) is marked in the sitting position, preoperatively. This marking can be performed with different kinds of markers and a color pen. Today, different kinds of markers are available and each surgeon should choose the one he or she feels most comfortable with.
2. The patient is now changed from sitting to supine position. If cyclorotation occurs, movement of the reference

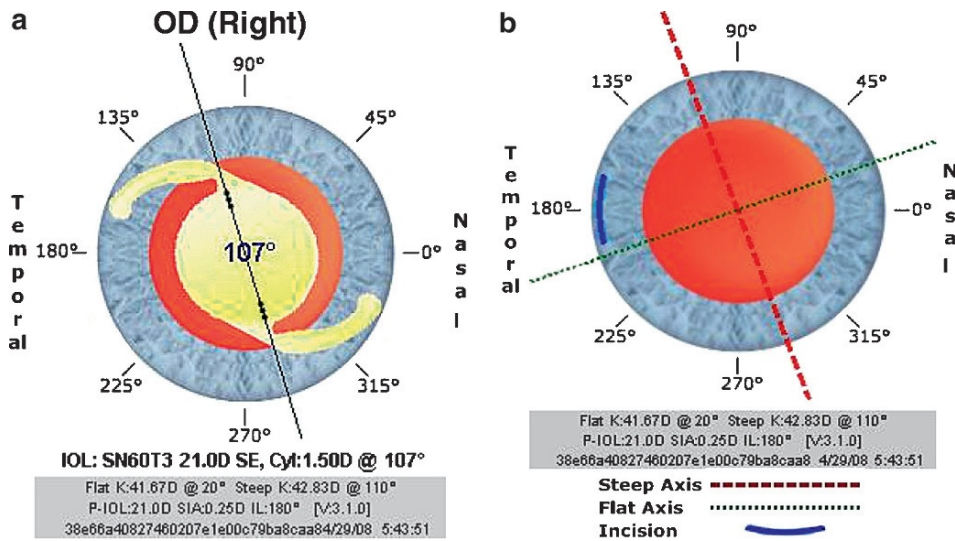


Fig. 5.7 Screenshot of online AcrySof calculator

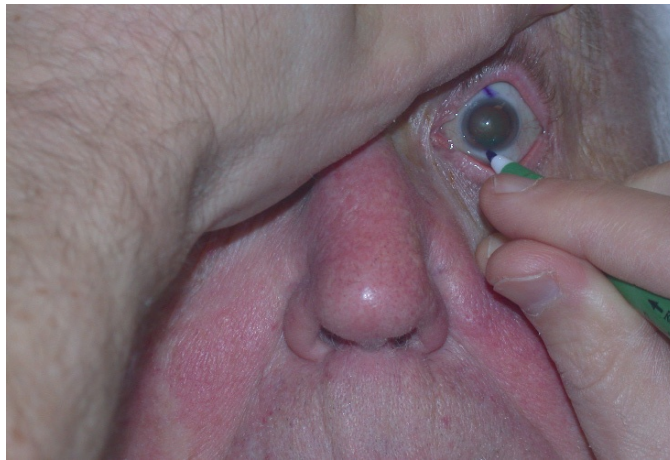

Fig. 5.8 Preoperative marking of reference axis in sitting position

axis will indicate this. The TIOL axis can now be easily marked in relation to the reference axis' rotation with, e.g., a TABO marker (see Figs. 5.9 and 5.10).

3. Implantation technique does not differ from implanting spherical IOL in most TIOL. Figure 5.10e shows a wound-assisted implantation technique with an injector system (Lens: AcrySof SN60TT; Injector system: Monarch II with C cartridge). Just the final alignment of TIOL (Fig. 5.10f) markings needs to be ensured. For optimal final alignment the lens is aligned in a range of -5° . After this gross alignment,

the optical viscoelastic device (OVD) is removed and the lens is aligned to its final position. These steps are necessary to avoid rotations of the lens caused by OVD removal. Figure 5.11 shows two different TIOL alignment marks in vivo. It is important to know how the specific IOL manufacturer marks its lenses. Note that markings both in the steep meridian and in the flat meridian are possible!

Different kinds of axis markers are available today (Fig. 5.11), which allow a correct positioning of TIOL postoperatively (Figs. 5.12 and 5.13).

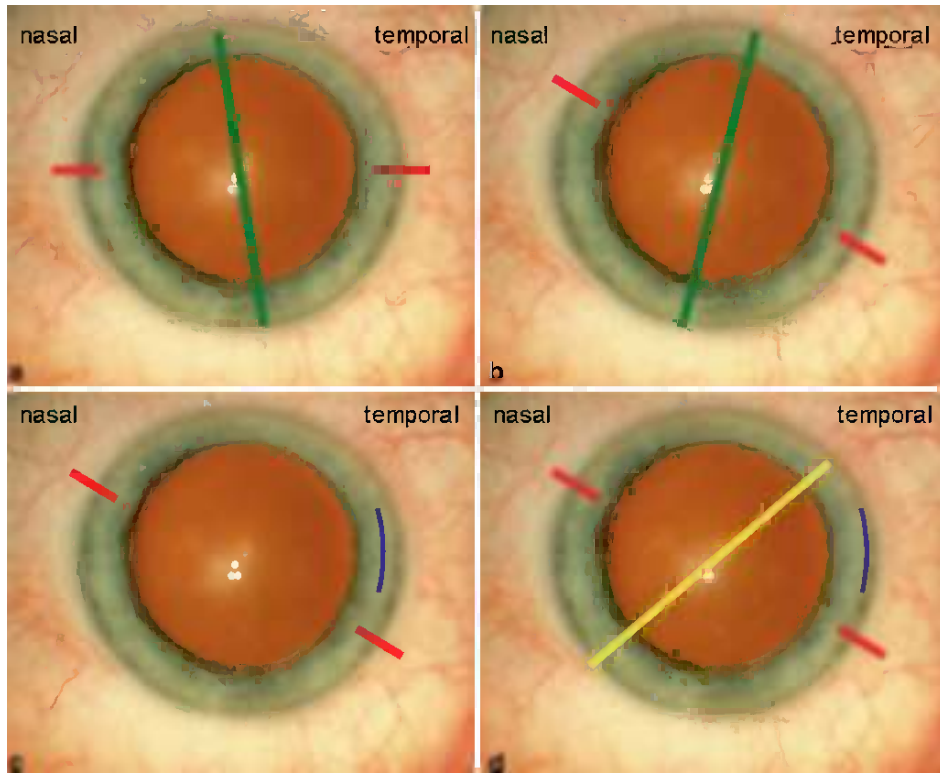


Fig. 5.9 Principle of TIOL alignment. (a) Axis of preexisting corneal cylinder (*green*) and surgeon's 0–180° reference marks (*red*) in sitting position, (b) patient changed to supine position, (c) incision location (*blue*), (d) axis of postoperative cylinder in supine position (*yellow*)

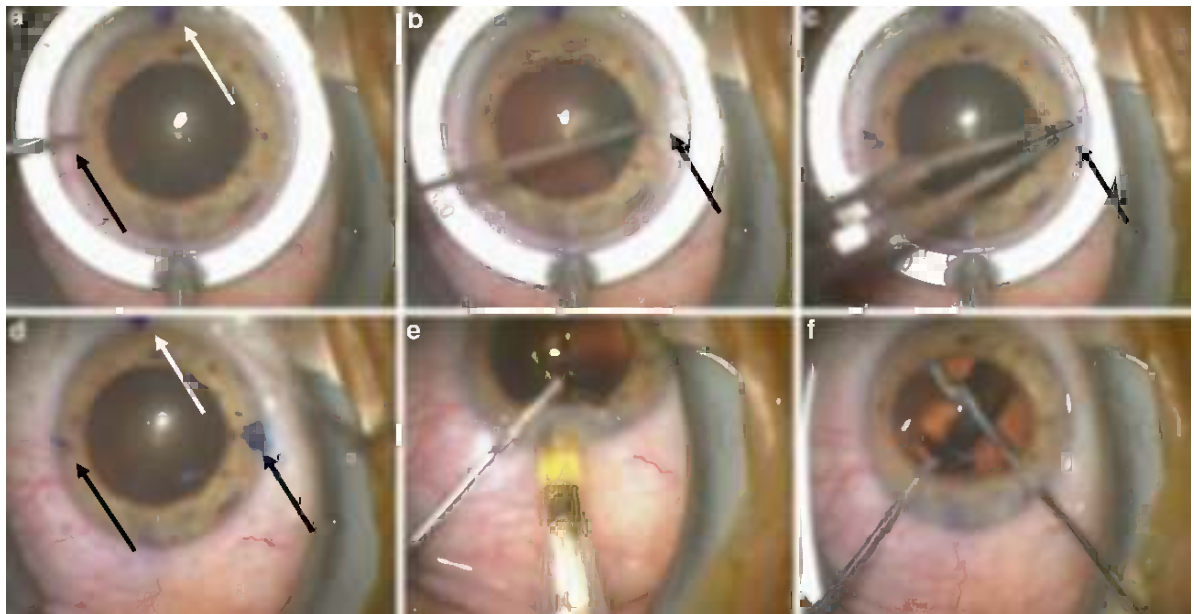


Fig. 5.10 Intraoperative TIOL marking and alignment; (a)–(c) Marking of the reference axis was done preoperative (*white arrow*) and axis markings (*black arrows*) are positioned relative to the occurring cyclorotation, (d) all markings are set, (e) TIOL implantation, (f) final bimanual alignment of the TIOL (this figure is not clear since we cannot really see how the TIOL is being aligned)

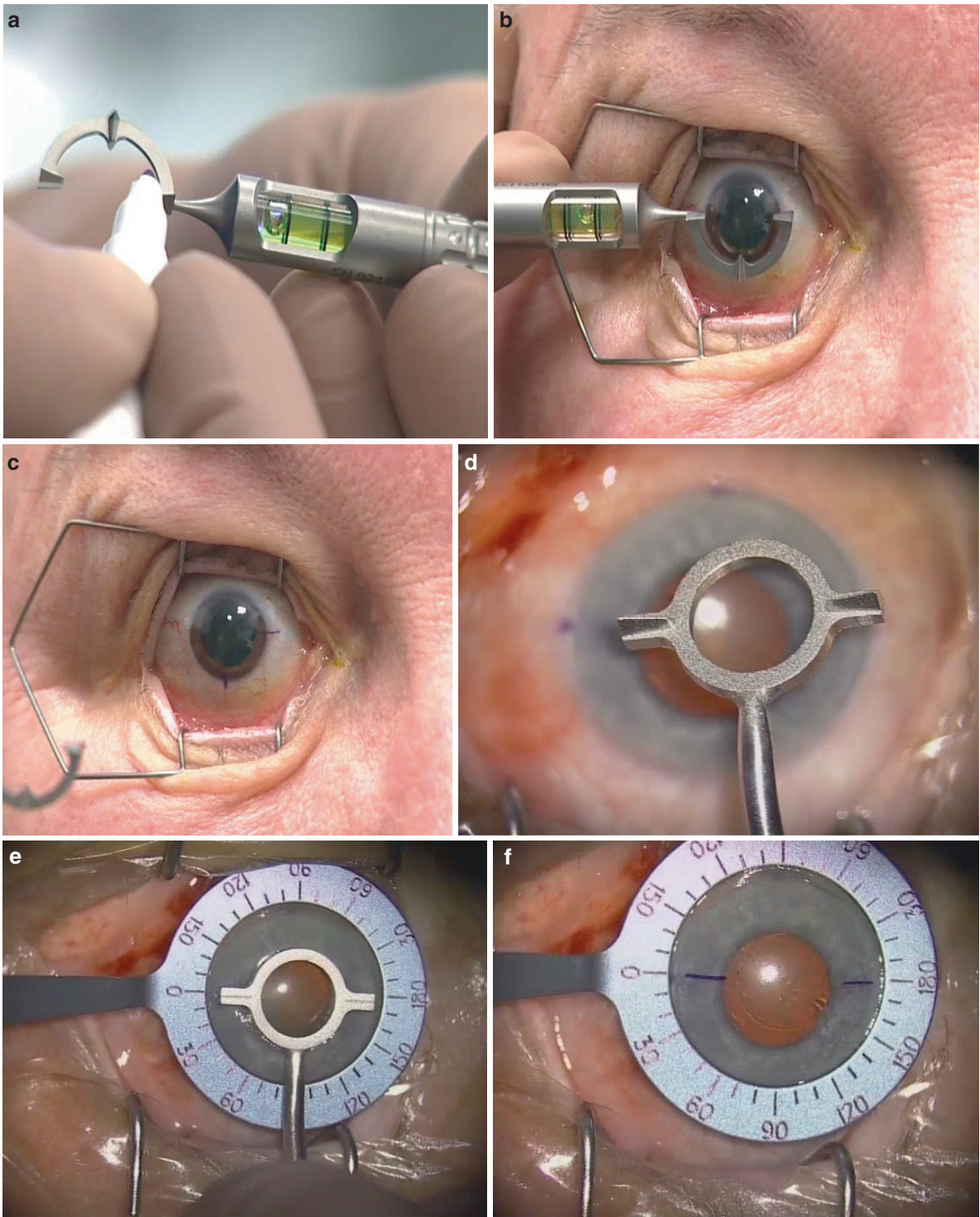


Fig. 5.11 Various axis markers. (a)–(c) Spirit level-supported marking process, (d)–(f) marking with an ASICO marker

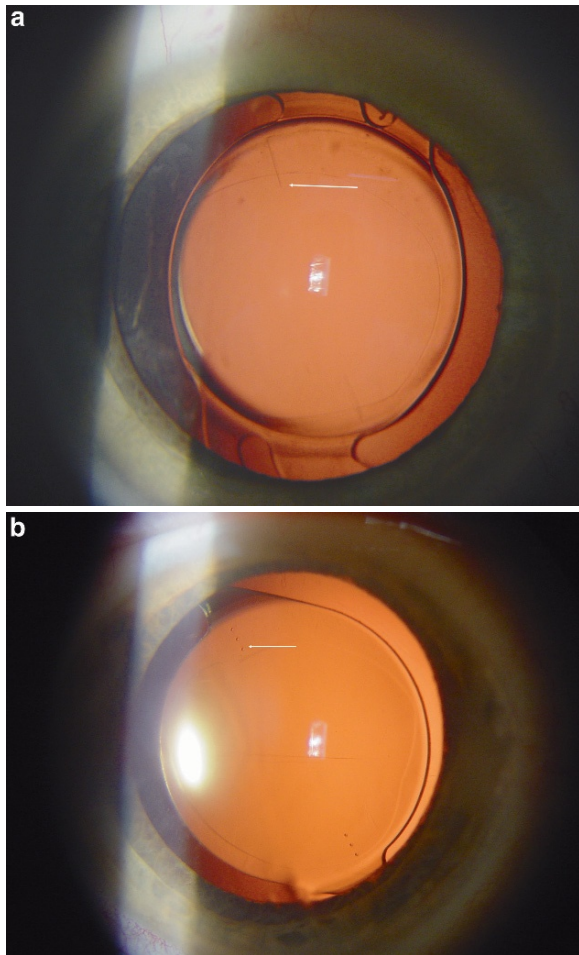


Fig. 5.12 Postoperative status of (a) Rayner TIOL and (b) Alcon TIOL; *white arrows* show the lenses' axis markings

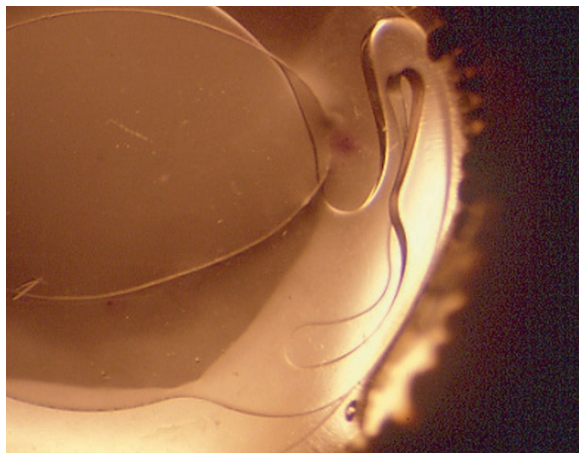


Fig. 5.13 Fixation of a TIOL in the bag (Rayner)

Another alignment method is the digital overlay technique [13, 19], which provides an preoperative-taken half transparent image of the eye to the operation microscope/operation monitor. This way, the surgeon can compare both pictures and does not have to mark a reference axis.

5.3.4 Follow-Up

The follow-up examinations are usually the same as for other spherical IOL, with a few additional requirements.

Subjective refraction control and topographic measurements should be performed. If possible, a photography in mydriasis should be taken in order to determine the TIOL's rotational stability. From such examinations it is easily possible to ascertain presence and origin of postoperative residual astigmatism. Possible origins are erroneous TIOL calculation, unexpected over-induced SIA, axis misalignment, or other (e.g., traumatic) reasons. In the first three cases, the IOL might be re-rotated. In the first two cases, value and direction of rotation can easily be calculated by a formula. If the TIOL is simply misaligned, correction is performed by rotating the lens to the preoperative planned position. If rotation is not possible or not wanted by the patient, refractive laser surgery can be performed.

5.4 Discussion

Table 5.1 and Fig. 5.14 provide a survey of the most common TIOL and their technical specifications. The following passages will give, in addition to Table 5.2, an overview of the current peer-reviewed literature's results of TIOL trials in terms of rotational stability, residual astigmatism, and visual acuity. Because some of the lenses mentioned in Table 5.1 have not yet been described in peer-reviewed literature, they are not included in Table 5.2.

5.4.1 Rotational Stability

TIOL gained rotational stability over the years since their first description in 1994. Shimizu et al. still showed very large amounts of rotation for the STAAR Toric three-piece IOL [12]; however, lens design was not sophisticated and surgeons had no experiences with TIOL. Newer versions of the STAAR Toric IOL with plate haptics showed better results [20–22]. With the introduction of the longer total diameter,

Table 5.1 Examples and technical specifications of different posterior chamber TIOLs for primary cataract surgery

TIOL	Manufacturer	Sph [D]	Cyl [D]	Oz [mm]	Optic design	Material	Total diameter [mm]	Implantation
MicroSil	Dr. Schmidt/	15–25 (0.5 steps)	2–12 (1.0 steps)	6.0	Spheric anterior and toric posterior surface (T-Y: blue light protection)	Hydrophobic MicroSil [®]	11.6	In-the-bag
MS6116TU/T-Y		-3 to 14 (1.0 steps)						
MicroSil		26–31 (1.0 steps)						
MS614T/T-Y	Humanoptics	15–25 (0.5 steps)	2–12 (1.0 steps)	6.0	Spheric anterior and toric posterior surface (Y: blue light protection)	Hydrophobic MicroSil [®]	14.0	Sulcus
Torica s/sY		-3 to 14 (1.0 steps)						
Torica s/sSY		26–31 (1.0 steps)						
T-Flex 573T	Rayner Surgical	-5.0 to 32.5 (0.5 steps)	1–11 (0.25 steps or 1.0 steps)	5.70	Toric anterior and spheric posterior surface	Hydrophilic Rayacryl	12.0	In-the-bag
T-Flex 623T				6.25			12.5	
Acri.Comfort	Carl Zeiss Meditec	-10 to 32 (0.5 steps)	1–12 (0.5 steps)	6.0	Bitoric	Foldable Acrylate with 25% water content, hydrophobic surface and UV-Absorber	11.0	In-the-bag
646TLC								
Acri.LISA toric		-10D to 32 (0.5 steps)	1–12 (0.5 steps)	6.0	Anterior surface toric, posterior diffractive surface, aberration-correcting, +3.75D addition, MICS, SMP-Technology			
466TD								
AA4203 TF	STAAR	21.5–28.5	2.0 and 3.5	6.0	Toric anterior and spheric posterior surface	Silicone	10.8	In-the-bag
AA4203 TL	Surgical	9.5–23.5	2.0 and 3.5				11.2	
SA60T3	Alcon Pharma	6–30 (0.5 steps)	1.5	6.0	Spheric anterior and toric posterior surface	Copolymer acrylate/methacrylate – hydrophobic acrylate with UV- and blue light filter	13.0	In-the-bag
SA60T4			2.25					
SA60T5			3					

Table 5.2 Survey on different clinical trials on TIOLs and main outcome measurements

TIOL	Author, year, reference	Number of eyes	Max. follow up	Rotational stability	Rerotation ratio [%]	Residual refractive astigmatism [D]	UCVA	BCVA
STAAR toric IOLs	Shimizu et al (1994) [12]	47	3 months	44.68% ≤ 30° 55.32% ≥ 30°	–	–	–	100% ≥ 20/40 77% ≥ 20/25
	Ruhswurm et al (1999) [20]	37	20.3 ± 19.6 months	18.9% ≤ 25° 100% ≤ 30°	18.92	0.84 ± 0.63	18.9% ≥ 20/20 67.5% ≥ 20/40	54% ≥ 20/20 91.8% ≥ 20/40
	Sun et al (2000) [21]	130	3 months	75% ≤ 20° 18% between 20 and 40°	11.32	1.03 ± 0.79	84% ≥ 20/40 69% ≥ 20/30	–
Alcon AcrySof SN60TT	Till et al (2002) [22]	100	23 weeks	7% ≥ 40° 62% ≤ 5° 27% between 5 and 15°	5	–	66% ≥ 20/40 45% ≥ 20/30	96% ≥ 20/40 85% ≥ 20/30
	Chang (2003) [23]	50 (TL)	1 month	14% ≥ 15° 72% ≤ 5° 90% ≤ 10° 98% ≤ 15° 2% = 20°	0	0.92 ± 0.87	7% ≥ 20/20 –	32% ≥ 20/20 92% ≥ 20/40
Dr.Schmidt MicroSil Toric/Humanoptics Toricá	Mendicute et al (2008) [24]	30	3 months	96% ≤ 10° 3.3% = 12°	0	–0.72 ± 0.34	93.3% ≥ 20/40 66.6% ≥ 20/25	100% ≥ 20/25
	Zuberbuhler et al (2008) [25]	44	3 months	95% ≤ 5° 68% ≤ 2°	0	–	–	0.01 ± 0.11 logMAR
	Dick et al (2006) [9]	68	3 months	85% ≤ 5° 15% ≥ 5°	8	1.12 ± 0.9	68% ≥ 20/40 12% ≥ 20/20	85% ≥ 20/40 31% ≥ 20/20
De Silva et al (2006) [26]	21	6 months	100% ≤ 15° 90% ≤ 10°	4.76	1.23 ± 0.9	0.23 ± 0.24 logMAR	0.23 ± 0.22 logMAR	

UCVA Uncorrected visual acuity; BCVA Best corrected visual acuity

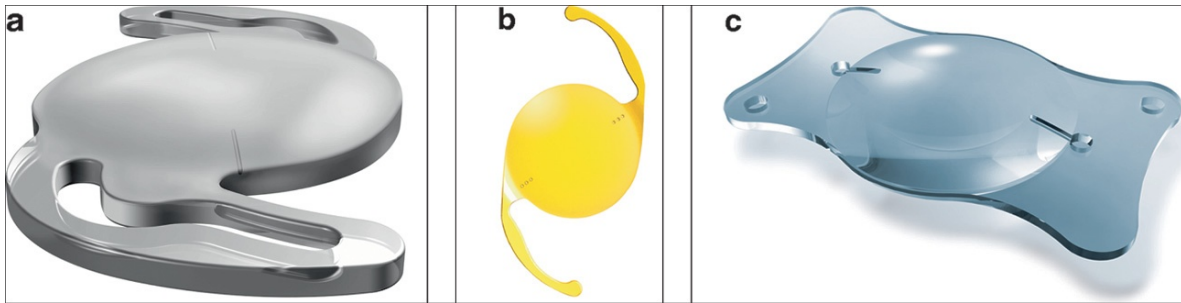


Fig. 5.14 Different TIOL for cataract surgery; (a) Rayner T-flex, (b) Alcon SN60TT, (c) Carl Zeiss Meditec Acri. LISAtoric

repositioning rate decreased to 0% in 2003 [23]. The MicroSil Z-haptics series by Dr.Schmidt (also known as Humanoptic's Torica) also show very low repositioning rates of 4.76% [26] to 8% [9] of lenses. Alcon's SN60TT series showed no need for repositioning at all [24, 25], no matter which lens of the series was implanted. Overall rotation was least with those lenses compared to the other trials.

5.4.2 Residual Astigmatism

In all clinical trials, residual astigmatism after implantation of TIOL seems to be nearly the same. It levels off at about 1.00 D. However, Mendicute [24] and Ruhswurm [20] showed the smallest residual astigmatism with two lenses of different generations (STAAR Toric IOL and Alcon SN60TT). Largest residual astigmatism was measured with the MicroSil lenses [9, 26]

5.4.3 Visual Acuity

Because of the better correction of astigmatism, the visual acuity after TIOL implantation can be evaluated in much higher values than this was possible before. Uncorrected visual acuity (UCVA) reaches levels of 20/40 between 66% (STAAR TF) and 93.3% (Alcon SN60TT). Best corrected visual acuity (BCVA) is better than 20/40 in nearly all cases, from 85% with MicroSil Lenses to even 100% with Shimizus first STAAR toric IOL. However, modern lenses also achieve larger visual acuities. The best results so far are described with the Alcon lens with 66.6% of UCVA \geq 20/25 and 100% BCVA \geq 20/25.

Summary for the Clinician

Due to their excellent functional outcomes and according to high patient satisfaction, TIOL are becoming more and more popular. Today, manufacturers' TIOL series deliver excellent clinical outcomes. Also, most manufacturers are currently investigating innovative new TIOL designs, so that in the future results are expected to get even better. In summary, modern TIOL are a safe, effective, predictable, and stable way to correct pre-existing astigmatism in cataract surgery.

References

1. Hoffer KJ (1980) Biometry of 7,500 cataractous eyes. *Am J Ophthalmol* 90:360–368
2. Bartels MC, Saxena R, van den Berg TJ, van Rij G, Mulder PG, Luyten GP (2006) The influence of incision-induced astigmatism and axial lens position on the correction of myopic astigmatism with the Artisan toric phakic intraocular lens. *Ophthalmology* 113:1110–1117
3. Kohnen T, Kasper T (2005) Incision sizes before and after implantation of 6-mm optic foldable intraocular lenses using Monarch and Unfolder injector systems. *Ophthalmology* 112:58–66
4. Beltrame G, Salvetat ML, Chizzolini M, Driussi G (2001) Corneal topographic changes induced by different oblique cataract incisions. *J Cataract Refract Surg* 27:720–727
5. Wang L, Misra M, Koch DD (2003) Peripheral corneal relaxing incisions combined with cataract surgery. *J Cataract Refract Surg* 29:712–722

6. Buchwald HJ, Lang GK (2004) [Cataract surgery with implantation of toric silicone lenses for severe astigmatism after keratoplasty]. *Klin Monatsbl Augenheilkd* 221:489–494
7. Sauder G, Jonas JB (2003) Treatment of keratoconus by toric foldable intraocular lenses. *Eur J Ophthalmol* 13:577–579
8. Auffarth GU, Rabsilber TM (2007) [Toric IOLs after cataract surgery and refractive lens exchange]. *Ophthalmologie* 104:1024–1031
9. Dick HB, Krummenauer F, Trober L (2006) [Compensation of corneal astigmatism with toric intraocular lens: results of a multicentre study]. *Klin Monatsbl Augenheilkd* 223:593–608
10. Horn JD (2007) Status of toric intraocular lenses. *Curr Opin Ophthalmol* 18:58–61
11. This picture has been taken from the article “Toric intraocular lenses and correction of astigmatism” published in *Der Ophthalmologie* (11) *Ophthalmologie* 104:620–627, modified and translated
12. Shimizu K, Misawa A, Suzuki Y (1994) Toric intraocular lenses: correcting astigmatism while controlling axis shift. *J Cataract Refract Surg* 20:523–526
13. Viestenz A, Seitz B, Langenbucher A (2005) Evaluating the eye’s rotational stability during standard photography: effect on determining the axial orientation of toric intraocular lenses. *J Cataract Refract Surg* 31:557–561
14. Kohnen T, Knorz MC, Neuhann T (2007) [Evaluation and quality assurance of refractive surgery procedures by the German Ophthalmological Society and the Professional Association of German Ophthalmologists]. *Ophthalmologie* 104:719–726
15. Bafna S, Kohnen T, Koch DD (1998) Axial, instantaneous, and refractive formulas in computerized videokeratography of normal corneas. *J Cataract Refract Surg* 24:1184–1190
16. Hill W (2008) Expected effects of surgically induced astigmatism on AcrySof toric intraocular lens results. *J Cataract Refract Surg* 34:364–367
17. Gills J, Van der Karr M, Cherchio M (2002) Combined toric intraocular lens implantation and relaxing incisions to reduce high preexisting astigmatism. *J Cataract Refract Surg* 28:1585–1588
18. Fam HB, Lim KL (2007) Meridional analysis for calculating the expected spherocylindrical refraction in eyes with toric intraocular lenses. *J Cataract Refract Surg* 33:2072–2076
19. Nguyen TM, Miller KM (2000) Digital overlay technique for documenting toric intraocular lens axis orientation. *J Cataract Refract Surg* 26:1496–1504
20. Ruhswurm I, Scholz U, Zehetmayer M, Hanselmayer G, Vass C, Skorpik C (2000) Astigmatism correction with a foldable toric intraocular lens in cataract patients. *J Cataract Refract Surg* 26:1022–1027
21. Sun XY, Vicary D, Montgomery P, Griffiths M (2000) Toric intraocular lenses for correcting astigmatism in 130 eyes. *Ophthalmology* 107:1776–1781; discussion 1781–1772
22. Till JS, Yoder PR Jr, Wilcox TK, Spielman JL (2002) Toric intraocular lens implantation: 100 consecutive cases. *J Cataract Refract Surg* 28:295–301
23. Chang DF (2003) Early rotational stability of the longer Staar toric intraocular lens: fifty consecutive cases. *J Cataract Refract Surg* 29:935–940
24. Mendicute J, Irigoyen C, Aramberri J, Ondarra A, Montes-Mico R (2008) Foldable toric intraocular lens for astigmatism correction in cataract patients. *J Cataract Refract Surg* 34:601–607
25. Zuberbuhler B, Signer T, Gale R, Haefliger E (2008) Rotational stability of the AcrySof SA60TT toric intraocular lenses: a cohort study. *BMC Ophthalmol* 8:8
26. De Silva DJ, Ramkissoon YD, Bloom PA (2006) Evaluation of a toric intraocular lens with a Z-haptic. *J Cataract Refract Surg* 32:1492–1498

Wavefront-Modified IOLs

Li Wang, Elizabeth Yeu, Douglas D. Koch

Core Messages

- Nearly all virgin human corneas have positive spherical aberration. Traditional spherical intraocular lenses (IOLs) also have positive spherical aberration, thereby adding to the positive spherical aberration of the cornea. Several IOLs with negative and zero spherical aberration have been proposed to partially or fully compensate for the positive SA of the cornea. The SA of available aspheric designs ranges from 0 to $-0.27\ \mu\text{m}$.
- There is a wide range of corneal spherical aberration in the population, and other higher-order corneal aberrations interact variably with spherical aberration to increase or decrease optical performance. For a 6-mm pupil, the optimal IOL SA varies widely in normal eyes and to an even greater extent in eyes that have undergone myopic and hyperopic PRK or LASIK, and can be predicted based on other HOAs of the cornea. The formulas are provided for making these calculations.
- The primary aberration introduced by decentration of an IOL with positive or negative asphericity is coma. For a 6-mm pupil, depending upon the optical model used, aspheric IOLs provide better image quality with decentration of 0.5–1.0 mm than SA-free and positive SA IOLs. With current technology, mean IOL centration has been reported to be within 0.1–0.3 mm. Therefore, the IOLs with negative SA should provide better optical quality than spherical aberration-free lenses and standard IOLs in the majority of patients.
- Theoretical studies and clinical investigations suggest, for some patients, there is slightly greater depth of focus for spherical IOLs and IOLs with no spherical aberration compared to an IOL with asphericity of $-0.27\ \mu\text{m}$.
- Clinically, aspheric IOLs improve contrast sensitivity and the quality of vision. They have less spherical aberration, which can improve visual clarity but may reduce the depth of focus. Subjectively, some patients prefer their vision from their aspheric IOL over the spherical IOL. More importantly, the quality of vision from aspheric IOLs can increase functional daily activities. Driving simulation studies have shown that the vision provided through a Tecnis IOL translates to significantly quicker reaction stop time when encountering pedestrians.

6.1 Introduction

The introduction of wavefront technology in ophthalmology has provided important insights on the effect of cataract and refractive surgery on the optical properties of the eye. In the field of cataract surgery, a primary area of interest has been the role of spherical aberration on modifying quality of vision. Positive spherical aberration occurs in an optical system when marginal rays are focused in front of paraxial rays (Fig. 6.1). Nearly all virgin human corneas have positive spherical aberration. Traditional spherical intraocular lenses (IOLs) also have positive spherical aberration, thereby adding to the positive spherical aberration of the cornea. Aspheric IOLs

with negative spherical aberration have been designed to compensate for the positive spherical aberration in the cornea. This chapter will discuss a range of topics regarding aspheric IOLs, including types that are currently available, custom selection, effect of decentration, impact on depth of focus, and clinical outcomes.

6.2 Aspheric IOLs

6.2.1 Corneal Spherical Aberrations

Using the polynomial decomposition, corneal height maps measured by computerized videokeratoscopes have been used to determine wavefront aberrations of the

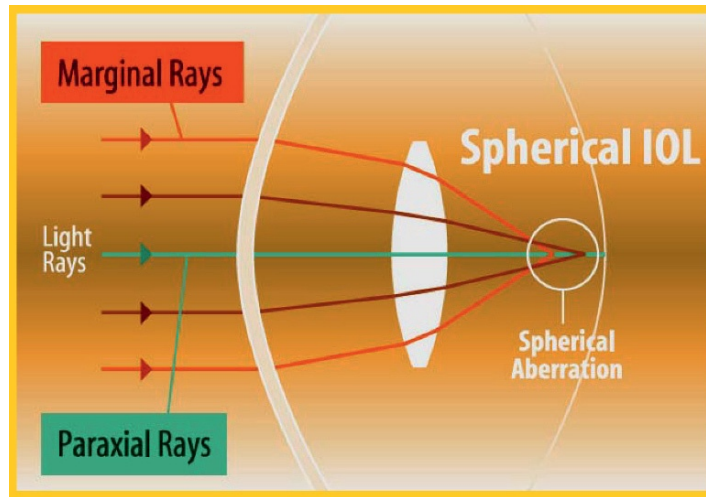


Fig. 6.1 Positive SA occurs when marginal rays focus in front of paraxial rays

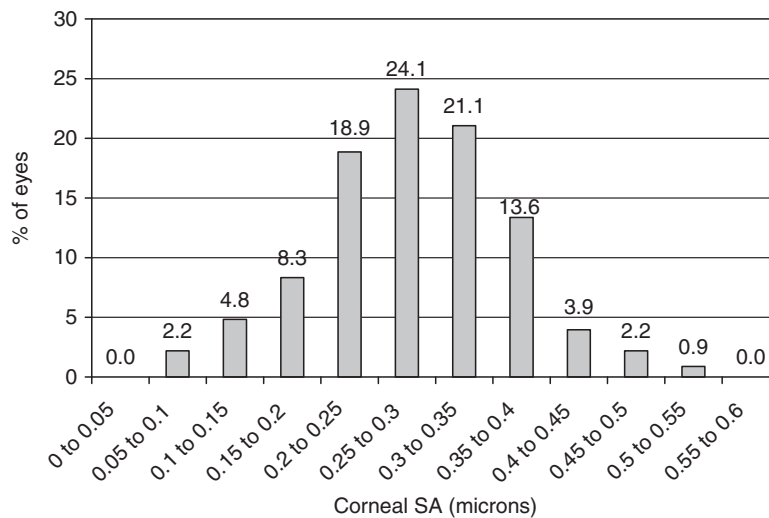


Fig. 6.2 Distribution of corneal spherical aberration (Z_4^0) in 228 eyes

anterior corneal surface [1–3]. Mean corneal spherical aberration of normal corneas is around $+0.27\mu\text{m}$ for a 6-mm pupil [4–6].

In a previous study, we investigated the distribution of anterior corneal higher-order aberrations (HOAs) in the population [7]. In 228 eyes, we found that there was wide individual variability in corneal aberrations. Of all higher-order Zernike terms up to sixth-order, fourth-order spherical aberration (SA) had the highest absolute values. Mean SA was $+0.280 \pm 0.086\mu\text{m}$ (range $0.055\text{--}0.544\mu\text{m}$) for a 6-mm pupil. Twenty-four

percent of eyes had corneal SA of $0.25\text{--}0.30\mu\text{m}$, followed by 21% of $0.30\text{--}0.35\mu\text{m}$, and 18.9% of $0.20\text{--}0.25\mu\text{m}$ (Fig. 6.2).

6.2.2 Aspheric IOLs

Several IOLs with negative and zero asphericity have been designed with the goal of improving on quality of vision produced by a standard IOL with positive SA. The Tecnis IOL from Advanced Medical Optics (AMO) was the first

aspheric intraocular lens to be marketed. Since then, several other IOLs with different amounts of asphericity have been introduced. These include:

- Tecnis IOL (AMO): The Tecnis IOL has SA of $-0.27\ \mu\text{m}$ for a 6-mm pupil and is designed to leave the “average” eye with no SA (Fig. 6.3). The Tecnis multifocal is a diffractive multifocal IOL that also has SA of $-0.27\ \mu\text{m}$.
- AcrySof IQ IOL (Alcon Laboratories): The AcrySof IQ IOL has negative asphericity of $-0.20\ \mu\text{m}$ for a 6-mm pupil, leaving a small amount of ocular positive SA for the average eye (Fig. 6.4).
- Aspheric Restor (Alcon Laboratories): This diffractive multifocal IOL has $-0.10\ \mu\text{m}$ of negative asphericity.
- SofPort AO/Akreos AO (Bausch & Lomb): The SofPort AO/Akreos AO lens has no spherical aberration, leaving the average eye with the naturally occurring positive SA from the cornea (Fig. 6.5).

- Afinity (STAAR): This IOL has a very small amount of negative asphericity (essentially zero) and, like the SofPort, is designed to leave the eye with the SA induced by the cornea.

Summary for the Clinician

- The human cornea has positive spherical aberration on average of $+0.27\ \mu\text{m}$ for a 6-mm pupil.
- Corneal spherical aberration varies widely among subjects, ranging in one study from 0.055 to $0.544\ \mu\text{m}$ for a 6-mm pupil.
- Aspheric IOLs with various amounts of spherical aberration have been proposed to partially or fully compensate for the positive SA of the cornea.
- The SA of available aspheric designs ranges from 0 to $-0.27\ \mu\text{m}$.

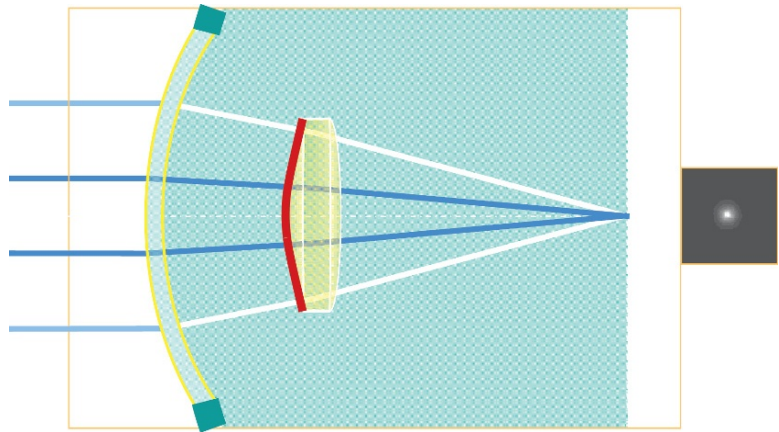


Fig. 6.3 The Tecnis lens compensates for the average corneal spherical aberration

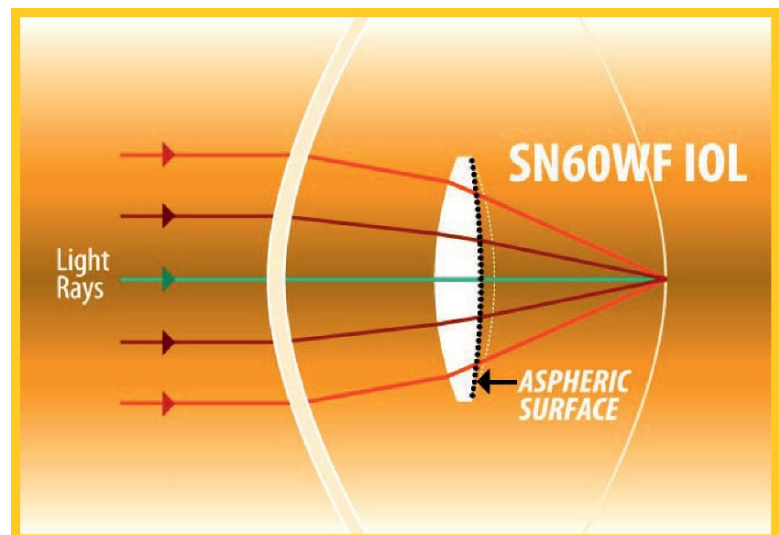
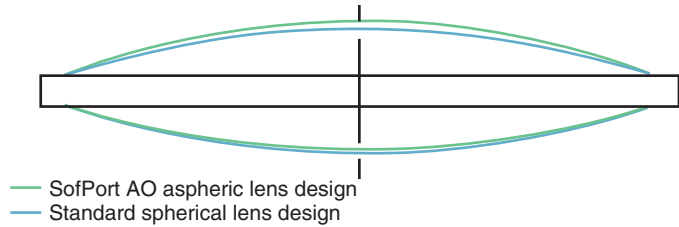


Fig. 6.4 Alcon AcrySof IQ IOL (SN60WF) surface design

Fig. 6.5 SofPort AO aspheric lens design

6.3 Custom Selection of Aspheric IOLs

There are two primary reasons to customize the asphericity of the IOL for each eye:

1. There is a wide range of corneal spherical aberration in the population (Fig. 6.2). Assuming implantation of Tecnis lens, AcrySof IQ lens, SofPort AO lens, and standard IOL with positive SA ($SA = +0.18 \mu\text{m}$) in the eyes in this figure, the residual ocular SA would have wide ranges: -0.215 to $0.274 \mu\text{m}$ for eyes with Tecnis lens, -0.145 to $0.344 \mu\text{m}$ for eyes with AcrySof IQ lens, 0.055 – $0.544 \mu\text{m}$ for eyes with SofPort AO lens, and 0.235 – $0.724 \mu\text{m}$ for eyes with standard IOL.
2. Other higher-order corneal aberrations interact variably with spherical aberration to increase or decrease

optical performance [8]. It is well known that other HOAs exist in the human cornea and that HOAs vary widely among subjects [7]. Aberrations in different Zernike terms interact to increase or decrease optical performance [9].

6.3.1 Custom Selection of Aspheric IOLs in Normal Eyes

In a previous study, we investigated the optimal amounts of ocular SA and IOL SA needed to maximize optical image quality in normal eyes [8]. We found that, for a 6-mm pupil, the majority of eyes had best image quality at small amounts of negative ocular SA (-0.10 to $0.00 \mu\text{m}$) with range from -0.30 to $+0.20 \mu\text{m}$ (Fig. 6.6). The optimal IOL

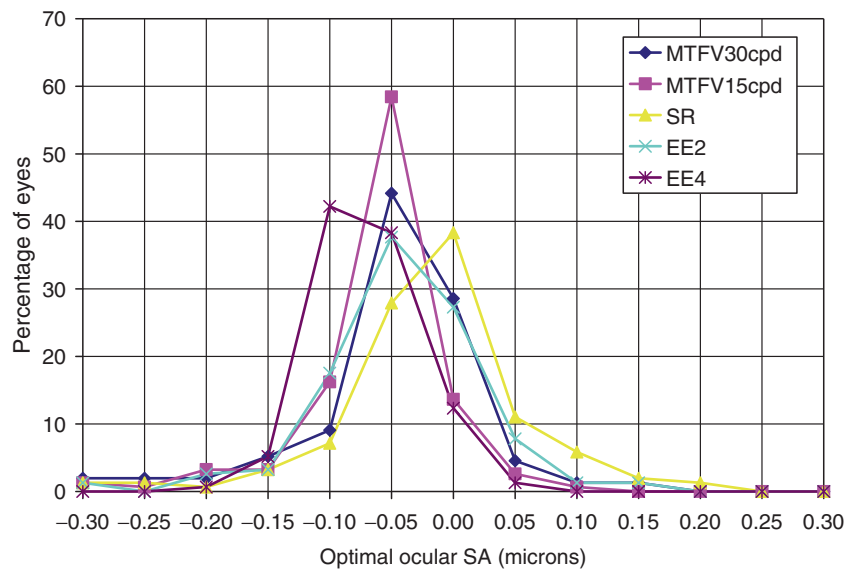


Fig. 6.6 In normal eyes, distribution of optimal ocular spherical aberration (SA, C_4^0) to produce best image quality for a 6-mm pupil as evaluated by modulation transfer function volume up to 30 cycles/degree (MTFV30cpd), MTF volume up to 15 cycles/degree (MTFV15cpd), Strehl ratio (SR), Encircled Energy at 2 arc minutes (EE2), and Encircled Energy at 4 arc minutes (EE4)

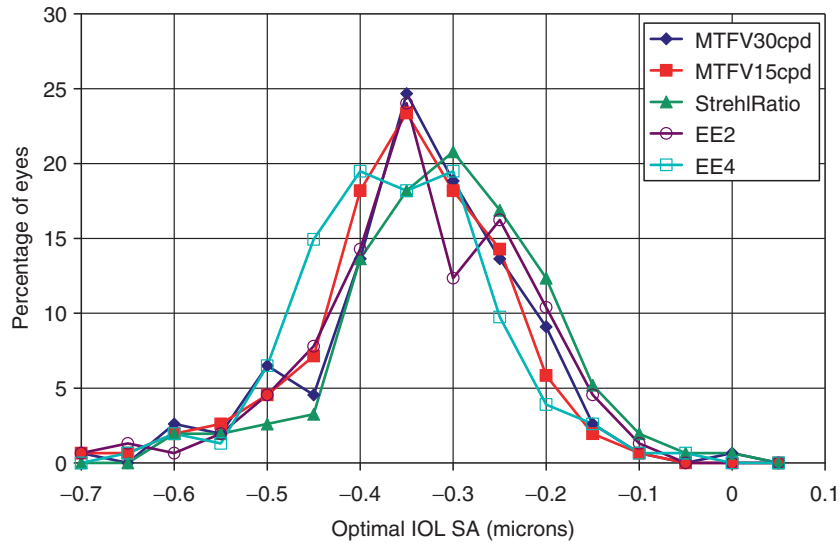


Fig. 6.7 In normal eyes, distribution of optimal intraocular lens spherical aberration (SA, C_4^0) to produce best image quality for a 6-mm pupil as evaluated by modulation transfer function volume up to 30 cycles/degree (MTFV30cpd), MTF volume up to 15 cycles/degree (MTFV15cpd), Strehl ratio (SR), Encircled Energy at 2 arc minutes (EE2), and Encircled Energy at 4 arc minutes (EE4)

SA varied widely among eyes for a 6-mm pupil, ranging from -0.70 to $0.00 \mu\text{m}$ (Fig. 6.7). Surprisingly, the mean IOL SA to maximize image quality was $-0.35 \mu\text{m}$. The IOL SA values that provided optimal visual quality in at least 10% of eyes were -0.45 to $-0.20 \mu\text{m}$. Using SA increments of $0.05 \mu\text{m}$, no single value of IOL SA produced optimal image quality in more than one out of four eyes, suggesting that optimizing SA for patients will require a range of IOLs with different amounts of SA.

For a 4-mm pupil, most eyes had a best image quality at an ocular SA of -0.05 to $+0.05 \mu\text{m}$. Using SA increments of $0.05 \mu\text{m}$, single values of IOL SA produced optimal image quality in 48–60% of eyes. Thus, pupil size is a critical variable when assessing the visual benefit of reducing ocular spherical aberration. In eyes with normal ranges of spherical aberration, steps to modulate spherical aberration will minimally affect quality of vision if the pupil size is below 4 mm.

Using the stepwise multiple regression analysis, we found that the amount of optimal IOL SA for a 6-mm pupil could be predicted based on other HOAs of the cornea with multiple correlation coefficient R values of 0.928–0.952. The fourth-order SA (Z_4^0) made the greatest contribution followed by the sixth-order SA (Z_6^0).

Once the corneal aberrations are known, the following formula can be used to predict the optimal IOL SA for a 6-mm pupil:

$$\text{Optimal IOL SA} = -0.988C_4^0 + 1.536C_6^0 - 0.186C_4^2 + 0.275C_6^2 + 0.214C_5^1 - 0.068$$

where C_4^0 and C_6^0 are coefficients of fourth-order and sixth-order SA, respectively, using the standards for calculating and reporting the wavefront aberrations.

To obtain corneal wavefront aberrations, there are two options. Some topographic devices on the market calculate and display corneal wavefront aberrations. For other devices, one can export their data into the VOL-CT program (<http://saavision.com>). This program allows users to import corneal topographic data from various corneal topographers to calculate corneal wavefront aberrations.

6.3.2 Custom Selection of Aspheric IOLs in Eyes Following Myopic-PRK

In another study (presented at American Society of Cataract and Refractive Surgery, April 3–9, 2008, Chicago, IL), we investigated the optimal amounts of ocular SA and IOL SA needed to maximize optical image quality in eyes following wavefront-guided myopic photorefractive keratectomy (PRK). We found greater variability than in normal eyes, with the optimal IOL SA ranging from -1.00 to $0.10 \mu\text{m}$ (Fig. 6.8). The mean IOL SA to maximize image quality was $-0.45 \mu\text{m}$. Thus, due to the positive SA induced by the myopic-PRK, more negative SA is required in this group of eyes compared to normal eyes.

Stepwise multiple regression analysis revealed that the amount of optimal IOL SA for a 6-mm pupil could be predicted based on other HOAs of the cornea with multiple correlation coefficient R values of 0.907–0.988. Again,

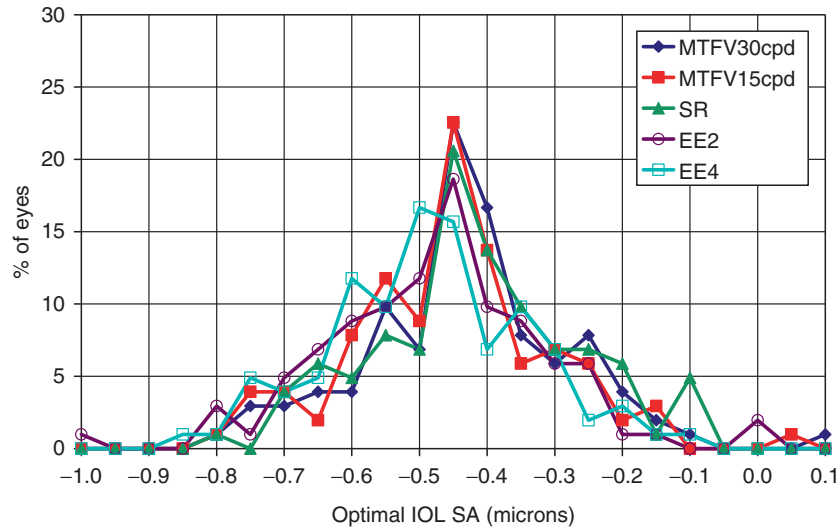


Fig. 6.8 In eyes following myopic-PRK, distribution of optimal intraocular lens spherical aberration (SA, C_4^0) to produce best image quality for a 6-mm pupil as evaluated by modulation transfer function volume up to 30 cycles/degree (MTFV30cpd), MTF volume up to 15 cycles/degree (MTFV15cpd), Strehl ratio (SR), Encircled Energy at 2 arc minutes (EE2), and Encircled Energy at 4 arc minutes (EE4)

the fourth-order SA (Z_4^0) made the greatest contribution, followed by the sixth-order SA (Z_6^0). The following formula could be used to predict the optimal IOL SA in eyes following myopic PRK for a 6-mm pupil:

$$\text{Optimal IOL SA} = -1.022 C_4^0 + 1.617 C_6^0 + 0.056 C_4^2 + 0.127 C_5^{-3} - 0.059$$

where C_4^0 and C_6^0 are coefficients of fourth-order and sixth-order SA, respectively, using the standards for calculating and reporting the wavefront aberrations.

6.3.3 Custom Selection of Aspheric IOLs in Eyes Following Hyperopic LASIK/PRK

We also investigated the optimal amounts of ocular SA and IOL SA needed to maximize optical image quality in eyes following hyperopic PRK and laser-assisted in situ keratomileusis (LASIK). This population showed much greater scatter in corneal SA than the normal eyes and the eyes following myopic PRK. In general, these corneas had less SA than a normal cornea. As a result, most eyes required small amounts of either of negative SA and positive SA in the IOL to achieve optimal optical quality (Fig. 6.9).

Stepwise multiple regression analysis revealed that the amount of optimal IOL SA for a 6-mm pupil could be predicted based on other HOAs of the cornea with multiple correlation coefficient R values of 0.898–0.980. Again, the fourth-order SA (Z_4^0) made the greatest contribution, followed by the sixth-order SA (Z_6^0). The following formula

could be used to predict the optimal IOL SA in eyes following hyperopic-LASIK/PRK for a 6-mm pupil:

$$\text{Optimal IOL SA} = -0.945 C_4^0 + 1.670 C_6^0 - 0.210 C_4^2 - 0.312 C_4^{-2} + 0.043 C_3^1 + 0.470 C_6^2 - 0.186 C_5^{-3} + 0.155$$

where C_4^0 and C_6^0 are coefficients of fourth-order and sixth-order SA, respectively, using the standards for calculating and reporting the wavefront aberrations.

Summary for the Clinician

- For a 6-mm pupil, the optimal IOL SA varied widely in normal eyes and to an even greater extent in eyes that had undergone myopic and hyperopic PRK or LASIK.
- The benefit of implanting an IOL that reduces spherical aberration is reduced as pupil size diminishes and is minimal at pupil sizes less than 4 mm.
- Due to wide individual variability in corneal HOAs in all three groups, several IOL designs with different amounts of SA are required to optimize image quality.
- The amount of optimal IOL SA for a 6-mm pupil can be predicted based on other HOAs of the cornea, and formulas are provided for making these calculations.
- The optical benefit of altering SA is greatly reduced as pupil size diminishes, becoming negligible at pupil size below 4 mm.

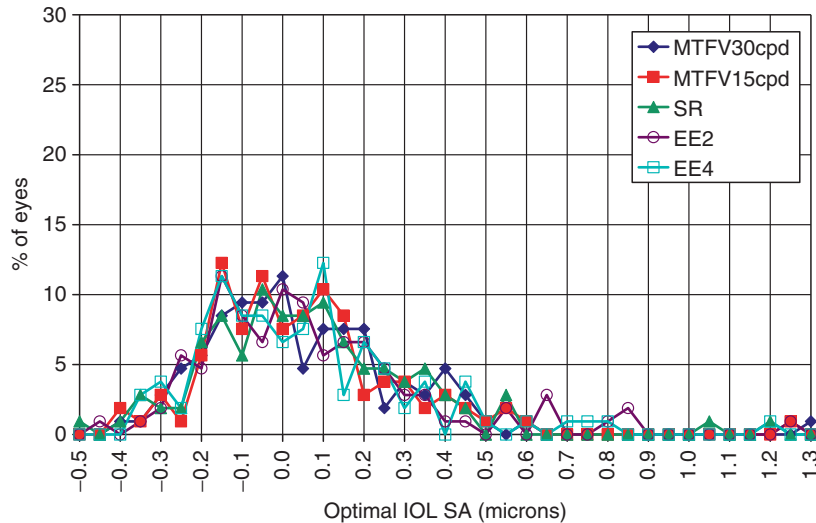


Fig. 6.9 In eyes following hyperopic-LASIK/PRK, distribution of optimal intraocular lens spherical aberration (SA, C_4^0) to produce best image quality for a 6-mm pupil as evaluated by modulation transfer function volume up to 30 cycles/degree (MTFV30cpd), MTF volume up to 15 cycles/degree (MTFV15cpd), Strehl ratio (SR), Encircled Energy at 2 arc minutes (EE2), and Encircled Energy at 4 arc minutes (EE4)

6.4 Decentration/Tilt of Aspheric IOL

An obvious concern with wavefront-modified IOLs is the required accuracy of the centration of the lens. The primary aberration introduced by decentration of an IOL with positive or negative asphericity is coma (Fig. 6.10) [10].

In a previous study, we evaluated the theoretical effect of decentration of aspheric IOLs on higher-order aberrations (HOAs, third to sixth-order) of the eye [10]. Simulated implantation of an aspheric IOL was performed in 154 eyes of 94 patients aged 40–80 years. The asphericity of the theoretically implanted IOL was $-0.287\mu\text{m}$, as it was designed to neutralize the mean corneal SA of this group. The aspheric IOL was laterally decentered up to 1 mm, and we calculated the residual ocular wavefront aberrations, which are the combination of the wavefront aberrations from the aspheric IOL and from the patient's cornea. We found that the average residual HOAs were smaller with the aspheric than the HOAs on the cornea if decentration was ≤ 0.5 mm. The residual ocular wavefront aberrations would equal the corneal HOAs if a spherical aberration free lens (SA = $0.00\mu\text{m}$) is implanted. This indicates that, with decentration ≤ 0.5 mm, an aspheric IOL with SA of $-0.287\mu\text{m}$ produces less residual ocular aberrations than spherical aberration-free lens. In this study, we did not evaluate the amount of decentration required for the aspheric IOL as superior to the standard IOL with positive SA.

Based on a model cornea designed to reproduce the measured average spherical aberration in 71 cataract patients, Holladay et al. [6] reported that an IOL with negative spherical aberration of $-0.27\mu\text{m}$ would exceed the optical performance of a conventional spherical IOL if centered within 0.4 mm and tilted less than 7° . This improvement occurred without an apparent loss in depth of focus.

The two previous studies were based on optical models using monochromatic light and no HOAs except for SA. Based on white light pseudophakic eye models constructed from physical measurements performed on 46 individual cataract patients, Piers and colleagues assessed the performance and optical limitations of standard, aspheric, and wavefront-customized IOLs [11]. They found that customized correction of ocular wavefront aberrations with an IOL results in contrast improvements of the order of 200% over the standard IOLs and the Tecnis IOLs. The customized lenses and the Tecnis lenses could, on average, be decentered by as much as 0.8 mm and tilted $>10^\circ$ before their polychromatic modulation transfer function at 8 cycles/degree is less than that of the spherical standard lens.

In a recent study, we investigated the effect of decentration on optical image quality with aspheric and standard IOLs (presented at the American Society of Cataract and Refractive Surgery, April 3–9, 2008, Chicago, IL). In 65 eyes of 43 patients with ages 40–80 years, we performed

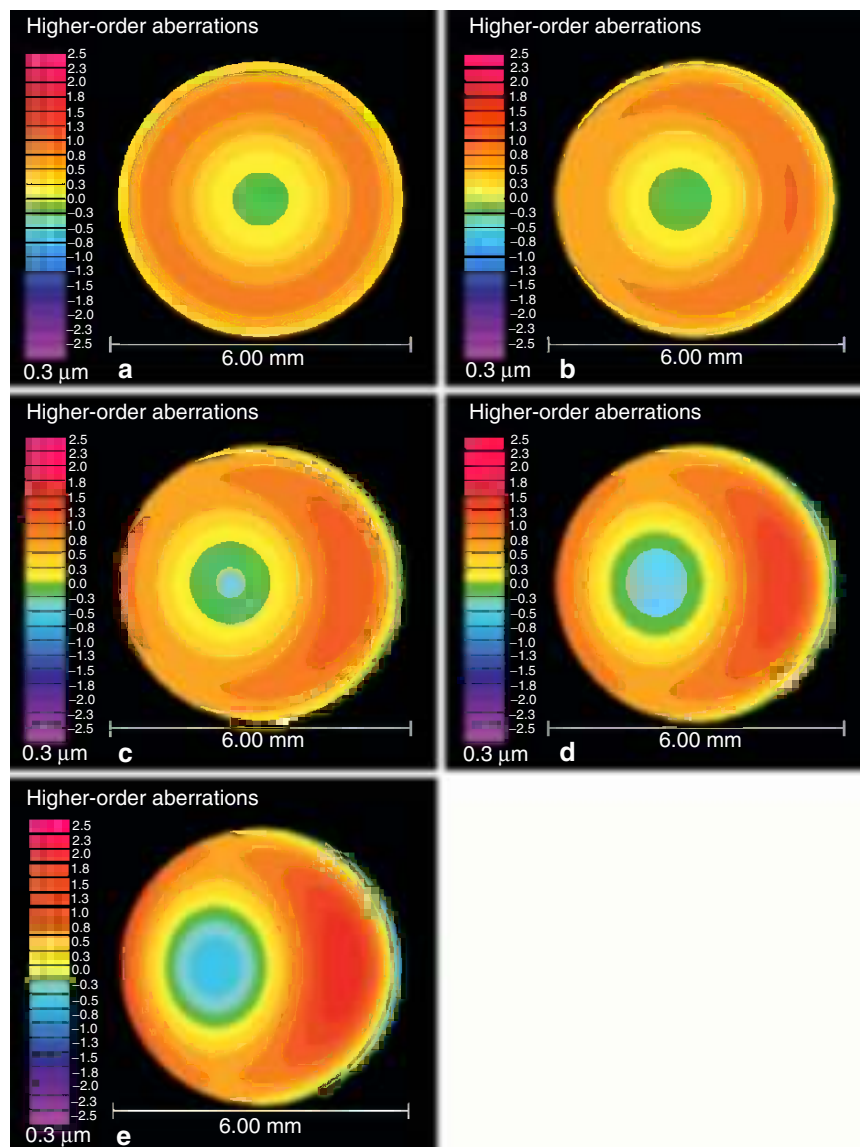


Fig. 6.10 An example of an aspheric intraocular lens with negative fourth-order spherical aberration ($-0.287\ \mu\text{m}$ for 6-mm pupil) (a). For horizontal decentration, the induced coma is $-0.152\ \mu\text{m}$ for 0.25 mm (b), $-0.304\ \mu\text{m}$ for 0.50 mm (c), $-0.457\ \mu\text{m}$ for 0.75 mm (d), and $-0.610\ \mu\text{m}$ for 1.00 mm (e)

simulated implantation of 5 IOLs in each eye: (1) customized aspheric IOL with the optimized IOL SA predicted using the formulas developed in previous study (Optimized IOL), (2) Tecnis IOL (SA = $-0.27\ \mu\text{m}$), (3) AcrySof IQ (SA = $-0.20\ \mu\text{m}$), (4) SofPort AO (SA = $0.00\ \mu\text{m}$), and (5) traditional spherical IOL (SA = $+0.18\ \mu\text{m}$) [8]. Simulations were performed for perfect IOL centration and horizontal decentration up to 1.00 mm. Using the ZernikeTool program (AMO), the polychromatic modulation transfer function (PMTF) with Stiles-Crawford effect was calculated to assess the optical image quality

(6- and 4-mm pupils). We found that, for a 6-mm pupil, the Optimized IOL produced higher PMTF values than the other four IOLs with decentration up to 0.25 mm. With decentration up to 1.00 mm, optical performance with the Optimized, Tecnis and IQ IOLs was superior to the AO and standard IOLs. For a 4-mm pupil, optical image qualities with the Optimized IOL, Tecnis, and IQ were significantly better than those with AO and standard IOL with decentration up to 0.25 mm.

With respect to the tilt of IOLs, as noted above, Piers and colleagues found that tilt must exceed 10° to reduce

visual quality of an aspheric IOL compared to a standard spherical lens [11]. What can be expected clinically? Although there are no published data to date clinically evaluating tilt of aspheric IOLs, studies of standard IOLs of similar design are valuable. Kohonen and associates observed no significant difference in postoperative tilt between the sharp-edged acrylic, sharp-edged silicone, or round-edged silicone IOLs ($2.32 \pm 1.41^\circ$, $2.34\text{--}3.03 \pm 1.81^\circ$, and $3.26 \pm 1.69^\circ$, respectively) [12]. This study also demonstrated that the postoperative tilt of all IOLs remained stable over its 12-month follow-up. Translating these results to aspheric IOLs, this minimal amount of tilt in uncomplicated cases should have little negative impact on the benefit to vision of reducing spherical aberration by implanting the appropriate aspheric IOL. Future clinical studies are necessary to further assess the effect of tilt on the performance of aspheric IOLs.

What can surgeons expect with regard to the accuracy of IOL centration? With continuous curvilinear capsulorhexis and in-the-bag IOL placement, mean IOL centration has been reported to be within 0.1–0.3 mm [13, 14]. Therefore, the optimized IOL and IOLs with negative SA should provide better optical quality than AO and standard IOLs in the majority of patients.

Summary for the Clinician

- Decentration of IOL with positive or negative SA induces coma.
- For a 6-mm pupil, depending upon the optical model used, aspheric IOLs provide better image quality with decentration of 0.5–1.0 mm than SA-free and positive SA IOLs.
- With current technology, mean IOL centration has been reported to be within 0.1–0.3 mm. The IOLs with negative SA should provide better optical quality than spherical aberration-free lenses and standard IOLs in the majority of patients.
- With current technology, IOL tilt is generally less than 3° . Such low levels of tilt are desirable in order for aspheric IOLs to provide their maximum refractive benefits. Further clinical studies are warranted to study the effect of IOL tilt on the performance of the various aspheric IOLs.

6.5 Depth of Focus with Aspheric IOLs

Studies have suggested that higher-order aberrations may contribute to greater depth of focus and that reducing or eliminating ocular SA may compromise this benefit.

Using an optical bench test with model corneas of various amount of SA (presented at the American Society of Cataract and Refractive Surgery, March 18–22, 2006, San Francisco, CA), we measured depth of defocus with 20.0 D of spherical (AcrySof SN60AT) and aspheric IOLs (AcrySof SN60WF). The results showed that elimination of SA could slightly decrease depth of focus.

As was noted in comparisons of studies evaluating the effect of decentration, studies of depth of focus show markedly different results depending upon whether the model includes monochromatic or polychromatic light and SA alone or other corneal HOAs. In a theoretical study using the ZernikeTool program (AMO), we simulated implantation of different IOLs to produce total ocular SA of +0.45, +0.27, 0.00, and $-0.20 \mu\text{m}$ [15]. The reduction in depth of focus from elimination of SA is minimal when evaluated with a polychromatic modulation transfer function with Stiles–Crawford effect in average cornea, compared to the much greater loss predicted with monochromatic light in a cornea with no other HOAs (Fig. 6.11) [7].

In the study by Piers and colleagues discussed in the previous section, for a 4-mm pupil the depth of focus was similar for Tecnis and standard spherical lenses [11]. Correction of all other wavefront aberrations resulted in a narrower through focus curve.

Jansonius and Kooijman studied the effect of spherical and other aberrations upon the modulation transfer of the defocused human eye [16]. They found that spherical aberration and other aberrations compromised modulation transfer at optimum focus; however, these aberrations increased the depth of focus. In a following study, Nio and colleagues confirmed that both spherical aberration and irregular aberrations increased the depth of focus, but decreased the modulation transfer at high spatial frequencies at optimum focus [17].

In eyes implanted with AcrySof spherical acrylic lens and Tecnis aspheric IOLs, Marcos et al. reported that the average optical depth-of-field, computed as the focus range for which Strehl ratio does not fall below 80% of the maximum, was 1.26 D for the spherical IOLs and 0.88 D for the aspheric lenses ($P = 0.0066$) [18].

In summary, aspheric IOLs may improve visual quality by reducing naturally occurring SA. However, it may be desirable to retain some SA to achieve an acceptable compromise with depth of focus. To determine the amount of optimal SA that should be left in the eye, interaction among Zernike terms, including higher-order and lower-order aberrations, should be considered. Further studies are desirable in this regard.

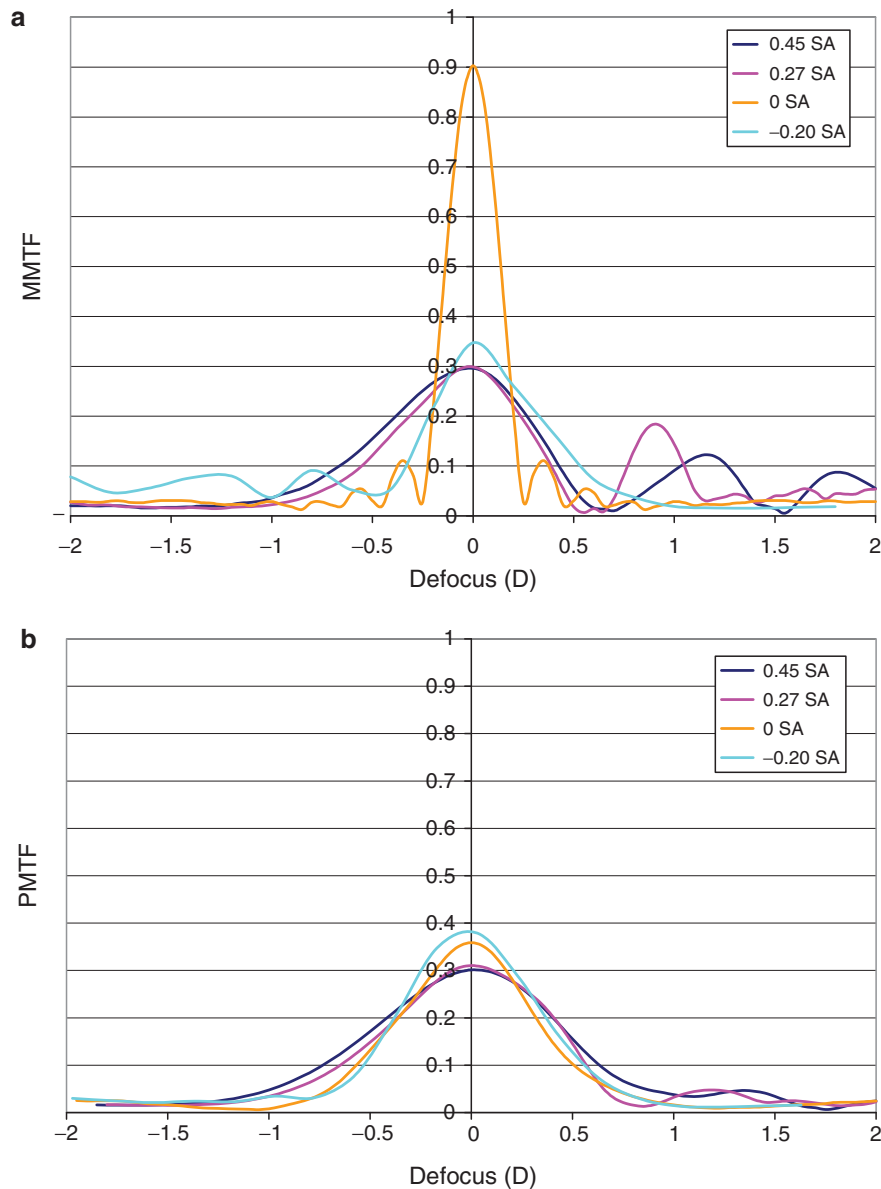


Fig. 6.11 With different IOLs to produce total ocular SA of $+0.45$, $+0.27$, 0.00 , and $-0.20 \mu\text{m}$, depth of focus based on monochromatic modulation transfer function at 15 cycles/degree (20/40 object) in perfect cornea (a), and on polychromatic modulation transfer function with Stiles-Crawford effect in average cornea (b)

Summary for the Clinician

- Theoretical studies suggest that elimination of SA could slightly decrease depth of focus.
- For some patients implanted with IOLs that do not accommodate, it may be desirable to retain some SA in order to increase depth of focus. Optimally, methods should be developed to predict depth of focus that a patient can achieve with various IOL designs.

6.6 Clinical Outcome of Aspheric IOLs

Multiple studies have been performed to evaluate the effect on vision of aspheric IOLs. Areas investigated have included spherical aberration (SA), contrast sensitivity, depth of focus, and activities of daily living.

- (1) *Spherical aberration.* Several studies have demonstrated that the Tecnis Z9000, Acrysof IQ, and Sofport aspheric IOLs consistently result in lower amounts of ocular SA than occurs following implantation of

standard spherical IOLs [5, 19, 20]. However, one study found that, although there was significantly less spherical aberration in eyes implanted with the Tecnis 9000 compared to the spherical Sensor AR40e, the small difference in SA between the two IOLs may not clinically affect contrast sensitivity [21].

- (2) *Quality of vision.* Most clinical studies have shown that aspheric IOLs result in improved contrast sensitivity and functional vision. Several have shown that the Tecnis provides superior contrast sensitivity in either mesopic or mesopic and photopic conditions [19, 22, 23]. In addition, Kershner and colleagues compared 221 eyes randomly assigned to receive either the Tecnis Z9000, Acrysof SA60AT, or the Staar conventional silicone plate IOL [24]. The Tecnis aspheric IOL provided statistically superior retinal image quality, as demonstrated by the comparison of the threshold luminance levels of fundus photographs. Regarding functional image contrast testing, the Tecnis aspheric IOL provided the greatest improvement under all lighting conditions. The conventional acrylic IOL provided improved contrast sensitivity under photopic conditions with glare and mesopic lighting conditions, while the conventional silicone IOL provided no change. The inferior performance of the silicone IOL may be due to an inherent property of the IOL material itself, as suggested by Tognetto and colleagues, who have demonstrated that the MTF through silicone material is lower than through an acrylic IOL [25]. However, two studies found no difference in contrast sensitivity between the Tecnis aspheric IOL and spherical IOLs [21, 26].

Regarding the Acrysof IQ SN60WF, three published series demonstrated that both photopic (at least at higher frequencies) and mesopic contrast sensitivities were significantly better compared to that achieved with spherical IOLs [5, 20, 27]. Regarding IOLs with zero asphericity, Caporossi and colleagues reported that the Sofport L161AO provided better photopic and mesopic contrast sensitivity compared to spherical IOLs [5]. However, they found no statistically significant differences in the contrast sensitivity among eyes implanted with the Tecnis, Acrysof IQ and Sofport IOLs.

- (3) *Depth of focus.* As was noted earlier in this chapter, the presence of some ocular SA may improve the depth of focus. Rocha and colleagues found that patients with the Acrysof SN60AT had statistically significant better distance-corrected intermediate and near visual acuity as compared to the IQ SN60WF [28]. The SN60AT provided approximately one line of improved distance-corrected intermediate vision (~20/40 vs ~20/50) and almost two lines of superior distance-corrected near visual acuity (~20/50 vs 20/65). In a study that evaluated aspheric IOLs, Johannson and colleagues reported that, compared to eyes implanted

with the Tecnis Z9000, eyes implanted with the Akreos Adapt Advanced Optics with zero SA lens had (1) more spherical aberration ($0.35 \pm 0.13 \mu\text{m}$ vs $0.05 \pm 0.13 \mu\text{m}$ RMS) and (2) greater depth of focus ($1.22 \pm 0.48 \text{ D}$ versus $0.86 \pm 0.50 \text{ D}$) [29].

- (4) *Activities of daily living.* Ultimately, subjective assessment of the quality of vision may be the most important clinical outcome, but we are aware of only two studies that assessed patients' perceptions with quality-of-vision questionnaires. Tzelikis and colleagues, in their study of 25 patients who randomly received one Tecnis aspheric IOL and one spherical ClariFlex IOL, reported that 42% of patients (12) preferred the vision out of the eye with the aspheric IOL, while 53% of patients (13) did not notice a difference in the vision of the two eyes [20]. Conversely, in the aforementioned intraindividual study comparing the Tecnis to the Akreos Adapt AO with zero SA, 28% of patients preferred the vision in the eye with the Akreos, compared to 14% with an eye implanted with the Tecnis [29]. Of note, 33% of the patients complained of experiencing greater visual disturbances in the eye implanted with the Tecnis as compared to 11% for the Akreos AO eye, which suggests that the minimizing spherical aberrations alone may not subjectively be interpreted as superior vision. Other factors such as edge design are obviously critical elements of patient satisfaction.

Perhaps the most compelling data supporting the benefit of aspheric IOLs are the driving simulation studies that were used to provide these IOLs with NTIOL status [30]. For the Tecnis lens, the Potomac Institute for Policy Studies performed two studies to evaluate the effect of implantation of the Tecnis lens on driving safety. Data for the study were generated by randomizing 60 eyes of 30 subjects to either the Tecnis or a standard IOL. The driving simulation study showed that patients viewing through a Tecnis lens identified a pedestrian significantly more quickly in a number of different conditions, including driving in the city with glare and in a real setting with or without glare. The patients implanted with a Tecnis lens were able to stop 0.5 s more quickly than those implanted with the standard IOL. This translated to a 45-foot (13.7 m) advantage at a speed of 55 mph (88.5 km/h). Remarkably, this exceeded the benefits gained by any of the recent changes that have been made in automobile lighting. For example, the greatest advance in lighting was the requirement for center high-mounted stop lamps, which provided a benefit of 0.35 s. Carrying this investigation further, the authors of the second study by the Potomac Institute concluded that, by 2010, the use of the Tecnis

lens could potentially save as much as US\$1 billion per year, and this does not take into account the actual injury or death from these accidents [31].

Summary for the Clinician

- Aspheric IOLs have less spherical aberration than spherical IOLs.
- Aspheric IOLs likely contribute to improved contrast sensitivity and functional vision.
- Clinical studies have shown slightly greater depth of focus with spherical IOLs and IOLs with no spherical aberration as compared to an IOL with asphericity of $-0.27\ \mu\text{m}$.
- Subjectively, patients may prefer their vision through aspheric IOLs over spherical IOLs. Reducing spherical aberration alone does not equate to superior vision, as some patients preferred vision through their zero-SA IOL over the $-0.27\ \mu\text{m}$ aspheric IOL.
- Driving simulation studies have demonstrated that patients with the Tecnis aspheric IOL are able to effectively identify pedestrians and stop 0.5 s quicker.
- Aspheric IOLs in general provide a superior quality of vision, but other factors contribute to patient perceptions, including refractive error, pupil size, positive and negative dysphotopsias, and depth of focus.

6.7 Conclusion

Several IOLs with negative and zero spherical aberration have been proposed to partially or fully compensate for the positive SA of the cornea. Due to the wide range of corneal spherical aberration in the population and interaction between Zernike terms, optimal IOL SA varied widely among eyes, especially in eyes that had undergone myopic and hyperopic LASIK/PRK. Therefore, custom selection of aspheric IOL is desirable. Although coma is induced by decentration of aspheric IOLs, studies have shown that, with current technology, the IOLs with negative SA should provide better optical quality than spherical aberration free lenses and standard IOLs in the majority of patients. Regarding the improved contrast sensitivity with the aspheric IOLs, although conflicting findings have been reported in the clinical studies, a night driving simulation study showed that patients implanted with a IOL with negative asphericity lens identified a pedestrian significantly more quickly in a number of different conditions.

References

1. Gobbe M, Guillon M, Maissa C (2002) Measurement repeatability of corneal aberrations. *J Refract Surg* 18:S567–S571
2. Guirao A, Artal P (2000) Corneal wave aberration from videokeratography: accuracy and limitations of the procedure. *J Opt Soc Am A Opt Image Sci Vis* 17:955–965
3. Schwiegerling J, Greivenkamp JE (1997) Using corneal height maps and polynomial decomposition to determine corneal aberrations. *Optom Vis Sci* 74:906–916
4. Beiko GH, Haigis W, Steinmueller A (2007) Distribution of corneal spherical aberration in a comprehensive ophthalmology practice and whether keratometry can predict aberration values. *J Cataract Refract Surg* 33(5):848–858
5. Caporossi A, Martone G, Casprini F, Rapisarda L (2007) Prospective randomized study of clinical performance of 3 aspheric and 2 spherical intraocular lenses in 250 eyes. *J Refract Surg* 23(7):639–648
6. Holladay JT, Piers PA, Koranyi G, van der Mooren M, Norrby NE (2002) A new intraocular lens design to reduce spherical aberration of pseudophakic eyes. *J Refract Surg* 18(6):683–691
7. Wang L, Dai E, Koch DD, Nathoo A (2003) Optical aberrations of the human anterior cornea. *J Cataract Refract Surg* 29(8):1514–1521
8. Wang L, Koch DD (2007) Custom optimization of intraocular lens asphericity. *J Cataract Refract Surg* 33(10):1713–1720
9. Applegate RA, Marsack JD, Ramos R, Sarver EJ (2003) Interaction between aberrations to improve or reduce visual performance. *J Cataract Refract Surg* 29:1487–1495
10. Wang L, Koch DD (2005) Effect of decentration of wavefront-corrected intraocular lenses on the higher-order aberrations of the eye. *Arch Ophthalmol* 123(9):1226–1230
11. Piers PA, Weeber HA, Artal P, Norrby S (2007) Theoretical comparison of aberration-correcting customized and aspheric intraocular lenses. *J Refract Surg* 23(4):374–384
12. Baumeister M, Neidhardt B, Strobel J, Kohnen T (2005) Tilt and decentration of three-piece foldable high-refractive silicone and hydrophobic acrylic intraocular lenses with 6-mm optics in an intraindividual comparison. *Am J Ophthalmol* 140(6):1051–1058
13. Jung CK, Chung SK, Baek NH (2000) Decentration and tilt: silicone multifocal versus acrylic soft intraocular lenses. *J Cataract Refract Surg* 26:582–585
14. Ram J, Apple DJ, Peng Q, Visessook N, Auffarth GU, Schoderbek RJ Jr, Ready EL (1999) Update on fixation of rigid and foldable posterior chamber intraocular lenses. Part I: elimination of fixation-induced decentration to achieve precise optical correction and visual rehabilitation. *Ophthalmology* 106:883–890
15. Dai D (2006) Optical surface optimization for the correction of presbyopia. *Appl Opt* 45:4184–4195

16. Jansonius NM, Kooijman AC (1998) The effect of spherical and other aberrations upon the modulation transfer of the defocused human eye. *Ophthalmic Physiol Opt* 18(6):504–513
17. Nio YK, Jansonius NM, Fidler V, Geraghty E, Norrby S, Kooijman AC (2002) Spherical and irregular aberrations are important for the optimal performance of the human eye. *Ophthalmic Physiol Opt* 22(2):103–112
18. Marcos S, Barbero S, Jiménez-Alfaro I (2005) Optical quality and depth-of-field of eyes implanted with spherical and aspheric intraocular lenses. *J Refract Surg* 21(3):223–235
19. Denoyer A, Le Lez ML, Majzoub S, Pisella PJ (2007) Quality of vision after cataract surgery after Tecnis Z9000 intraocular lens implantation: effect of contrast sensitivity and wavefront aberration improvements on the quality of daily vision. *J Cataract Refract Surg* 33(2):210–216
20. Tzelikis PF, Akaishi L, Trindade FC, Boteon JE (2008) Spherical aberration and contrast sensitivity in eyes implanted with aspheric and spherical intraocular lenses: a comparative study. *Am J Ophthalmol* 145(5):827–833
21. Kasper T, Bühren J, Kohnen T. (2006) Visual performance of aspheric and spherical intraocular lenses: intraindividual comparison of visual acuity, contrast sensitivity, and higher-order aberrations. *J Cataract Refract Surg* 32(12):2022–2029
22. Bellucci R, Scialdone A, Buratto L, Morselli S, Chiarego C, Criscuoli A, Moretti G, Piers P (2005) Visual acuity and contrast sensitivity comparison between Tecnis and AcrySof SA60AT intraocular lenses: a multicenter randomized study. *J Cataract Refract Surg* 31(4):712–717
23. Mester U, Dillinger P, Anterist N (2003) Impact of a modified optic design on visual function: clinical comparative study. *J Cataract Refract Surg* 29(4):652–660
24. Kershner RM (2003) Retinal image contrast and functional visual performance with aspheric, silicone, and acrylic intraocular lenses. Prospective evaluation. *J Cataract Refract Surg* 29(9):1684–1694
25. Tognetto D, Sanguinetti G, Sirotti P, Cecchini P, Marcucci L, Ballone E, Ravalico G. (2004) Analysis of the optical quality of intraocular lenses. *Invest Ophthalmol Vis Sci* 45(8):2682–2690
26. Muñoz G, Albarrán-Diego C, Montés-Micó R, Rodríguez-Galiero A, Alió JL (2006) Spherical aberration and contrast sensitivity after cataract surgery with the Tecnis Z9000 intraocular lens. *J Cataract Refract Surg* 32(8):1320–1327
27. Pandita D, Raj SM, Vasavada VA, Vasavada VA, Kazi NS, Vasavada AR (2007) Contrast sensitivity and glare disability after implantation of AcrySof IQ Natural aspheric intraocular lens: prospective randomized masked clinical trial. *J Cataract Refract Surg* 33(4):603–610
28. Rocha KM, Soriano ES, Chamon W, Chalita MR, Nosé W (2007) Spherical aberration and depth of focus in eyes implanted with aspheric and spherical intraocular lenses: a prospective randomized study. *Ophthalmology* 114(11):2050–2054
29. Johansson B, Sundelin S, Wikberg-Matsson A, Unsbo P, Behndig A (2007) Visual and optical performance of the Akreos Adapt Advanced Optics and Tecnis Z9000 intraocular lenses: Swedish multicenter study. *J Cataract Refract Surg* 33(9):1565–1572
30. McBride DK, Matson W (2003) Assessing the significance of optically produced reduction in braking response time: possible impacts on automotive safety among the elderly. Potomac Institute for Policy Studies, Arlington, Virginia
31. McBride DK, Matson W (2004) Assessing the significance of optically produced reduction in automobile crashes in an aging america population: possible economic impacts. Potomac Institute for Policy Studies, Arlington, Virginia
32. Wallin TR, Hinckley M, Nilson C, Olson RJ (2003) A clinical comparison of single-piece and three-piece truncated hydrophobic acrylic intraocular lenses. *Am J Ophthalmol* 136:614–619

How Should We Manipulate Higher-Order Aberrations After Refractive Surgery?

7

Jens Bühren, Thomas Kohnen, Scott M. MacRae

Core Messages

- Induction of least possible HOA should be a goal of all refractive surgical treatments
- Methods for minimizing HOA induction in excimer surgery are wavefront-guided and aspheric (“wavefront-optimized”) profiles, dynamic rotational sensible eye trackers, and femtosecond lasers for flap creation
- Implementation of several minor and moderate improvements will help to optimize optical quality of refractive surgical procedures

7.1 Refractive Surgical Procedures Induce Higher-Order Aberrations, and Higher-Order Aberration Correction Can Induce Spherical Refractive Error (Aberration Interaction)

Based on the plethora of reports in the literature, refractive surgical procedures often reduce spherical and cylindrical (lower-order) aberrations but have a tendency to induce higher-order aberrations (HOA) in a variety of refractive surgeries. APPLGATE and coworkers were the first to describe the induction of corneal HOA after radial keratotomy (RK) and their interference in visual performance [1, 2]. Subsequently, data were published for photorefractive keratectomy (PRK) [3, 4], laser in situ keratomileusis (LASIK) [5, 6], wavefront-guided LASIK [7], and phakic intraocular lenses (pIOL) [8, 9]. Often the pattern of HOA induction is similar for many procedures: the treatment results in a change of refraction over a defined central area of the cornea (the optical zone, OZ) which itself leads to a more or less high discrepancy between the center and the periphery. The use of relatively small optical zones in refractive surgery and the use of spherical implants in cataract surgery typically induces spherical aberration (SA). In corneal laser surgery, the higher the attempted effect and the smaller the programmed OZ and the larger the pupil, the higher is the SA induction [6, 10]. It has been shown that, even if the programmed OZ equaled the pupil diameter (PD), SA was induced [11–13]. The reason for the inherent SA induction has been discussed controversially: some authors favor physical reasons such as loss of energy in

the periphery of the cornea [14, 15], while others deem the biomechanical response of the cornea causal [16–18]. Myopic treatments induce positive SA, while hyperopic treatments expectedly induce negative SA [19, 20].

The second hallmark HOA induced by refractive surgical procedures is coma [1, 3, 19, 21]. The most likely reasons for coma induction are decentrations due to surgeon offsets and pupil shifts [22, 23] which translate SA into coma [24]. It is interesting to note that owing to their profile with more transition points and higher slopes [25] hyperopic ablations induce more SA per diopter of attempted SA [18, 19] and thus also bear the risk of higher coma induction [19]. Secondary astigmatism (a fourth-order aberration) shows a behavior similar to SA (e.g., change of C_4^2 in positive direction with myopic and negative direction with hyperopic treatments). Other sources for HOA induction after refractive surgery are the incisions in pIOL surgery (trefoil induction [8]), spherical aberration after implantation of a spherical IOL or phakic IOL and –to much lower extent– the creation of the flap after LASIK [26, 27]. Another problem is the induction of spherical refractive error when treating HOAs. This is most obvious in customized retreatment in individuals who have large amounts of preoperative third-order coma, trefoil or positive SA who will tend to have a postoperative hyperopic over-correction if the aberration interaction is not compensated for [28, 29]. This also occurs in virgin eyes treated with customized wavefront guided ablation. Compensating for aberration interaction improves the outcomes making the treatments more accurate [30, 31].

Summary for the Clinician

- Many refractive-surgical procedures induce spherical aberration which translates into coma if the treatment is decentred.
- There is also an interaction between preexistent HOAs and the refractive outcome, especially in eyes with high preoperative coma and spherical aberration.

7

7.2 Role of Higher-Order Aberrations After Refractive Surgery on Visual Performance

The advent of aberrometric techniques into clinical practice raised the question how wave aberrations influence visual performance and subjective quality of vision. APLEGATE and coworkers found that a high corneal wavefront error post refractive surgery, post keratoplasty or due to keratoconus reduced both low-contrast visual acuity (LCVA) and contrast sensitivity (CS) [32]. Also for uncomplicated conventional LASIK, correlations between the modulation transfer function (MTF, computed from the ocular wavefront error) and the contrast sensitivity function (CSF, obtained by psychophysical testing) could be found [33]. More systematic studies from the APLEGATE lab revealed different impact of different optical aberrations as represented by ZERNIKE modes on visual acuity [34], showed that combinations of certain ZERNIKE modes (e.g., Z_2^0 and Z_4^0) provided a better retinal image quality and visual acuity compared to a wavefront containing only the single modes Z_2^0 or Z_4^0 [35]. Another important finding was that higher-order aberrations mainly affect LCVA, especially under mesopic conditions [36]. This may be known from clinical experience and should be taken into account when assessing optical quality after refractive surgery. An ideal wavefront error representation to use as a metric to predict retinal image quality has not been found yet. There are several attempts to summarize the retinal image quality based on the ocular wavefront aberrations using clinically handy single-value metrics, with different success, however a definitive metric has not been established [37–40].

In our institutions, we recently performed a prospective study to investigate the impact of the wavefront error on the subjective quality of vision (SQV) post LASIK [41]. SQV was assessed psychometrically with a questionnaire and linear regression analysis was used to explore the variance of SQV scores explained by different wavefront data representations. In general, the influence of the wavefront error on SQV was limited. The model using individual Zernike coefficients explained up to 39% of

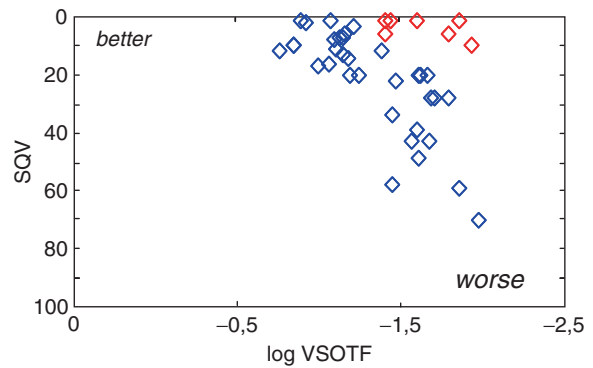


Fig. 7.1 Scatterplot diagram showing the subjective quality of vision (SQV) as a function of retinal image quality (VSOTF, 6mm PD). Red diamonds: eyes with high SQV despite low VSOTF (from [41])

the postoperative SQV variance with defocus (C_2^0) and secondary coma (C_5^{-1}) as significant predictors underlining the role of residual refractive error for SQV. The single-value metric that performed best in our study ($R^2 = 0.24$) was the VSOTF (visual Strehl ratio based on the optical transfer function [39]). Closer analysis of the scatter plot between VSOTF and SQV (Fig. 7.1) revealed the following important findings: First, a high theoretical retinal image quality (a high VSOTF) also yielded a good SQV. Second, patients who rated their SQV as “bad” also had a low retinal image quality (low VSOTF). Third, some patients rated their SQV as “good” although their VSOTF was low. The first two findings strongly suggest that induction of less HOA should be the aim of modern refractive surgery while the third finding is an important reason for the difficulty of finding a reliable wavefront aberration metric or value that describes the threshold between good and bad optical quality.

Summary for the Clinician

- Higher-order aberrations affect low-contrast acuity more than high-contrast acuity.
- Low postoperative wave aberrations are associated with a high subjective quality of vision. Eyes with a low subjective quality of vision are more highly aberrated.

7.3 Methods to Optimize the Wavefront Error Post Refractive Surgery

Based on the findings summarized in the previous chapter, the improvements of standard refractive surgical procedures should address the reduction of HOA induction. In

the recent years, several modifications have been implemented to achieve this goal:

7.3.1 Wavefront-Guided Laser Profiles

The introduction of wavefront-guided laser profiles aimed at the reduction of the physiological HOAs pre-existent in the eye [42]. In contrast to the multitude of publications on wavefront-guided excimer procedures (for review, see [43, 44]) there are only few peer-reviewed reports of prospective studies that compared the outcomes of wavefront-guided and conventional excimer surgery [45–47]. While the HOA induction was lower with wavefront-guided profiles, the patient satisfaction was similar. One potential reason is that there is still a net induction of HOAs: a recent study showed that the wavefront-guided algorithm reduced the preexisting HOA with a certain effect; in the meantime it also induced HOA -mainly coma and SA [10]. Most of the HOA reduction effect was overridden by the inherent induction of spherical aberration which increased with the attempted spherical equivalent and decreased with the diameter of the programmed optical zone.

7.3.2 Aspheric (“Wavefront-Optimized”) Laser Profiles

The goal of aspheric ablation profiles [48, 49] is the reduction of the inherent induction of SA which is the hallmark aberration induced with corneal refractive surgical procedures. Since the induction of coma-like aberration is closely linked to SA induction [24] aspheric well-centred treatments are also likely to induce less coma. Thus, avoiding or at least reducing the induction of SA and consecutive coma is an important step for the improvement of the predictability of wavefront-guided corneal refractive procedures [10]. Recently, first clinical results of aspheric profiles in PRK and LASIK were published [50–52]. Wavefront-optimized profiles appeared to be predictable and safe, and treatments tended to induce – as expected – less SA. The comparative studies found slightly higher low-contrast visual acuity [50] and contrast sensitivity [51], respectively. It is important to note that a prolate cornea or a standard Q factor alone does not guarantee a high image quality which is dependent from effective SA [53]. Spherical aberration is a result of the Q factor, the pupil size, the lenticular aberrations and the axial length of the eye [54]. Therefore, aspheric ablation profiles should be customized for optimal image quality or precompensate for the expected induction of SA.

7.3.3 Improved Treatment Registration: Dynamic Rotational Sensible (Active) Eyetrackers

Another potential source of lack of predictability is the cyclotorsion of the globe between sitting and supine position [55]. Also torsional misalignment can lead to under-correction and induction of aberrations [56]. Advanced eye trackers not only compensates for translational movements along the x - and y -axis but also correct for cyclotorsional deviation [57]. The latest generation of eye trackers compensates for torsional movements during the treatment. Preliminary results suggest increase of efficacy of cylinder treatment [58].

7.3.4 Improved Keratomes: Femtosecond Laser LASIK

It is known for quite some time that the keratome incision induces HOAs [26, 27, 56], albeit at a negligible rate if compared to those induced by the ablation [27]. There is some recent evidence that femtosecond laser flaps induce less HOAs, namely spherical aberration [59, 60] although some studies may note no difference when comparing mechanical microkeratome and femtosecond laser cuts [61].

Summary for the Clinician

- *Wavefront-guided profiles* reduce physiological preexisting HOA but their efficacy could be compromised by inherent induction of spherical aberrations and coma.
- *Aspheric ablation profiles* could reduce the induction of spherical aberration.
- *Dynamic rotational sensible eye trackers* could improve predictability of astigmatic and wavefront-guided treatments.
- *Femtosecond lasers* may induce less HOAs than mechanical microkeratomes when the LASIK flap is cut.

7.4 Current and Future State of the Art LASIK and Lenticular Surgery

Based on the findings summarized in the previous paragraphs it is likely that not only one solution rather than a variety of minor and moderate improvements implemented together could be able to optimize outcomes. Therefore, for the future state of the art LASIK the cut is performed with a femtosecond laser, the programmed

optical zone is based on the patient's individual pupil size and an aspheric wavefront-guided profile with a dynamic rotational sensible (active) eye-tracker is used. Further potential improvements include treatment planning based on individual anatomic and biomechanic properties ("biomechanical customization" [59, 62]), aberration interactions, closed-loop ablation monitoring of the ablation effect [60] and the use of wound healing–modulating agents in surface ablation [63]. The use of more sensitive and more robust wavefront sensors in combination with corneal topography will allow more sophisticated ablation design which can correct corneal or other ocular aberrations selectively. In the field of intraocular lens (IOL) surgery, the use of aspheric optics which are customized to compensate for corneal and lenticular (for phakic IOLs) aberrations will also improve outcomes.

Summary for the Clinician

- The single effects of new technical improvements (e.g., profiles, eye trackers) are often marginal; a combined implementation is likely to improve outcomes notably
- The femtosecond-laser assisted LASIK with a wavefront-guided aspheric profile under control of a dynamic, rotational sensible (dynamic) eye tracker will help optimize these procedures in the near future.

References

1. Applegate RA, Gansel KA (1990) The importance of pupil size in optical quality measurements following radial keratotomy. *Refract Corneal Surg* 6(1):47–54
2. Applegate RA, Hilmantel G, Howland HC (1996) Corneal aberrations increase with the magnitude of radial keratotomy refractive correction. *Optom Vis Sci* 73(9):585–589
3. Martinez CE, Applegate RA, Klyce SD, et al (1998) Effect of pupillary dilation on corneal optical aberrations after photorefractive keratectomy. *Arch Ophthalmol* 116(8):1053–1062
4. Seiler T, Kaemmerer M, Mierdel P, Krinke HE (2000) Ocular optical aberrations after photorefractive keratectomy for myopia and myopic astigmatism. *Arch Ophthalmol* 118(1):17–21
5. Oshika T, Klyce SD, Applegate RA, et al (1999) Comparison of corneal wavefront aberrations after photorefractive keratectomy and laser in situ keratomileusis. *Am J Ophthalmol* 127(1):1–7
6. Moreno-Barrusio E, Lloves JM, Marcos S, et al (2001) Ocular aberrations before and after myopic corneal refractive surgery: LASIK-induced changes measured with laser ray tracing. *Invest Ophthalmol Vis Sci* 42(6):1396–1403
7. Kohnen T, Bühren J, Kühne C, Mirshahi A (2004) Wavefront-guided LASIK with the Zyoptix 3.1 system for the correction of myopia and compound myopic astigmatism with 1-year follow-up: clinical outcome and change in higher order aberrations. *Ophthalmology* 111(12):2175–2185
8. Bühren J, Kasper T, Terzi E, Kohnen T (2004) Higher order aberrations after implantation of an iris claw pIOL (Ophtec Artisan) in the phakic eye. *Ophthalmologie* 101(12):1194–1201
9. Tahzib NG, Bootsma SJ, Eggink FA, Nuijts RM (2006) Functional outcome and patient satisfaction after Artisan phakic intraocular lens implantation for the correction of myopia. *Am J Ophthalmol* 142(1):31–39
10. Bühren J, Kohnen T (2006) Factors affecting the change in lower-order and higher-order aberrations after wavefront-guided laser in situ keratomileusis for myopia with the Zyoptix 3.1 system. *J Cataract Refract Surg* 32(7):1166–1174
11. Boxer Wachler BS, Huynh VN, El-Shiaty AF, Goldberg D (2002) Evaluation of corneal functional optical zone after laser in situ keratomileusis. *J Cataract Refract Surg* 28(6):948–953
12. Holladay JT, Janes JA (2002) Topographic changes in corneal asphericity and effective optical zone after laser in situ keratomileusis. *J Cataract Refract Surg* 28(6):942–947
13. Bühren J, Kühne C, Kohnen T (2005) Influence of pupil and optical zone diameter on higher-order aberrations after wavefront-guided myopic LASIK. *J Cataract Refract Surg* 31(12):2272–2280
14. Dorransoro C, Cano D, Merayo-Lloves J, Marcos S (2006) Experiments on PMMA models to predict the impact of corneal refractive surgery on corneal shape. *Optics Express* 14(13):6142–6156
15. Freedman KA, Brown SA, Mathews SM, Young RSL (2003) Pupil size and the ablation zone in laser refractive surgery: Considerations based on geometric optics. *J Cataract Refract Surg* 19(10):1924–1931
16. Nagy LJ, MacRae S, Yoon G, et al (2007) Photorefractive keratectomy in the cat eye: Biological and optical outcomes. *J Cataract Refract Surg* 33(6):1051–1064
17. Roberts C (2000) The cornea is not a piece of plastic. *J Refract Surg* 16(4):407–413
18. Yoon G, MacRae S, Williams DR, Cox IG (2005) Causes of spherical aberration induced by laser refractive surgery. *J Cataract Refract Surg* 31(1):127–135
19. Kohnen T, Mahmoud K, Bühren J (2005) Comparison of corneal higher-order aberrations induced by myopic and hyperopic LASIK. *Ophthalmology* 112(10):1692
20. Llorente L, Barbero S, Merayo J, Marcos S (2004) Total and corneal optical aberrations induced by laser in situ keratomileusis for hyperopia. *J Refract Surg* 20(3):203–216
21. Oshika T, Miyata K, Tokunaga T, et al (2002) Higher order wavefront aberrations of cornea and magnitude of refractive

- correction in laser in situ keratomileusis. *Ophthalmology* 109(6):1154–1158
22. Porter J, Yoon G, Lozano D, et al (2006) Aberrations induced in wavefront-guided laser refractive surgery due to shifts between natural and dilated pupil center locations. *J Cataract Refract Surg* 32(1):21–32
 23. Porter J, Yoon G, MacRae S, et al (2005) Surgeon offsets and dynamic eye movements in laser refractive surgery. *J Cataract Refract Surg* 31(11):2058–2066
 24. Bühren J, Yoon G, Kenner S, et al (2007) The effect of optical zone decentration on lower- and higher-order aberrations after photorefractive keratectomy in a cat model. *Invest Ophthalmol Vis Sci* 48(12):5806–5814
 25. MacRae S (1999) Excimer ablation design and elliptical transition zones. *J Cataract Refract Surg* 25:1191–1197
 26. Pallikaris I, Kymionis G, Panagopoulou S, et al (2002) Induced optical aberrations following formation of a laser in situ keratomileusis flap. *J Cataract Refract Surg* 28:1737–1741
 27. Porter J, MacRae S, Yoon G, et al (2003) Separate effects of the microkeratome incision and laser ablation on the eye's wave aberration. *Am J Ophthalmol* 136(2):327–337
 28. Durrie DS, Stahl JE, Schwendeman F (2005) Alcon LADAR-Wave customcornea retreatments. *J Refract Surg* 21(6):S804–S807
 29. Schwartz GS, Park DH, Lane SS (2005) CustomCornea wavefront retreatment after conventional laser in situ keratomileusis. *J Cataract Refract Surg* 31(8):1502–1505
 30. Subbaram MV, MacRae S, Slade SG, Durrie DS (2006) Customized LASIK treatment for myopia: relationship between preoperative higher order aberrations and refractive outcome. *J Refract Surg* 22(8):746–753
 31. Subbaram MV, MacRae SM (2007) Customized LASIK treatment for myopia based on preoperative manifest refraction and higher order aberrometry: the Rochester nomogram. *J Refract Surg* 23(5):435–441
 32. Applegate RA, Hilmantel G, Howland HC, et al (2000) Corneal first surface optical aberrations and visual performance. *J Refract Surg* 16(5):507–514
 33. Marcos S (2001) Aberrations and visual performance following standard laser vision correction. *J Refract Surg* 17(5):S596–S601
 34. Applegate RA, Sarver EJ, Khemsara V (2002) Are all aberrations equal? *J Refract Surg* 18(5):S556–S562
 35. Applegate RA, Marsack JD, Ramos R, Sarver EJ (2003) Interaction between aberrations to improve or reduce visual performance. *J Cataract Refract Surg* 29(8):1487–1495
 36. Pseudovs K, Marsack JD, Donnelly WJL, et al (2004) Measuring visual acuity-mesopic or photopic conditions, and high or low contrast letters? *J Refract Surg* 20:S508–S514
 37. Campbell CE (2004) Improving visual function diagnosis with the use of higher-order information from metrics. *J Refract Surg* 20(5):S495–S503
 38. Chen L, Singer B, Guirao A, et al (2005) Image metrics for predicting subjective image quality. *Optom Vis Sci* 82(5):358–369
 39. Cheng X, Thibos LN, Bradley A (2003) Estimating visual quality from wavefront aberration measurements. *J Refract Surg* 19(5):S579–S584
 40. Marsack JD, Thibos LN, Applegate RA (2004) Metrics of optical quality derived from wave aberrations predict visual performance. *J Vis* 4(4):322–328
 41. Bühren J, Strenger A, Martin T, Kohnen T (2007) Wavefront aberrations and subjective quality of vision after wavefront-guided LASIK: First results. *Ophthalmologie* 104(8):688–696
 42. Seiler T, Mrochen M, Kaemmerer M (2000) Operative correction of ocular aberrations to improve visual acuity. *J Refract Surg* 16(5):S619–S622
 43. Kohnen T, Kühne C, Bühren J (2007) The future role of wavefront-guided excimer ablation. *Graefes Arch Clin Exp Ophthalmol* 245:189–194
 44. Netto MV, Dupps W, Jr., Wilson SE (2006) Wavefront-guided ablation: evidence for efficacy compared to traditional ablation. *Am J Ophthalmol* 141(2):360–368
 45. Kim TI, Yang SJ, Tchah H (2004) Bilateral comparison of wavefront-guided versus conventional laser in situ keratomileusis with Bausch and Lomb Zyoptix. *J Refract Surg* 20(5):432–438
 46. Mastropasqua L, Nubile M, Ciancaglini M, et al (2004) Prospective randomized comparison of wavefront-guided and conventional photorefractive keratectomy for myopia with the meditec MEL 70 laser. *J Refract Surg* 20(5):422–431
 47. Tran DB, Shah V (2006) Higher order aberrations comparison in fellow eyes following intraLase LASIK with wavelight allegretto and customcornea LADARvision4000 systems. *J Refract Surg* 22(9):S961–S964
 48. Manns F, Ho A, Parel JM, Culbertson W (2002) Ablation profiles for wavefront-guided correction of myopia and primary spherical aberration. *J Cataract Refract Surg* 28(5):766–774
 49. Mrochen M, Donitzky C, Wüllner C, Löffler J (2004) Wavefront-optimized ablation profiles: theoretical background. *J Cataract Refract Surg* 30(4):775–785
 50. Mastropasqua L, Toto L, Zuppari E, et al (2006) Photorefractive keratectomy with aspheric profile of ablation versus conventional photorefractive keratectomy for myopia correction: six-month controlled clinical trial. *J Cataract Refract Surg* 32(1):109–116
 51. Padmanabhan P, Mrochen M, Basuthkar S, et al (2008) Wavefront-guided versus wavefront-optimized laser in situ keratomileusis: contralateral comparative study. *J Cataract Refract Surg* 34(3):389–397
 52. Randleman JB, Loft ES, Banning CS, et al (2007) Outcomes of wavefront-optimized surface ablation. *Ophthalmology* 114(5):983–988

53. Tuan KM, Chernyak D (2006) Corneal asphericity and visual function after wavefront-guided LASIK. *Optom Vis Sci* 83(8):605–610
54. Calossi A (2007) Corneal asphericity and spherical aberration. *J Refract Surg* 23(5):505–514
55. Pansell T, Schworm H, Ygge J (2003) Torsional and vertical eye movements during head tilt dynamic characteristics. *Invest Ophthalmol Vis Sci* 44:2986–2990
56. Bueeler M, Mrochen M, Seiler T (2004) Maximum permissible torsional misalignment in aberration-sensing and wavefront-guided corneal ablation. *J Cataract Refract Surg* 30(1):17–25
57. Kohnen T, Kühne C, Cichocki M, Strenger A (2007) Cyclorotation of the eye in wavefront-guided LASIK using a static eyetracker with iris recognition. *Ophthalmologie* 104(1):60–65
58. Bharti S, Bains HS (2007) Active cyclotorsion error correction during LASIK for myopia and myopic astigmatism with the NIDEK EC-5000 CX III laser. *J Refract Surg* 23(9 Suppl):S1041–S1045
59. Roberts C (2005) Biomechanical customization: the next generation of laser refractive surgery. *J Cataract Refract Surg* 31(1):2–5
60. Schruender SA, Fuchs H, Spasovski S, Dankert A (2002) Intraoperative corneal topography for image registration. *J Refract Surg* 18(5):S624–S629
61. Patel SV, Maguire LJ, McLaren JW, et al (2007) Femtosecond Laser versus Mechanical Microkeratome for LASIK: a randomized controlled study. *Ophthalmol* 114:1482–1490
62. Slade SG (2007) The use of the femtosecond laser in the customization of corneal flaps in laser in situ keratomileusis. *Curr Opin Ophthalmol* 18(4):314–317
63. Netto MV, Mohan RR, Ambrosio R Jr, et al (2005) Wound healing in the cornea: a review of refractive surgery complications and new prospects for therapy. *Cornea* 24(5):509–522

Current State of Accommodation Research

Martin Baumeister and Thomas Kohnen

Core Messages

- Accommodation is a dynamic change in the dioptric power of the eye.
- It is achieved by release of zonular tension with contraction of the ciliary muscle and consecutive molding of the shape of the crystalline lens by the elastic lens capsule.
- The ability to accommodate is gradually lost with age (presbyopia).
- Because of difficulties with the examination of the accommodative apparatus in vivo, many theories, in part contradictory, about the mechanism of accommodation and the origin of presbyopia have been developed.
- In recent years, experimental studies have greatly increased the knowledge about the accommodative apparatus and suggest a multifactorial etiology of presbyopia.
- A better understanding of the physiology of accommodation and presbyopia can contribute to the development of effective treatments.

8.1 Introduction

8.1.1 Accommodation

By “accommodation” is understood the change of the eye’s optical power to facilitate focusing on objects at different distances. Hermann von Helmholtz whose description of the accommodative mechanism from the year 1855 is still valid in all major parts wrote in his *Handbook of Physiological Optics*: “There is no other portion of physiological optics where one finds so many differing and contradictory ideas as concerns the accommodation of the eye where only recently in the most recent time have we actually made observations where previously everything was left to the play of hypotheses [1]”. Even nowadays, the mechanism of accommodation and the cause of presbyopia are a matter of controversial discussion, and a general consensus comprising all the elements has not yet been reached.

8.1.2 Presbyopia

With advancing age in humans and other primates the accommodative ability is gradually lost. This condition, known as presbyopia (Greek for “old-sightedness”),

constitutes the most frequent visual impairment in humans. It affects without exception all humans who reach a sufficient age. The decrease of the accommodative amplitude has already begun at an age of 10–12 years and ends with the nearly complete loss of accommodative ability at 50–55 years of age. Presbyopia can be corrected by various optical methods and, although it does not result in disability or blindness, it contributes to a rise of health care costs in the aging societies of today’s industrialized nations.

8.2 The Mechanism of Accommodation

8.2.1 Anatomy of the Accommodative Apparatus

8.2.1.1 Ciliary Muscle

The accommodative plant of the eye contains the ciliary body, the ciliary muscle, the anterior and posterior zonular fibers, and the lens, which consists of the lens capsule and the lens substance. The ciliary muscle is located within the ciliary body and consists of three groups of muscular fibers which are distinguished by their situation and ordering within the ciliary body [2]. These groups are the

longitudinal, the radial, and the equatorial or circular fibers. The longitudinal part of the muscle borders directly to the sclera. Farther inward of the longitudinal part are the radial fibers and, farthest anterior and inward, the circular fibers. Anteriorly, the ciliary muscle inserts at the scleral spur and the trabecular meshwork. Posteriorly, it is fixed by elastic tendons to the stroma of the choroid.

8.2.1.2 Zonular Fibers

The zonule consists of fine elastic fibers which can be grouped by localization, origin, and insertion into two groups (posterior and anterior). The posterior or pars plana zonular fibers have their origin near the posterior insertion of the ciliary muscle at the ora serrata [3], and extend in a longitudinal direction to the pars plicata of the ciliary body where they insert in the walls of the crypts between the ciliary processes [4]. The anterior zonular fibers extend from the ciliary processes to the lens and insert in the equatorial region of the lens [5]. Recent research has confirmed the attachment of the posterior zonule to the anterior hyaloid membrane [6].

8.2.1.3 Lens and Lens Capsule

The lens is a transparent biconvex organ consisting of capsule, epithelium, cortex, and nucleus. It is held in position between the iris and the vitreous cavity by the zonular fibers. It can refract light because its index of refraction (about 1.4) is different from that of the aqueous humor and the vitreous body (1.336) [7]. The lens capsule is a membrane of collagen type IV which is produced by the lens epithelium and has a thickness of 5–25 μm . It is thickest at the peripheral anterior and posterior surface and thinner towards the equator. The thinnest regions are the anterior and posterior pole [8]. The lens thickness increases during life because the lens epithelium, which is located under the anterior lens capsule and at the lens equator, generates new lens fibers with a hexagonal diameter which are stacked in a shell-like fashion and form the lens cortex [9]. The oldest fibers form the lens nucleus.

8.2.2 The Helmholtz Mechanism of Accommodation

8.2.2.1 Far-to-Near Accommodation

In 1855, Helmholtz described his theory on the process of accommodation which is in all major points still the base for the current understanding of accommodation [10].

The lens is held in its flattened unaccommodated state by the zonular fibers whose resting tension pulls the lens equator outwards. An accommodation stimulus effects contraction of the ciliary muscle. Some of the muscular fibers reorient and the ciliary muscle moves anteriorly and inwards [11] thus diminishing the diameter of the ciliary ring. This decreases the tension of the zonular fibers, and the elastic lens capsule moulds the lens into a more accommodated, i.e., more spherical, shape [12] with an increased lens thickness, an increased curvature of the refractive surfaces, and shorter focal length. Thus, the refractive power of the lens, and of the whole eye, increases.

8.2.2.2 Near-to-Far Accommodation (Disaccommodation)

When the accommodating stimulus is released, the contraction of the ciliary muscle decreases and the muscle is pulled outward and posteriorly to its resting position by the elastic Bruch's membrane and the posterior zonular fibers [4]. Thus, the diameter of the ciliary ring increases and the tension of the zonular fibers is restored, pulling the lens again outward and posteriorly towards the ciliary muscle. The anterior zonule, which is anchored in the crypts between the ciliary processes [3], transmits the traction of the muscle and the elastic tissues to the lens capsule. The axial thickness of the lens decreases, the equatorial diameter of the lens increases, and the anterior and posterior surfaces decrease their curvatures. When this is completed, the lens has reached again its unaccommodated resting state.

8.2.3 Proposed Alternative Mechanisms of Accommodation

It is not disputed that the change in shape of the lens plays a major role in the process of accommodation. However, there is disagreement about the details of the steepening of lens curvature effecting the change in ocular focus. The difficulties are foremost due to the fact that the process of accommodation in the human eye is for the larger part not visible in vivo. Additionally, some concerns have been raised about particular points in the accommodative process, such as the very precise and rapid change of the anterior lens curvature with considerably less change in the posterior curvature, and the small but detectible forward movement of the entire lens which are, as some authors claim, not sufficiently explained by the accommodative mechanism according to Helmholtz [13–15].

Some authors have considered a contribution of the vitreous body to accommodation [16–18]. It could serve

either passively as support for the stabilization of the posterior lens surface or take over an active role by compressing the lens peripherally when the ciliary muscle contracts. Experiments conducted by Coleman on primates and a blind human eye showed an intraocular pressure gradient between the anterior and the posterior segment of the eye during accommodation with the effect of a decrease in pressure of the anterior segment with a corresponding increase of pressure in the vitreous cavity [19]. Thus, the action of the ciliary muscle on the choroidal tissue would increase vitreous pressure causing the entire lens–zonule complex to move forward and the posterior lens surface to steepen less than the anterior. However, *in vitro* investigations using centrifugal forces or mechanical stretching of human cadaver lenses have shown that the accommodative changes of the human are reproducible without the presence of the vitreous body or a vitreous compartment [5, 20]. In a clinical case of unilateral vitrectomy in a 32-year-old patient published by Fisher [21], no significant difference in accommodative ability between the vitrectomized and the nonvitrectomized eye was detected. Nevertheless, microscopic studies have described a close relationship between the posterior zonules and the anterior hyaloid membrane [22], which was recently confirmed by Bernal and coauthors [6] who described an anchoring of the majority of posterior zonular fibers on the anterior hyaloid membrane. This leaves at least the possibility of posterior lens support or suspension by the anterior vitreous.

Other theories have been proposed which represent an entirely different understanding of the accommodative mechanism. Tscherning originally proposed an accommodative mechanism which involved a flattening of the lens periphery and a steepening of its center [18]. This was partly based on studies on bovine lenses which, however, are different from human lenses and lack the ability to accommodate. A variant of this theoretical mechanism has been proposed more recently [23]. This theory involves an increase of the equatorial lens diameter during accommodation because, contrary to the usually accepted view, the ciliary muscle is supposed to pull the lens outwards. This also implies a different understanding of the zonular architecture. The existence of three distinct groups of zonular fibers is suggested, one of which inserts at the lens equator; the second one at the anterior lens surface, and the third one at the posterior lens surface. The tension of the middle (“equatorial”) group increases and pulls the lens equator outward while the other two groups relax and serve to stabilize the position of the lens. There is, however, no direct experimental evidence for the existence of these three distinct zonular groups, and studies performed *in vivo* on iridectomized

rhesus monkeys clearly show a decrease of lens diameter with accommodation in accordance with the Helmholtz mechanism of accommodation [24, 25].

Summary for the Clinician

- Accommodation is effected by a change in the optical power of the crystalline lens.
- During accommodation, by contraction of the ciliary muscle, the equatorial lens diameter decreases, while its thickness and anterior and posterior surface curvatures increase.
- The Helmholtz mechanism of accommodation is supported by convincing experimental evidence.
- It needs to be ensured, therefore, that the performance of instruments with reduced diameters at least equals that of the well-established 20-gauge system.

8.3 Neural Control of Accommodation

8.3.1 Parasympathetic Innervation

Stimuli for accommodation are primarily blur, but also include changes in ocular vergence, perceived object size, or optical aberrations, especially longitudinal chromatic aberration [26–29]. The innervation of the ciliary muscle is mostly parasympathetic. The afferent pathway runs from the optic nerve via the lateral geniculate body to the primary visual cortex (area 17). From there, the accommodation-related nerve fibers reach area 19. The processing of accommodative stimuli takes place in cooperation of different cortical and cerebellar areas [30]. From the visual cortex, the signal is transmitted to the Edinger–Westphal nucleus (accessory oculomotor nucleus) in the midbrain. From there, impulses are sent to the ciliary muscle and the pupil sphincter via the ciliary ganglion and the short, possibly also the long [31], ciliary nerves, but also to the motor nerve nuclei in the brainstem. In this way, accommodation is coupled with pupil constriction and convergence (accommodative triad). The magnitude of the change in pupil size with accommodation varies with accommodative amplitude and age [32].

8.3.2 Sympathetic Innervation

The sympathetic innervation of the ciliary muscle has an inhibitory function and contributes to the relaxation of the muscle during disaccommodation, but has little effect

in stimulus-driven closed-loop accommodation [33]. It originates in the diencephalon and runs via the spinal chord to the superior cervical ganglion. From there, the nerve fibers of the third neuron continue their way in the carotid plexus and enter the orbit with the first branch of the trigeminal nerve where they join the long and short ciliary nerves.

Summary for the Clinician

- Accommodation is coupled with convergence and pupil constriction (accommodative triad).

8.4 Pseudo-Accommodation

Accommodation, i.e., the dynamic change of focus, needs to be distinguished from other conditions that can help to achieve good near vision by increasing the depth of field of the eye. These are often referred to as apparent accommodation or “pseudo-accommodation”. One of the most important of them is the constriction of the pupil during accommodation, which is dynamic but does not cause the focus change implied in the definition of accommodation. Static conditions like against-the-rule astigmatism can also increase the eye’s depth of field and facilitate near vision in a presbyopic or pseudophakic eye without actual accommodation [34]. The fundamental distinction between accommodation and pseudo-accommodation is apparent when one compares subjective and objective measurements of accommodation. Subjective measurement, such as the “push-up” test, in which a viewing target is moved closer to the eye from a distance, regularly overestimate the true accommodative amplitude, and even in fully presbyopic subjects an apparent accommodative amplitude of about 1.0D can be measured with subjective tests [35].

Summary for the Clinician

- Good subjective near vision is achieved by a combination of accommodation and pseudo-accommodation.
- Subjective measurements overestimate the accommodative amplitude.

8.5 Presbyopia

8.5.1 Development of Presbyopia

The decrease of accommodative amplitude starts at a young age. Children can have an accommodative amplitude of 15D, while during youth it is about 10D. By the age of 35, two-thirds of the original accommodative amplitude is lost. By the age of 55–60, the ability to accommodate is completely lost [36].

8.5.2 Theories About the Etiology of Presbyopia

8.5.2.1 Lenticular Origin

Hardening of the Lens

Presbyopia is generally regarded as the effect of age-related changes in the accommodative apparatus of the eye. There is, however, disagreement as to the exact causes of the accommodative decline and the contribution of different structures to the development of presbyopia. Theories about the origin of presbyopia can be broadly divided into those which locate the cause of presbyopia in the lens and those which focus on the extralenticular parts of the accommodative apparatus. As accommodation is effected by a change in shape of the lens, the classical assumption is that progressive hardening or “sclerosis” of the lens causes presbyopia because, in spite of undiminished force and excursion of the ciliary muscle, the lens capsule cannot any longer mold the lens because the lens substance is too hard [37]. This would mean that with advancing age there is an increasing “latent” excursion of the ciliary muscle which no longer has any effect on the lens.

As first reported by Fincham in 1937 [12], in the presbyopic eye after cutting the zonular fibers the lens capsule is unable to exert enough force for accommodation on the hardened lens substance. Other experimental studies proved that the ability of the human lens to change its shape with mechanical stretching decreases continuously until the age of 60 years [5]. After that, no changes in shape can take place. In fact, the age-related loss of the ability of the lens to change its focus runs parallel to the loss of accommodative amplitude with age, to an extent that virtually all of the accommodative loss could be accounted for by the lens [5]. Physical measurements of the human lens substance showed an exponential increase of hardness with age [5, 38–40]. More recent studies indicate that the change of the stiffness gradient between lens nucleus and lens cortex plays an important role in the development of presbyopia [41, 42]. The

relationship between this change in the lens and nuclear cataract in older people is the subject of further research. There are indications that nuclear cataract is related to a disturbance of transport of metabolites within the lens and that presbyopia could be viewed as the first stage of nuclear cataract [43].

Growth of the Lens

The continuous growth of the lens throughout life and the suspected changes in the insertion angle of the zonule led to the hypothesis that presbyopia could be related to the inability of the zonular fibers to hold the lens in its far-accommodated (disaccommodated) state [44]. Also, it has been shown that the amount of tension that must be applied to the zonular fibers to change the shape of the lens *in vitro* increases with age. It is thus supposed to be in a permanently near-accommodated state. Compensatory changes of the refractive index of the lens are used as an explanation why the human eye does not, as one should expect, become myopic with age. It has, however, been shown that accommodation occurs primarily by thickening of the lens nucleus and that the thickness of the nucleus of an unaccommodated lens remains constant with age [45]. This makes it unlikely that an older unaccommodated lens has the properties of a young accommodated lens. Moreover, experimental studies have confirmed that a change in zonular tension cannot effect optical variations in old human lenses [38]. This argues against the hypothesis that the lens in the presbyopic eye is unable to take up its unaccommodated shape.

There are many documented effects of aging on the human lens. The insertion of the anterior zonule near the lens equator shifts anteriorly with advancing age. In contrast, the distance between the insertion of the zonular fibers and their origin in the ciliary body remains constant with advancing age [46]. This led to the development of the “geometrical theory” of presbyopia [47, 48], which states that the increasing lens thickness and the anterior displacement of the zonular fibers with age cause a decrease of the insertion angle at the anterior side of the lens near the equator. This should influence the change in tension of the zonular fibers and thus prevent accommodation of the lens. So far, there is no experimental evidence for this mechanism. Investigations on lens/ciliary body specimens *in vitro* did not result in a loss of zonular tension with age, independently from the insertion angle [5].

Aging of the Lens Capsule

Generally, it is held as the purpose of the lens capsule to mold the lens substance into the accommodated shape. For this reason, age-related changes in the lens capsule are

also seen as one possible cause of presbyopia. According to some *in vitro* studies, the capsule becomes thicker with age up to 60–75 years and afterwards becomes thinner again. It becomes less elastic [49] and more brittle with age [50]. Other recent investigations, however, indicate that the mechanical properties of the lens capsule may remain constant with age [51]. The partly contradicting results of previous studies and the uncertainties concerning the exact role of the lens capsule for accommodation make it difficult to estimate its contribution to presbyopia. Results from animal experiments in primates show that the capsule participates in the movement of the lens and ciliary processes during accommodation and that aging of the capsule can play a role in the development of presbyopia [52].

8.5.2.2 Extralenticular Origin

Ciliary Muscle

Presbyopia has often been attributed to a dysfunction of the ciliary muscle, possibly caused by a loss of elasticity of the tendons, of the posterior zonular fibers, or of the choroid [53], by age-related degeneration of muscle and nerve fibers [54] or configuration changes [11]. The number and binding affinity of the muscarinic receptors of the ciliary muscle as well as the activity of the acetylcholine-synthesizing enzymes do not change with age [55], and the isolated ciliary muscle of the rhesus monkey shows no age-related loss of its contractile response to acetylcholine [56]. The parasympathetic neuro-muscular mechanism thus seems to stay intact. The geometrical and optical changes of the lens during accommodation are, however, mainly caused by the anteroaxial movement of the muscle and not by the force of the muscle contraction [57].

In humans, *in vivo* studies with magnet resonance imaging (MRI) show that the decrease of the ciliary muscle diameter with accommodation is reduced in older pre-presbyopic eyes [58]. In a presbyopic eye, this remaining muscle movement is, however, not accompanied by increasing lens thickness or decreasing equatorial lens diameter [58]. The MRI examinations also show a decrease in ciliary muscle ring diameter with advancing age. These results agree with histological studies which show that the inner apex of the far-accommodated ciliary muscle gradually moves forward and inward until it almost has the appearance of a young accommodated ciliary muscle [59]. This configurational change results from the combined effects of an inward pull of the zonular fibers from the lens equator and the decreased elasticity of the posterior tendon. In older rhesus monkeys, the

mobility of the ciliary muscle is reduced but not totally lost. Even when the lens is fully immobile, stimulation of the Edinger–Westphal nucleus results in a significant inward movement of the ciliary body [24]. Nevertheless, the histological and morphometric data in the rhesus monkey show that a loss of ciliary body mobility probably plays a role in the pathophysiology of presbyopia.

Extralenticular Elastic Tissues

A loss of elasticity of Bruch's membrane which is fixed to the posterior part of the ciliary muscle could be responsible for the loss in muscle mobility and accommodation amplitude. If this tissue becomes more rigid, the ciliary body eventually fails to move sufficiently in an antero-axial direction. In eyes of older rhesus monkeys, the posterior elastic tendons of the ciliary muscle are thicker and show histological changes which are compatible with a diminished elasticity [60]. By partial dissection of the posterior insertion of the muscle, the mobility of the ciliary muscle in reaction to pilocarpine can be fully restored [53]. For this reason, restriction of ciliary muscle mobility due to an increasingly unelastic posterior fixation could be related to presbyopia. Most likely, presbyopia is caused by an interaction of several factors [61], and lenticular and ciliary-muscle related origins are not mutually exclusive [5, 11, 53].

Vitreous Body

If the vitreous body plays a more important role in accommodation than support and stabilization of the posterior lens surface [16], it can be assumed that age-related changes in the vitreous body contribute to the development of presbyopia. With age, the vitreous body becomes increasingly liquefied which could diminish the peripheral compression of the lens. Alternatively, growth of the lens could affect this supposed accommodative function of the vitreous body [13].

8.5.2.3 Multifactorial Origin of Presbyopia

Age-related changes can be found in all components of the accommodative apparatus. Presbyopia has thus been described as a condition of multifactorial origin [62]. It is unclear whether these changes occur independently or as a consequence of each other. For example, the increased hardness of the lens could theoretically be a consequence of the reduced ciliary muscle mobility. Alternatively, the reduced mobility could be due to the loss of tension from the lens. However, both could well develop independently and contribute as separate factors to the loss of accommodation with age.

Summary for the Clinician

- All parts of the accommodative apparatus show age-related morphological and functional changes.
- Hardening of the lens substance is very likely a major contributor to presbyopia.
- Presbyopia may be of multifactorial origin.

8.6 Experimental Studies of Accommodation In Vivo

The results of laboratory examinations on enucleated eyes can be influenced by postmortal degradation. [63]. Therefore, it has been attempted for a long time to gain information about human accommodation from animal models [64, 65]. Finding a suitable model is difficult because there are considerable differences between species regarding the existence, the mechanism, and the amplitude of accommodation [66]. An accommodative apparatus comparable to the human one has only been found in primates. The most frequently used animal model for human accommodation is the rhesus monkey. It is especially suitable for accommodation studies because the development of presbyopia, and also other aging processes in relation to its total life span, run more or less parallel to the development of presbyopia in humans [67]. In iridectomized rhesus monkeys, important findings in the physiology of accommodation were gained. By means of electrodes implanted into the Edinger–Westphal nucleus, accommodation can be stimulated directly with electrical impulse without a visual stimulus. In this way, the mechanical behavior of the accommodative plant can be investigated without the interference of central feedback mechanisms. This is helpful for the differentiation of mechanical and neurological changes in the development of presbyopia and for measurement of the effects of aging of the different parts of the accommodative plant. With such experiments, the linear dependence of biometric data such as lens thickness, lens diameter, and anterior chamber depth on the accommodative amplitude have been shown [68, 69], and the relationship between amplitude and dynamics of accommodation have been characterized [70, 71].

Summary for the Clinician

- The knowledge about accommodation has been advanced by experimental studies in primates.
- Midbrain stimulation in anesthetized monkeys can deliver information about the behavior of the accommodative apparatus without visual feedback.

8.7 Surgical Restoration of Accommodation in the Presbyopic Eye

8.7.1 Pseudo-Accommodative Procedures

Recently, efforts have been intensified to find a surgical treatment for the restoration of accommodation in the presbyopic eye. Such procedures are increasingly used to treat patients, although not all the details of the physiology of accommodation and presbyopia are sufficiently clear.

Nowadays, several surgical procedures for the correction of presbyopia are used, such as

- Unilateral myopization (so-called monovision)
- Implantation of a bi- or multifocal intraocular lens
- application of laser or thermal energy to the cornea to achieve multifocality

These are not intended to restore true accommodation but to improve near vision by enhancing the depth of field. This is often well tolerated but can nevertheless result in problems such as reduced stereoscopic vision, reduced contrast sensitivity, glare, or unwanted photic phenomena. Also, these methods do not provide equally good vision over a large range of distances. Especially, the correction for intermediate distances is often judged unsatisfactory [72–74].

8.7.2 Procedures Intended to Restore Accommodation

8.7.2.1 Scleral Expansion

To restore accommodation in the presbyopic eye, scleral expansion has been suggested. This is surgical cuts into the sclera over the ciliary body for enlargement of the space available to the ciliary muscle and improvement of lens mobility. This is aided by polymethyl-methacrylate (PMMA) segments implanted into the sclera. This is based on an alternative theory of accommodation and presbyopia suggesting (as mentioned above) that the lens equator is pulled outward during accommodation, that the equatorial lens diameter increases with age, and that the lens retains its accommodative ability [75]. All of these suggestions are questionable in light of experimental evidence [5, 24, 25, 38, 68, 76–78]. Clinical studies reported an improvement of subjective near vision following scleral expansion [79]. This improvement was, however, variable and in many cases no longer detectable some months after the procedure. Reports of objective measurement of accommodation in patients treated with scleral expansion did not find a higher accommodative amplitude than in age-matched untreated patients [80].

8.7.2.2 Accommodative Intraocular Lenses

Accommodative intraocular lenses are designed to translate the movement of the ciliary muscle in the process of accommodation into a change of focus of the eye. Most accommodative IOLs now implanted rely on a forward shift of the IOL optic. By some mechanism, the contraction of the ciliary muscle is supposed to effect a movement of the lens optic anteriorly and thus increase the optical power of the eye. With such IOLs, subjective accommodative amplitudes of more than 2D and spectacle independence of about 80% of patients have been reported [81, 82]. Objective measurements of lens mobility yielded equivocal results [83, 84]. Further developments include dual-optic IOLs which are intended to achieve higher amplitudes and better filling of the capsular bag by movement of two lens optics [85]. These are still undergoing clinical testing. The amount of accommodative efficacy in accommodative IOLs depends on a number of factors, including optical power of the lens optic and position in the capsular bag. The necessary instability of accommodative IOLs which allows them to move inside this capsular bag increases the danger of secondary cataract as well as unwanted postoperative changes of IOL position and refraction [86].

8.7.2.3 Experimental Procedures

Some of the concepts of presbyopia reversal are still in an experimental state. These include the restoration of lens elasticity by treatment with a femtosecond laser inside the lens without opening the capsule [87] and the refilling of the capsular bag with an elastic material with refractive properties similar to the human lens [88]. Theoretically, this would be closest to the natural accommodation mechanism and, given a fully functional extralenticular accommodative apparatus, could restore a juvenile accommodative ability

8.7.3 Evaluation of Surgical Procedures to Restore Accommodation

For the evaluation and further development of these methods, the results of clinical and experimental research must be considered and taken into account, especially with respect to the changes in lens and ciliary muscle function with age and the relation of accommodation and pseudo-accommodation. Many of the currently used surgical techniques to restore accommodation rely on assumptions about the accommodative mechanism that are not supported by experimental evidence. For this

reason, the reported improvement in near vision may in some cases be due to unintended effects. It has, for example, been suggested that the subjective improvement in near visual acuity achieved with scleral expansion procedures is a result of induced asymmetry or displacement of the crystalline lens [89]. It has also been suggested that the success in restoring near vision achieved with certain types of accommodative intraocular lenses is more likely due to a change in wavefront aberration caused by deformation or bending of the intraocular lens optic than to the anterior displacement. If the effect of surgical interventions to restore accommodation is based on unintended side effects, the predictability and stability of such procedures is called into question. For this reason, thorough evaluation of new surgical procedures is mandatory. Only a correlation of standardized objective and subjective measurement methods can show if and how a surgical procedure can reliably restore near vision in a presbyopic eye.

Summary for the Clinician

- Surgical methods for presbyopia treatment can be pseudo-accommodative or accommodative.
- Some accommodative procedures rely on concepts which are not proven or which contradict experimental evidence about the accommodative mechanism.
- To evaluate the ability of a procedure to restore accommodation, objective functional measurements are mandatory.
- In the future, procedures will emerge that may come closer to the goal of restoring accommodation.

References

1. Helmholtz von HH, Southall JPC (1911) *Handbuch der Physiologischen Optik*. The Optical Society of America, Menasha, Wisconsin
2. Tamm ER, Lütjen-Drecoll E (1996) Ciliary body. *Microsc Res Tech* 33:390
3. Rohen JW (1979) Scanning electron microscopic studies of the zonular apparatus in human and monkey eyes. *Invest Ophthalmol Vis Sci* 18:133
4. Glasser A, Croft MA, Brumback L, et al (2001) Ultrasound biomicroscopy of the aging rhesus monkey ciliary region. *Optometr Vis Sci* 78:417
5. Glasser A, Campbell MC (1998) Presbyopia and the optical changes in the human crystalline lens with age. *Vision Res* 38:209–229
6. Bernal A, Parel JM, Manns F (2006) Evidence for posterior zonular fiber attachment on the anterior hyaloid membrane. *Invest Ophthalmol Vis Sci* 47:4708–471
7. Atchison DA, Smith G (2002) *Optics of the human eye*. Butterworth-Heinemann, Oxford
8. Fincham EF (1925) The changes in the form of the crystalline lens in accommodation. *Trans Opt Soc* 26:240
9. Taylor VL, al-Ghoul KJ, Lane CW, et al (1996) Morphology of the normal human lens. *Invest Ophthalmol Vis Sci* 37:1396
10. von Helmholtz H (1855) Über die Accommodation des Auges. *Graefes Arch Ophthalmol* 1(Abst II):1–74
11. Lütjen-Drecoll E, Tamm E, Kaufman PL (1988) Age-related loss of morphologic responses to pilocarpine in rhesus monkey ciliary muscle. *Arch Ophthalmol* 106:1591–1598
12. Fincham EF (1937) The mechanism of accommodation. *Br J Ophthalmol Monogr* 8:7–76
13. Coleman DJ (1970) Unified model for accommodative mechanism. *Am J Ophthalmol* 69:1063
14. Duane A (1925) Are the current theories of accommodation correct? *Am J Ophthalmol* 8:196
15. Strenk SA, Strenk LM, Koretz JF (2005) The mechanism of presbyopia. *Prog Retin Eye Res* 24:379
16. Coleman DJ (1986) On the hydraulic suspension theory of accommodation. *Trans Am Ophthalmol Soc* 84:846–868
17. Koretz JF, Handelman GH (1982) Model of the accommodative mechanism in the human eye. *Vision Res* 22:917
18. Tscherning M (1899) The theory of accommodation. *Ophthalmic Rev* 18:91
19. Coleman DJ, Fish SK (2001) Presbyopia, accommodation, and the mature catenary. *Ophthalmology* 108:1544
20. Fisher RF (1982) The vitreous and lens in accommodation. *Trans Ophthalmol Soc U K* 102:318
21. Fisher RF (1983) Is the vitreous necessary for accommodation in man? *Br J Ophthalmol* 67:206
22. Albrecht M, Eisner G (1982) The hyalo-capsular zonula. *Graefes Arch Clin Exp Ophthalmol* 218:88–92
23. Schachar RA, Black TD, Kash RL, et al (1995) The mechanism of accommodation and presbyopia in the primate. *Ann Ophthalmol* 27:58
24. Croft MA, Glasser A, Heatley G, et al (2006) The zonula, lens, and circumlental space in the normal iridectomized rhesus monkey eye. *Invest Ophthalmol Vis Sci* 47:1087–1095
25. Glasser A, Kaufman PL (1999) The mechanism of accommodation in primates. *Ophthalmology* 106:863–872
26. Kotulak JC, Morse SE (1995) The effect of perceived distance on accommodation under binocular steady-state conditions. *Vision Res* 35:791
27. Shapiro JA, Kelly JE, Howland HC (2005) Accommodative state of young adults using reading spectacles. *Vision Res* 45:233

28. Stark LR, Atchison DA (1994) Subject instructions and methods of target presentation in accommodation research. *Invest Ophthalmol Vis Sci* 35:528
29. Takeda T, Hashimoto K, Hiruma N, et al (1999) Characteristics of accommodation toward apparent depth. *Vision Res* 39:2087
30. Quinlan DJ, Culham JC (2007) fMRI reveals a preference for near viewing in the human parieto-occipital cortex. *Neuroimage* 36:167–187
31. Kaufman PL, Rohen JW, Gabelt BT, et al (1991) Parasympathetic denervation of the ciliary muscle following pan-retinal photocoagulation. *Curr Eye Res* 10:437–455
32. Kasthurirangan S, Glasser A (2005) Characteristics of pupil responses during far-to-near and near-to-far accommodation. *Ophthalmic Physiol Opt* 25:328
33. Mullen EA, Gilmartin B, Wolffsohn JS (2005) Sympathetic innervation of ciliary muscle and oculomotor function in emmetropic and myopic young adults. *Vision Res* 45:1641
34. Nanavaty MA, Vasavada AR, Patel AS, et al (2006) Analysis of patients with good uncorrected distance and near vision after monofocal intraocular lens implantation. *J Cataract Refract Surg* 32:1091–1097
35. Ostrin LA, Glasser A (2004) Accommodation measurements in a prepresbyopic and presbyopic population. *J Cataract Refract Surg* 30:1435
36. Duane A (1912) Normal values of the accommodation at all ages. *J Am Med Assoc* 59:1010–1012
37. Gullstrand A, Southall JPC (1909) The mechanism of accommodation. In: Helmholtz's treatise on physiological optics. Dover, New York, p 382
38. Glasser A, Campbell MC (1999) Biometric, optical and physical changes in the isolated human crystalline lens with age in relation to presbyopia. *Vision Res* 39:1991–2015
39. Heys KR, Cram SL, Truscott RJ (2004) Massive increase in the stiffness of the human lens nucleus with age: the basis for presbyopia? *Mol Vis* 10:956–963
40. Weeber HA, Eckert G, Soergel F, et al (2005) Dynamic mechanical properties of human lenses. *Exp Eye Res* 80:425–434
41. Weeber HA, Eckert G, Pechhold W, et al (2007) Stiffness gradient in the crystalline lens. *Graefes Arch Clin Exp Ophthalmol* 245:1357–1366
42. Weeber HA, van der Heijde RG (2007) On the relationship between lens stiffness and accommodative amplitude. *Exp Eye Res* 85:602–607
43. McGinty SJ, Truscott RJ (2006) Presbyopia: the first stage of nuclear cataract? *Ophthalmic Res* 38:137
44. Bito LZ, Miranda OC (1989) Accommodation and Presbyopia. *Ophthalmol Annu* 21:103
45. Cook CA, Koretz JF, Pfahnl A, et al (1994) Aging of the human crystalline lens and anterior segment. *Vision Res* 34(22):2945
46. Farnsworth PN, Shyne SE (1979) Anterior zonular shifts with age. *Exp Eye Res* 28:291
47. Koretz JF, Handelman GH (1988) How the human eye focuses. *Sci Am* 259:92
48. Pierscionek B, Weale RA (1995) Presbyopia – a maverick of human aging. *Arch Gerontol Geriatr* 20:229
49. Fisher RF (1969) Elastic constants of the human lens capsule. *J Physiol* 201:1
50. Krag S, Olsen T, Andreassen TT (1997) Biomechanical characteristics of the human anterior lens capsule in relation to age. *Invest Ophthalmol Vis Sci* 38:357
51. Ziebarth NM, Borja D, Arrieta E, Aly M, Manns F, Dortonne I, Nankivil D, Jain R, Parel JM (2008) Role of the lens capsule on the mechanical accommodative response in a lens stretcher. *Invest Ophthalmol Vis Sci* 49:4490–4496.
52. Croft MA, McDonald JP, James RJ, et al (2008) Surgical intervention and accommodative responses: I. Centripetal ciliary body, capsule and lens movement in rhesus monkeys of varying age. *Invest Ophthalmol Vis Sci*
53. Tamm E, Croft MA, Jungkunz W, et al (1992) Age-related loss of ciliary muscle mobility in the rhesus monkey. Role of the choroid. *Arch Ophthalmol* 110:871–876
54. Lütjen-Drecoll E, Tamm E, Kaufman PL (1988) Age changes in rhesus monkey ciliary muscle: light and electron microscopy. *Exp Eye Res* 47:885
55. Gabelt BT, Kaufman PL, Polansky JR (1990) Ciliary muscle muscarinic binding sites, choline acetyltransferase, and acetylcholinesterase in aging rhesus monkeys. *Invest Ophthalmol Vis Sci* 31:2431
56. Poyer JF, Kaufman PL, Flugel C (1993) Age does not affect contractile responses of the isolated rhesus monkey ciliary muscle to muscarinic agonists. *Curr Eye Res* 12:413
57. Fisher RF (1973) Presbyopia and the changes with age in the human crystalline lens. *J Physiol* 228:765–779
58. Strenk SA, Semmlow JL, Strenk LM, et al (1999) Age-related changes in human ciliary muscle and lens: a magnetic resonance imaging study. *Invest Ophthalmol Vis Sci* 40:1162
59. Tamm S, Tamm E, Rohen JW (1992) Age-related changes of the human ciliary muscle. A quantitative morphometric study. *Mech Ageing Dev* 62:209–221
60. Tamm E, Lütjen-Drecoll E, Jungkunz W, et al (1991) Posterior attachment of ciliary muscle in young, accommodating old, presbyopic monkeys. *Invest Ophthalmol Vis Sci* 32:1678–1692
61. Koretz JF, Cook CA, Kuszak JR (1994) The zones of discontinuity in the human lens: development and distribution with age. *Vision Res* 34:2955
62. Atchison DA (1995) Accommodation and presbyopia. *Ophthalmic Physiol Opt* 15:255
63. Weale RA (1999) On potential causes of presbyopia [letter]. *Vision Res* 39:1263

64. Crampton P (1813) The description of an organ by which the eyes of birds are accommodated to the different distances of objects. *Thompson's Ann Phil* 1:170
65. Müller H (1857) Über den Accommodations-Apparat im Auge der Vögel, besonders der Falken. *Archiv für Ophthalmologie* 3:25–55
66. Glasser A, Guthoff R, Ludwig K (2003) How other species accommodate. In: *Current aspects of human accommodation II*. Kaden Verlag, Heidelberg, p 13
67. Bito LZ, Kaufman PL, DeRousseau CJ, et al (1987) Presbyopia: an animal model and experimental approaches for the study of the mechanism of accommodation and ocular ageing. *Eye* 1:222–230
68. Glasser A, Wendt M, Ostrin L (2006) Accommodative changes in lens diameter in rhesus monkeys. *Invest Ophthalmol Vis Sci* 47:278
69. Vilupuru AS, Glasser A (2005) The relationship between refractive and biometric changes during Edinger-Westphal stimulated accommodation in rhesus monkeys. *Exp Eye Res* 80:349–360
70. Baumeister M, Wendt M, Glasser A (2008) Edinger-Westphal stimulated accommodative dynamics in anesthetized, middle-aged rhesus monkeys. *Exp Eye Res* 86:25–33
71. Vilupuru AS, Glasser A (2002) Dynamic accommodation in rhesus monkeys. *Vision Res* 42:125–141
72. Kohnen T, Derhartunian V (2007) [Apodized diffractive optic. New concept in multifocal lens technology]. *Ophthalmologie* 104:899–904, 906–897
73. Leyland M, Pringle E (2006) Multifocal versus monofocal intraocular lenses after cataract extraction. *Cochrane Database Syst Rev*:CD003169
74. Schmidinger G, Geitzenauer W, Hahsle B, et al (2006) Depth of focus in eyes with diffractive bifocal and refractive multifocal intraocular lenses. *J Cataract Refract Surg* 32:1650–1656
75. Schachar RA (1992) Cause and treatment of presbyopia with a method for increasing the amplitude of accommodation. *Ann Ophthalmol* 24:445
76. Croft MA, Glasser A, Heatley G, et al (2006) Accommodative ciliary body and lens function in rhesus monkeys, I: normal lens, zonule and ciliary process configuration in the iridectomized eye. *Invest Ophthalmol Vis Sci* 47:1076–1086
77. Strenk SA, Strenk LM, Semmlow JL, et al (2004) Magnetic resonance imaging study of the effects of age and accommodation on the human lens cross-sectional area. *Invest Ophthalmol Vis Sci* 45:539
78. Wendt M, Croft MA, McDonald J, et al (2008) Lens diameter and thickness as a function of age and pharmacologically stimulated accommodation in rhesus monkeys. *Exp Eye Res* 86:746–752
79. Malecaze FJ, Gazagne CS, Tarroux MC, et al (2001) Scleral expansion bands for presbyopia. *Ophthalmology* 108:2165
80. Ostrin LA, Kasthurirangan S, Glasser A (2004) Evaluation of a satisfied bilateral scleral expansion band patient. *J Cataract Refract Surg* 30:1445
81. Cumming JS, Colvard DM, Dell SJ, et al (2006) Clinical evaluation of the Crystalens AT-45 accommodating intraocular lens: results of the U.S. Food and Drug Administration clinical trial. *J Cataract Refract Surg* 32:812–825
82. Macsai MS, Padnick-Silver L, Fontes BM (2006) Visual outcomes after accommodating intraocular lens implantation. *J Cataract Refract Surg* 32:628–633
83. Findl O, Leydolt C (2007) Meta-analysis of accommodating intraocular lenses. *J Cataract Refract Surg* 33:522–527
84. Koepl C, Findl O, Menapace R, et al (2005) Pilocarpine-induced shift of an accommodating intraocular lens: AT-45 Crystalens. *J Cataract Refract Surg* 31:1290
85. McLeod SD (2006) Optical principles, biomechanics, and initial clinical performance of a dual-optic accommodating intraocular lens (an American Ophthalmological Society thesis). *Trans Am Ophthalmol Soc* 104:437–452
86. Menapace R, Findl O, Kriechbaum K, et al (2007) Accommodating intraocular lenses: a critical review of present and future concepts. *Graefes Arch Clin Exp Ophthalmol* 245:473–489
87. Ripken T, Oberheide U, Fromm M, et al (2007) fs-Laser induced elasticity changes to improve presbyopic lens accommodation. *Graefes Arch Clin Exp Ophthalmol* 246:897–906
88. Koopmans SA, Terwee T, Glasser A, et al (2006) Accommodative lens refilling in rhesus monkeys. *Invest Ophthalmol Vis Sci* 47:2976–2984
89. Hunter JJ, Campbell MC (2006) Potential effect on the retinoscopic reflex of scleral expansion surgery for presbyopia. *Optometr Vis Sci* 83:649

Corneal Approaches to the Treatment of Presbyopia

Shazia S. Ahmed, Mitchell P. Weikert

Core Messages

- There are multiple approaches to the correction of presbyopia. These include refractive surgical ablation, corneal inlay devices, and conductive keratoplasty. The goal is to provide a safe and effective way to correct near vision while maintaining good distance visual acuity.
- The success of monovision LASIK and PRK depend upon interocular blur suppression. A preoperative contact lens trial can help select for optimal candidates.
- Multifocal ablation or ‘PresbyLASIK’ provides discrete levels of pseudo-accommodation in each eye. While clinical trial results are promising, the potential for increased glare, haloes, and compromised visual quality at all focal points is a concern.
- Corneal inlay devices correct for presbyopia either by creating a pinhole effect, a technique utilized by the Acufocus corneal inlay, or by altering corneal curvature, as in the case of the Presbylens. Both procedures are reversible and outcome is dependent on optimal placement of the devices.
- Conductive keratoplasty alters the cornea using radiofrequency-based energy to achieve a ‘blended vision.’ While easy to perform, there is a limited treatment range and thus a limited population of patients that may benefit from this technique.

9.1 Introduction

As the population segment between the ages of 45 and 55 grows, so will the demand for presbyopic correction. Current technology is well equipped to meet the visual demands of young patients with refractive error and older patients with cataracts. However, the options for those that fall between these extremes (i.e., the presbyope) are still evolving. Presbyopia results from a decrease in the accommodative capacity of the crystalline lens. While there is no way to directly restore this ability, intraocular lenses are currently available or in development that can provide both distance and near vision. Unfortunately, refractive lens exchange is a very invasive procedure that carries certain risks, such as endophthalmitis and retinal detachment.

Other, less invasive techniques are becoming available that seek to improve uncorrected near vision by altering the eye’s refractive power at the cornea. This chapter will explore three of these surgical technologies:

excimer laser refractive ablation, corneal inlay devices, and conductive keratoplasty.

9.2 Monovision Approach to Presbyopia Correction

9.2.1 Introduction

One of the most commonly utilized approaches to treating presbyopia relies on the creation of monovision, where one eye, typically the dominant eye, is focused for distance and the other eye is focused for near. Ideally, this should create a clear continuous range of vision free of any image blur. Success of this procedure relies on a patient’s ability to suppress interocular blur [1]. According to Jain et al [2], patients with alternating ocular dominance are better able to suppress interocular blur, thus leading to a higher success rate compared to patients with strong sighting preferences.

Even if well tolerated, monovision has the potential to compromise certain aspects of visual function. First, binocular visual acuity may be reduced by 0.04–0.06 logMAR unit in conditions of high illumination (250 cd m^{-2}) and by 0.10 logMAR unit in conditions of low illumination (5 cd m^{-2}) [3]. Thus, a patients' night vision may be significantly impacted. Second, patients may experience a decrease in stereopsis. A mean decrease in stereopsis of 36.6 arc seconds has been documented in monovision patients with a further reduction in stereopsis of 50–62 arc seconds in patients with poor adaptation [2]. Third, contrast sensitivity can also be compromised with increasing monocular defocus [4, 5]. Specifically, visual resolution at higher spatial frequencies can be affected making this a less than desirable option for people engaged in fine detailed work.

9.2.2 Patient Selection

The premise of the successful monovision patient is contingent upon careful patient selection. A discussion of the patients' visual demands in terms of their occupation and hobbies needs to occur in order to determine whether the patient is a suitable monovision candidate. If the ability to adapt to monovision is in question, the patient can be offered a monovision contact lens trial. The non-dominant eye is typically targeted for 1–2 D of myopia. An adequate time frame, typically 1–3 weeks, is provided to assess whether the patient can adapt to the visual compromises of this approach. A successful contact lens trial can increase the surgical success rate of monovision laser in situ keratomileusis (LASIK) from 69 to 81% [6]. In addition, since binocular visual acuity is compromised with monovision correction, it is extremely important to correct for any residual astigmatic error which can further degrade binocular visual acuity in the monovision patient [7].

9.2.3 Monovision LASIK

Despite its limitations, the initial success of monovision in the contact lens population has paved the way for its implementation in the arena of refractive surgery. While monovision has been utilized in laser vision correction for several years, its use has always been 'off-label', and the treatment for the near eye could only be designed using conventional, refraction-based ablation (not wavefront-guided).

The CustomVue monovision LASIK trial (Advanced Medical Optics) prospectively assessed the visual outcomes and satisfaction associated with this procedure using wavefront-guided ablations for both the near and

distance eyes. Presbyopic patients with myopia were recruited with the goal of targeting the dominant eye for emmetropia and the non-dominant eye for -1.25 to -2.00 D of myopia. Prior to surgical correction, patients had to demonstrate monovision acceptance with a 1-week contact lens trial. Ninety-three percent of patients achieved binocular uncorrected distance visual acuity of 20/20 or better at the 12-month visit. Likewise, 87% achieved 20/20 or better binocular uncorrected intermediate vision and 92% achieved 20/20 or better binocular uncorrected near vision at 12 months (Fig. 9.1). In addition, 86% of patients demonstrated binocular uncorrected distance and near visual acuities of 20/20 or better (Fig. 9.2). Patient satisfaction with monovision LASIK was likewise high. At the 12-month visit, 98% of patients said they would elect to have monovision treatment again. The procedure overall was relatively safe and no patient lost greater than two lines of best spectacle-corrected visual acuity (BSCVA) [8].

A study comparing monovision LASIK results in myopes and hyperopes similarly revealed excellent results [9]. One hundred percent of monovision patients in both groups achieved 20/30 or better vision in the distance eye and J2 or better vision in the near eye. Despite high satisfaction scores, patient surveys revealed increased difficulty with light perception- and depth perception-related activities in the monovision hyperopes in comparison to the monovision myopes, distance myopes, and distance hyperopes. In addition, a larger percentage of monovision hyperopes required enhancements compared to the other three subgroups. While successful monovision can be achieved in hyperopes, they may experience more side effects and need enhancements more often to achieve proper correction.

The risks of monovision LASIK are no different than LASIK correction for emmetropia, including complications with flap creation, diffuse lamellar keratitis, dry eyes, glare/haloes, and reduced contrast sensitivity [10–15]. Patients may require spectacle correction for certain activities, such as night driving or extended reading.

9.2.4 Monovision Photorefractive Keratectomy

Given the high level of success with monovision LASIK, there is little reason to believe that similar results with photorefractive keratectomy cannot be achieved. In a limited study of 21 myopic presbyopic patients by Wright and colleagues, 95.3% of patients achieved a binocular uncorrected distance and near visual acuity of 20/25 or better. A mean patient satisfaction rate of 86% was achieved with photorefractive keratectomy (PRK)-induced monovision [16].

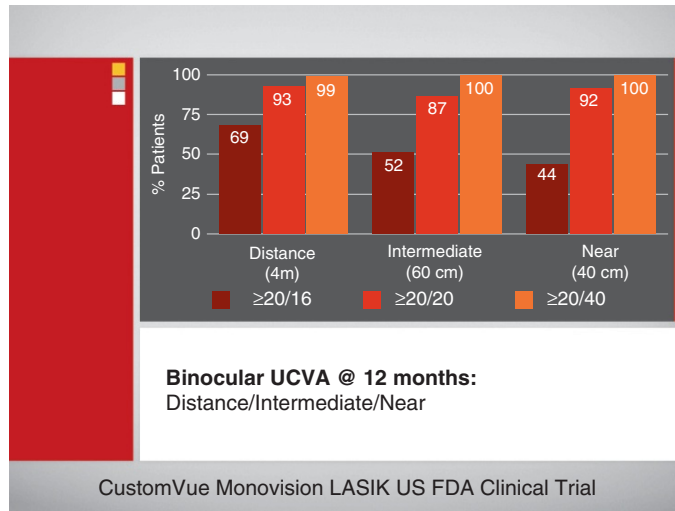


Fig. 9.1 CustomVue Monovision. Binocular uncorrected visual acuity at 12 months for distance, intermediate, and near vision

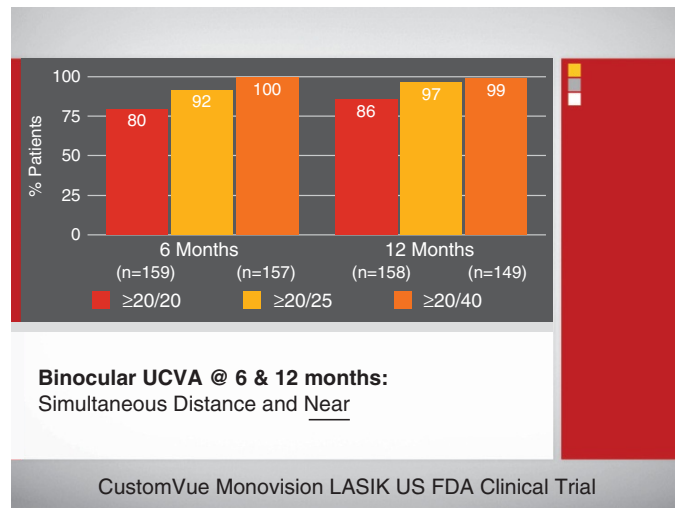


Fig. 9.2 CustomVue Monovision. Binocular uncorrected visual acuity at 6 and 12 months for simultaneous distance and near vision

Summary for the Clinician

- The success of monovision depends on the patient's ability to suppress interocular blur. Careful patient selection combined with a contact lens trial for candidates whose ability to adapt is in question can help optimize surgical success.
- Monovision LASIK performed in myopic presbyopes appears to have excellent visual results. Hyperopic presbyopes may require more enhancements and experience more side effects.
- Monovision PRK patients should be able to achieve visual results similar to the monovision LASIK group.

9.3 Multi-focal Presbyopic LASIK

9.3.1 Introduction

Instead of using different refractive states in each eye to provide a range of vision, presbyopic LASIK (also known as PresbyLASIK) uses multifocal ablation patterns to provide discrete levels of pseudo-accommodation within the eye. Concentric rings of ablation alternate to correct both distance and near vision. The central zone can be chosen to target either distance or near; however, with this modality, intermediate vision may suffer. The main advantage of PresbyLASIK is that it allows for multiple simultaneous refractive states to exist. One drawback of this method is that visual quality may suffer at all distances. Patients may also experience glare and haloes.

9.3.2 Outcome

To study the visual outcomes and patient satisfaction associated with multifocal ablation, a multifocal ablation clinic trial is underway. In the Hyperopic Presbyopia Correction Trial (Advanced Medical Optics), the dominant eye receives a full hyperopic wavefront-guided distance correction, while the non-dominant eye is treated with a hyperopic multifocal ablation. The multifocal ablation consists of a central zone steepened for near vision, with a flatter peripheral zone targeted for distance (Fig. 9.3). The size of the central zone is varied according to pupil size. Iris registration with compensation for pupil centroid

shift and ocular rotation is crucial for accurate placement of the multifocal ablation. Given the differential curvature produced by the multifocal ablation, accurate centration is vital to maximize near visual function and to prevent undesired aberrations.

Six-month data from the multifocal eye reveals that 100% of patients had an uncorrected distance visual acuity of 20/25 or better. Uncorrected near visual acuity was likewise impressive, with a 100% of patients achieving 20/20 or better vision in the multifocal eye. Binocular uncorrected distance and near visual acuity of 20/20 or better was noted in 100% of patients (Fig. 9.4). Patient satisfaction surveys have also confirmed an increased




Fig. 9.3 PresbyLASIK. Central steepening of the cornea with multifocal ablation

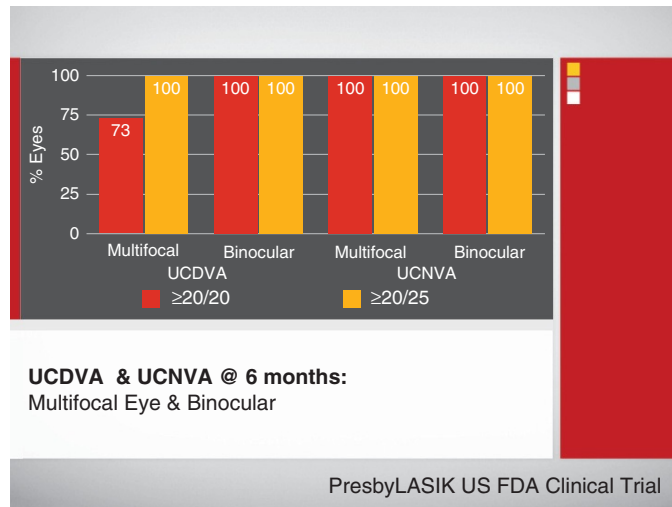


Fig. 9.4 PresbyLASIK. Uncorrected distance and near vision at 6 months: multifocal eye and binocular

level of satisfaction with distance and near vision correction following surgery [17].

The early results of this technology are promising. The risks of this procedure are similar to those of LASIK monovision, but may have a slightly higher potential for haloes. Currently other centers are investigating the outcomes of bilateral multifocal treatments with PRK.

Summary for the Clinician

- PresbyLASIK uses a multifocal ablation pattern to create discrete levels of pseudo-accommodation. Visual acuity data appears very promising in presbyopic hyperopes. Concern exists regarding the quality of vision at these multiple refractive states.

9.4 Intracorneal Inlays

9.4.1 Acufocus ACI 7000 Corneal Inlay

The Acufocus ACI 7000 is a potentially reversible alternative for correcting presbyopia, which uses a corneal inlay to create a pinhole effect (Fig. 9.5). The inlay is a 10- μ m thick disc made of polyvinylidene fluoride, an opaque biocompatible polymer that softens with heat and hardens under cold conditions. The device contains microscopic pores across its entire surface to facilitate the flow of nutrients between the corneal tissue on either side. The thin circular disc is placed under a standard LASIK flap. It has a total diameter of 3.8 mm with a 1.6-mm central opening that isolates paraxial light rays to function as a pinhole. During distance activities, the pupil is dilated beyond the opaque ring allowing peripheral rays to enter the eye. When the subject engages in near activities, the

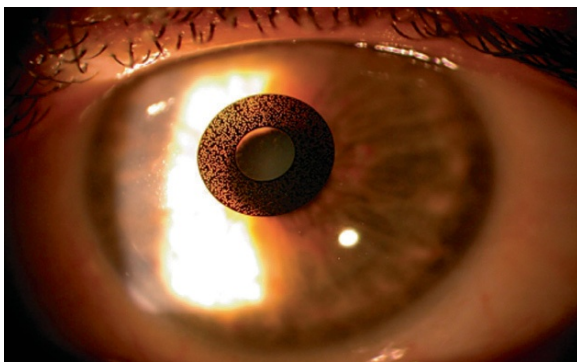


Fig. 9.5 Clinical appearance of the Acufocus ACI 7000 corneal inlay

pupil constricts to a diameter smaller than that of the Acufocus inlay. Peripheral rays are blocked with only paraxial rays entering the eye, thereby increasing depth-of-focus and improving near vision. This approach has several advantages. It is minimally invasive, reversible, and utilizes a biocompatible material. It may also be combined with LASIK for simultaneous correction of refractive error and presbyopia or placed under a preexisting LASIK flap in a patient who has undergone prior refractive surgery. Six-month follow-up results from the current clinical trial reveal a mean uncorrected distance and near visual acuity of 20/20 [18].

9.4.2 Intracorneal Hydrogel Lenses

Another variant on corneal inlay technology is the PresbyLens™ (ReVision Optics, Lake Forest, CA). The PresbyLens is a hydrogel inlay with a diameter of 1.5 mm and an edge thickness of 10 μ m that increases centrally up to 24–40 μ m. Unlike the Acufocus, this inlay works by altering the radius of curvature of the anterior cornea to achieve presbyopic correction. These hydrogel lenses are implanted under a standard LASIK flap within the pupillary aperture. They are biocompatible and highly permeable, allowing water and nutrients to be exchanged throughout the depth of the cornea. However, while this permeability is beneficial to the health of the cornea, it can also lead to variations in the thickness and refractive power of the implant.

A current clinical FDA trial has yielded 3-month postoperative data. Myopic presbyopes were selected to receive bilateral myopic LASIK. At the time of surgery, the inlay was placed in the non-dominant eye, in a 'monovision-like' manner. Uncorrected distance visual acuity (UCDVA) with the dominant eye (no implant) was 20/20 or better in 79% of eyes and 20/40 or better for 100% of eyes. UCDVA in the non-dominant eye (PresbyLens implant) was 20/20 or better in 7% and 20/40 or better in 64%. Under conditions of binocularity, 86% of eyes experienced UCDVA of 20/20 or better and 100% of eyes were 20/40 or better. Uncorrected near visual acuity (UCNVA) at 3 months in the non-dominant PresbyLens eye was 20/25 in 21% of eyes and 20/40 or better in 86% of eyes. Under binocular conditions, 50% of eyes had an UCNVA of 20/25 and 86% had an uncorrected near vision of 20/40 or better. No eye achieved a near vision correction of 20/20 (Fig. 9.6) [19].

This procedure can be viewed as an adjunctive enhancement to LASIK and is adjustable and reversible. There is limited experience with this procedure and the 3-month uncorrected near visual acuity data were less impressive when compared to other options, such as monovision

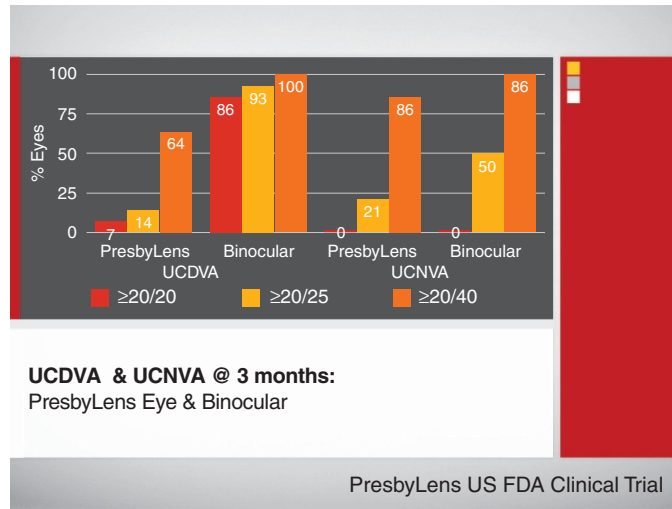


Fig. 9.6 PresbyLens. Uncorrected distance and near visual acuity at 6 months: implant eye and binocular

and PresbyLASIK. Achieving better uncorrected near vision may be dependent upon the optimization of inlay placement.

Summary for the Clinician

- Intracorneal inlays are a safe and reversible approach to presbyopia correction.
- The Acufocus ACI 7000 relies upon the creation of a pinhole effect while the PresbyLens inlay alters the anterior corneal curvature to achieve presbyopic correction.
- The PresbyLens inlay needs to be further optimized for improved acuity at distance and near.

6-, 7-, and 8-mm treatment zones for correction of presbyopia. Eight spots at the 6 mm optical zone (OZ) will correct 0.75–0.875 D of hyperopia. Treatments can be titrated with the addition of more spots and rings of increasing diameters. For example, the correction of 3 D of hyperopia would require 8 spots at the 6 mm OZ, 16 spots at the 7 mm OZ, and another 8 spots at the 8 mm OZ [20].

The pressure exerted by the probe during spot placement in conventional CK typically produces a 5–7 mm dimple in the cornea. A newer CK technique, known as ‘light touch,’ utilizes less pressure to produce a 2-mm dimple in the cornea. This technique is currently preferred because it improves energy delivery and creates a greater effect while utilizing fewer spots. It is associated with

9.5 Conductive Keratoplasty

9.5.1 Introduction

Conductive keratoplasty (CK) was initially approved for the treatment of spherical hyperopia in 2002. In 2004, the indications for CK were expanded to include treatment of presbyopia in emmetropes and hyperopes. The procedure involves delivering electromagnetic energy at radio frequencies of 350 kHz to the cornea via a needle-like probe that is 90 μ in diameter and 450 μ long. The energy increases the tissue temperature in the cornea, leading to collagen shrinkage. When discrete spots are placed in rings around the mid-periphery of the cornea, localized tissue contraction steepens the central cornea increasing its refractive power. The treatment algorithm is designed to deliver energy at

Table 9.1 Comparison of the different approaches towards presbyopia correction

	Reversible	Monovision	Implant	Near Vision	Limited Range	Function
Monovision LASIK/PRK	-	+	-	+	-	-
PresbyLASIK	-	-	-	+	-	+/-
Acufocus	+	-	+	+	-	+
PresbyLens	+	+	+	-	-	-
NearVision CK	-	+	-	+	+	-

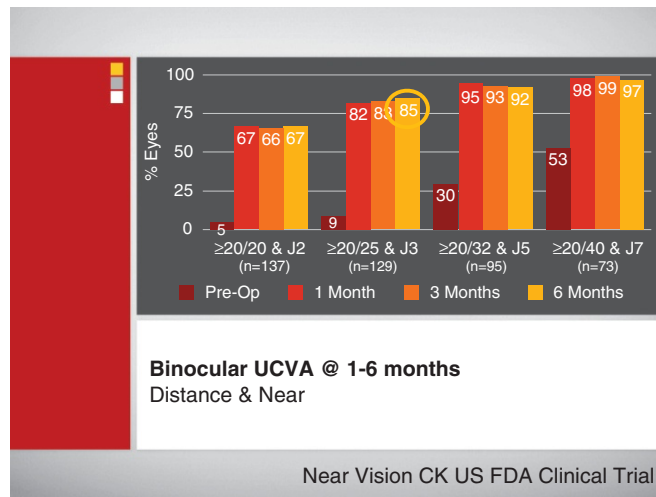


Fig. 9.7 Near Vision CK. Binocular uncorrected distance and near visual acuity at 1–6 months

increased predictability, faster recovery, and decreased induction of astigmatism.

9.5.2 Outcome

An FDA clinical trial was undertaken to evaluate visual outcomes and patient satisfaction with this procedure. Inclusion criteria for the ViewPoint CK trial included age >40 years, preoperative spherical equivalent manifest refraction of plano to +2.00 D, and preoperative astigmatism of <0.75 D. Monovision conductive keratoplasty was carried out on the non-dominant eye with a target refraction of up to -2.00 D. Six months following surgery, 85% of patients were able to achieve binocular UCVA of 20/25 and binocular UCVA of J3, a combination that provides functional vision for a majority of distance and near activities (Fig. 9.7). In addition, 76% of patients at the 6-month visit felt very satisfied with the visual outcome of the procedure. In evaluating the safety of the procedure, no eye lost two or more lines or had worse than 20/40 BSCVA.

In terms of accuracy, 66% of eyes treated for near vision were within 0.5 D of intended correction at the 6-month evaluation. The change in refraction over the 6-month period proved to be minimal. Eighty-five percent of patients experienced a change of 0.05 D or less between months 1 and 3, and 89% of patients experienced a similar change between months 3 and 6. Longer follow-up results will be needed to assert long-term stability [21].

Although conductive keratoplasty was applied in a monovision fashion, it seems to provide more 'blended vision', thus lessening the adverse effects of decreased

binocular distance acuity, contrast sensitivity, and depth perception that accompanies traditional monovision correction. The procedure is technically easy to perform at a low cost to the patient. It avoids the risk of flap complications that can occur with LASIK and does not show any evidence of visually significant corneal haze or scarring. However, the procedure has a limited treatment range, increased risk of inducing irregular astigmatism, and the potential for regression.

Summary for the Clinician

- Conductive keratoplasty utilizes electromagnetic energy to induce corneal collagen shrinkage in the periphery and thereby increase the corneal refractive power.
- In addition to being a safe and easy to perform procedure, visual results appear promising in presbyopic emmetropes and hyperopes.

9.6 Conclusion

Multiple procedures are currently available or under investigation for the corneal management of presbyopia. Corneal approaches can provide minimally invasive methods to achieve spectacle and contact lens independence. Several of these procedures are reversible and, overall, the visual results appear to be encouraging. Near visual acuity can be improved with minimal impact on distance vision (Table 9.1). For some of the non-reversible procedures, such as presbyopic LASIK, further consideration needs to be given to the long-term

management of these patients as they progress from presbyopia to the development of visually significant cataracts.

References

- Schor C, Landsman L, Erickson P (1987) Ocular dominance and the interocular suppression of blur in monovision. *Am J Optom Physiol Opt* 64:723–730
- Jain S, Ou R, Azar DT (2001) Monovision outcomes in presbyopic individuals after refractive surgery. *Ophthalmology* 108:1430–1433
- Back A, Grant T, Hine N (1992) Comparative visual performance of three presbyopic contact lens corrections. *Optom Vis Sci* 69:474–480
- Blake R FR (1973) The psychophysical inquiry into binocular summation. *Perception Psychophys* 14:161–185
- Loshin DS LH, Cornear G. (1982) Binocular summation with monovision contact lens correction for presbyopia. *Int Cont Lens Clin* 9:161–173
- Back AP, Holden BA, Hine NA (1989) Correction of presbyopia with contact lenses: comparative success rates with three systems. *Optom Vis Sci* 66:518–525
- Collins M, Goode A, Brown B (1993) Distance visual acuity and monovision. *Optom Vis Sci* 70:723–728
- CustomVue Monovision LASIK US FDA Clinical Trial
- Goldberg DB (2003) Comparison of myopes and hyperopes after laser in situ keratomileusis monovision. *J Cataract Refract Surg* 29:1695–1701
- Albietz JM, Lenton LM, McLennan SG (2002) Effect of laser in situ keratomileusis for hyperopia on tear film and ocular surface. *J Refract Surg* 18:113–123
- Donnenfeld ED, Solomon K, Perry HD, et al (2003) The effect of hinge position on corneal sensation and dry eye after LASIK. *Ophthalmology* 110:1023–1029; discussion 1029–30
- Fagerholm P, Molander N, Podskochy A, Sundelin S (2004) Epithelial ingrowth after LASIK treatment with scraping and phototherapeutic keratectomy. *Acta Ophthalmol Scand* 82:707–713
- Sugar A, Rapuano CJ, Culbertson WW, et al (2002) Laser in situ keratomileusis for myopia and astigmatism: safety and efficacy: a report by the American Academy of Ophthalmology. *Ophthalmology* 109:175–187
- Toda I, Asano-Kato N, Hori-Komai Y, Tsubota K (2002) Laser-assisted in situ keratomileusis for patients with dry eye. *Arch Ophthalmol* 120:1024–1028
- Wilson SE, Ambrosio R Jr (2002) Sporadic diffuse lamellar keratitis (DLK) after LASIK. *Cornea* 21:560–563
- Wright KW, Guemes A, Kapadia MS, Wilson SE (1999) Binocular function and patient satisfaction after monovision induced by myopic photorefractive keratectomy. *J Cataract Refract Surg* 25:177–182
- VISX Hyperopic Presbyopia Correction US FDA Clinical Trial
- Acufocus ACI 7000 Corneal Inlay Clinical Trial
- PresbyLens Corneal Inlay US FDA Clinical Trial
- McDonald MB, Hersh PS, et al (2002) Conductive keratoplasty for the correction of low to moderate hyperopia: U.S. clinical trial 1-year results on 355 eyes. *Ophthalmology* 109:1978–1989
- McDonald MB, Durrie D, Asbell P, Maloney R, Nichamin L (2004) Treatment of presbyopia with conductive keratoplasty: six-month results of the 1-year United States FDA clinical trial. *Cornea* 23:661–668

Index

- Accommodation of eye
 - apparatus anatomy
 - ciliary muscle, 101, 102
 - zonular fibers and lens capsule, 102
 - Helmholtz mechanism, 102
 - in-vivo experiments, 106
 - intraocular lenses, 107
 - lens shape change
 - anterior curvature, 102
 - flattening and steeping, 103
 - neural control
 - parasympathetic innervation, 103
 - sympathetic innervation, 103, 104
 - optical power change, 101
 - presbyopia
 - definition, 101
 - extralenticular origin, 105, 106
 - lenticular origin, 104, 105
 - multifactorial origin, 106
 - pseudo-accommodation, 104
 - pseudo-accommodative surgery, 107
 - scleral expansion, 107
- Accommodative intraocular lenses, 107
- Acri.Smart lens, 21
- AcriLISA lens, 22
- AcrySof IQ IOL, 83
- Acufocus ACI 7000 inlay, 115
- Afinity IOL, 83
- Alcon SN60TT TIOL, 78
- Alio's MICS knife, 13
- Anterior chamber IOLs (ACIOL)
 - disadvantages, 50
 - dislocation or decentration, 46
- Anterior segment imaging
 - and slit lamp biomicroscopy, 1
 - arc-scanning ultrasound, 3, 4
 - categories of, 1
 - OCT imaging, 4
 - pachymetry measurements, 4–7
 - placido-disc based, 2
 - scheimpflug, 2, 3
 - slit-scanning, 2
- ArcScan. *See* Artemis
- Artemis, 3, 4
- Aspheric IOLs
 - advantages, 91, 92
 - aspheric intraocular lenses, 82, 83
 - corneal spherical aberrations
 - clinical outcomes, 90, 91
 - higher-order aberrations, 82
 - videokeratoscopes, 81
 - custom selection
 - in LASIK, 86
 - in myopic-PRK, 85, 86
 - in normal eyes, 84, 85
 - primary reasons, 84
 - decentration
 - average HOA, 87
 - optical image quality, 87, 88
 - tilt evaluation, 88, 89
 - focus and defocus depth
 - clinical outcomes, 92
 - polychromatic modulation transfer, 89, 90
 - Aspheric laser profiles, 97
 - Aspheric Restor, 83
- Astigmatism
 - cataract population and incidence
 - corneal astigmatism, 69, 70
 - refractive power, 69
 - regular corneal, 67
 - surgical corrections, 70
 - TIOL technology
 - advantages and disadvantages, 70, 71
 - clinical trial, 78
 - refraction control, 76
 - topographic measurements, 76
 - toricity of optics, 67
- BESSt formula, 2
- Biaxial microincision clear corneal phacoemulsification, 11
- Biometry, 8
- Capsular bending ring (CBR)
 - 'tailed' ring, 38
 - after-cataract preventive effect, 36, 37
 - capsular bend induction, 36
 - fibrotic shrinkage prevention, 37
 - foldable closed ring
 - diameter and shrinkage, 38–40
 - segments, 38
 - ring insertion, 40
 - ring insertion, 40
- Capsular distance ring. *See* Capsular bending ring (CBR)

- Capsular tension rings (CTR)
 - after-cataract formation
 - clinical effects, 36
 - mechanisms involved, 35
 - and capsular tension segment, 33, 34
 - capsular bag
 - diameter quantification, 34
 - shrinkage, 34, 35
 - capsular bag ovalization, 28, 29
 - capsular contraction, 41
 - capsulorhexis, 41
 - cataract and vitreous surgery, 30, 31
 - for sulcus suture fixation, 32, 33
 - generalized zonular weakness, 29, 30
 - insertion technique
 - capsular entanglement, 40
 - zonular traction, 41
- intravitreal misplacement, 41
- iris defects
 - aniridia, 31, 32
 - kolobomas, 31
 - localized zonular dehiscence, 29
 - modifications in, 28, 29
 - poly (methylmethacrylate) source, 27
 - posterior capsulorhexis, 30
 - subluxation in capsule complex, 42
- Capsular tension segment (CTS), 33, 34
- CBR. *See* Capsular bending ring
- Coma induction, 95
- Conductive keratoplasty (CK)
 - clinical trial, 116, 117
 - electromagnetic energy, 115, 116
 - emmetropes and hyperopes, 115
- Contrast sensitivity (CS), 90–92, 96, 97, 107, 112, 117
- Corneal refractive power, 69
- Corneal spherical aberrations
 - higher-order aberrations, 82
 - videokeratoscopes, 81
- Corneal wavefront aberrations, 85
- Cruise Control™ system, 19
- CTR. *See* Capsule tension rings
- CTS. *See* Capsular tension segment

- Disaccommodation of eye, 102

- Effective phaco time (EPT), 12
- EPT. *See* Effective phaco time
- Eye trackers, 97

- Femtosecond laser, 97

- Helmholtz mechanism, 102
- Higher-order aberrations (HOAs)
 - and spherical aberration, 84
 - aspheric IOLs, custom selection, 85–87
 - focus depth, 88
- Hydrodelineation, 14
- Hydrodissection, 14

- Intracorneal hydrogel lenses, 115
- Intraocular lens (IOL)
 - capsular fixation
 - anterior optic capture, 51
 - bag fixation, 51
 - ciliary sulcus, 53, 54
 - posterior optic capture, 52, 53
 - causes, 48–49
 - complications, 63
 - disadvantages, 50
 - dislocation or decentration
 - anterior and posterior chambers, 46–48
 - incident rate, 45
 - retroillumination, 48
 - zonular integrity, 48
 - iris sutured repositioning
 - out-of-the-bag lenses, 58
 - residual Sommering's ring, 58
 - vitreous adhesions, 58, 60
 - polymethylmethacrylate source, 45
 - pre-existing subluxation
 - iris claw IOL, 63
 - opacification, 60
 - vitreous management, 62
 - pseudoexfoliation syndrome, 47, 48
 - scleral suture repositioning
 - conjunctival dissection, 55, 56
 - corneal paracentesis, 56
 - haptic region, 54
 - IOL-CTR complex, 54, 55
 - polypropylene needle, 56, 57
 - surgical management, 64
- IOL. *See* Intraocular lens
- IRIS
 - and capsule tension rings
 - aniridia, 31, 32
 - kolobomas, 31
- Iris sutured repositioning and IOL
 - out-of-the-bag lenses, 58
 - residual Sommering's ring, 58
 - vitreous adhesions, 58, 60

- Lamellar corneal surgery, 8
- Laser in situ keratomileusis (LASIK) astigmatism, 67
- Laser-assisted in situ keratomileusis (LASIK)
 - aspheric IOL, 86
 - presbyopia monovision approach, 112
- LASIK. *See* Laser-assisted in situ keratomileusis
- LCVA. *See* Low-contrast visual acuity
- Limbal relaxing incisions (LRI), 70
- Low-contrast visual acuity (LCVA), 96

- McCannel suture technique, 60, 61
- Microincision cataract surgery (MICS)

- astigmatism, 70
- astigmatism control, 21
- corneal aberration control, 21–23
- definition and advantages, 12
- endophthalmitis prevention, 23, 24
- flat instruments usage, 17
- future development, 24
- incision integrity, 20, 21
- incision minimization, 11
- irrigating–aspirating system, 19
- liquid flow
 - corneal burns, 18, 19
 - infusion canulas, 17, 18
- operation indication, 12, 13
- surgical technique
 - anesthesia, 13
 - capsulorhexis, 13, 14
 - cataract removal, 15–17
 - hydrodissection and hydrodelineation, 14
 - incision optimization, 13
 - phacoemulsification, 15
 - prechopping, 14, 15
 - ultrasonic power reduction, 20
- MicroSil Z-haptics, 79
- Microtying forceps (MST), 60
- MICS diamond knife, 13
- MST. *See* Microtying forceps
- Myopic PRK, aspheric IOL, 85, 86

- OCT. *See* Optical coherence tomography
- Ocular visco-surgical device (OVD), 29
- Oculus. *See* Pentacam
- Optical coherence tomography (OCT), 4
- Optical Quality Analysis System, 22
- Optimal IOL spherical aberrations, 85, 86
- Orbscan technology
 - elevation maps, 2
 - in refractive surgery, 7
- OVD. *See* Ocular visco-surgical device

- Pachymetry, 4–7
- Pea podding, 49
- Pentacam
 - and slit images, 2, 3
 - in refractive surgery, 7, 8
- Phacoemulsification, 15
- Phakic intraocular lenses (PIOL), 8
- Photorefractive keratectomy (PRK)
 - presbyopia monovision approach, 112, 113
- Phototherapeutic keratectomy (PTK)
 - postoperative curvature maps, 2, 3
- PIOL. *See* Phakic intraocular lenses
- Placido-disc based imaging, 2
- PMTF. *See* Polychromatic modulation transfer function
- Polychromatic modulation transfer function (PMTF), 88

- Posterior chamber IOLs (PCIOL), 46
- PPC. *See* Primary posterior capsulorhexis
- Prechopping, 14, 15
- PresbyLASIK
 - concentric rings, 113
 - visual outcomes, 114, 115
- Presbyopia
 - Acufocus ACI 7000 inlay, 115
 - conductive keratoplasty
 - clinical trial, 116, 117
 - electromagnetic energy, 115, 116
 - definition, 101
 - extralenticular origin
 - ciliary muscle dysfunction, 105, 106
 - elasticity of membrane, 106
 - vitreous body, 106
 - intracorneal hydrogel lenses, 115
 - lens elasticity restoration, 107
 - lenticular origin
 - aging of capsule, 105
 - growth of lens, 105
 - hardening of lens, 104 105
 - monovision approach
 - binocular visual acuity, 112
 - interocular blur, 111
 - LASIK, 112
 - patient selection, 112
 - photorefractive keratectomy (PRK), 112, 113
 - multifactorial origin, 106
 - multifocal LASIK
 - concentric rings, 113
 - visual outcomes, 114, 115
- Primary posterior capsulorhexis (PPC), 30
- Pseudo-accommodation of eye, 104
- PTK. *See* Phototherapeutic keratectomy
- Pupil diameter (PD), 95

- Scheimpflug imaging, 2, 3
- Scleral suture repositioning and IOL
 - conjunctival dissection, 55, 56
 - corneal paracentesis, 56
 - haptic region, 54
 - IOL-CTR complex, 54, 55
 - polypropylene needle, 56, 57
- Slit lamp biomicroscopy, 1
- Slit-scanning imaging, 2
- SofPort AO/Akreos AO IOL, 83
- Spherical aberrations (SA)
 - clinical outcomes, 90, 91
 - higher-order aberrations, 82, 84
 - videokeratoscopes, 81
- SQV. *See* Subjective quality of vision
- STAAR Toric IOL, 78
- Stable chamber tubing system, 19, 20
- Stiles–Crawford effect, 88, 89
- Subjective quality of vision (SQV), 96
- Sulcus suture fixation and CTR, 32, 33

- Sunrise syndrome, 48
- Sunset syndrome, 48
- Surgically induced astigmatism (SIA), 21

- Tecnis IOL, 83
- ThinOptX lens, 21
- Toric intraocular lenses (TIOL)
 - advantages and disadvantages, 70, 71
 - clinical trials, 78
 - digital overlay technique
 - axis markers, 73, 75
 - cyclorotation, 72–74
 - implantation, 76,
 - IOL power calculation, 72
 - keratometric measurements, 71, 72
 - primary cataract surgery, 70
 - refraction control and topography, 76
- Uncorrected distance visual acuity (UCDVA), 115, 116

- Videokeratography
 - in refractive surgery, 7
 - placido-disc based imaging, 2
- VOL-CT program, 85

- Wavefront-guided laser profiles, 97

- Zernike modes, 96
- Zernike terms, 82, 84, 89
- ZernikeTool program, 88, 89